

Case Series of Warts and Its Individualised Homoeopathic Treatment

Dr. Mousumi Das¹, Dr. Ananya Paramanya²

¹Assistant Professor, Department of Practice of Medicine, Noble Homoeopathic College and Research Institute, Junagadh, Gujarat, India

²Assistant Professor, Department of Surgery, Noble Homoeopathic College and Research Institute, Junagadh, Gujarat, India

Corresponding Author: Dr. Mousumi Das

DOI: <https://doi.org/10.52403/ijhsr.20231120>

ABSTRACT

The mirror of your health is your skin. When health gets compromised there are growth on your skin. Warts are the commonest viral infections which are benign skin growths that grow in various forms on different parts of the body. Warts are caused by the human papillomavirus (HPV), of which there are over 100 types. Inadequate rest, poor diet, increased stress, weak immune systems and close living quarters can also contribute to risk of acquiring the wart virus which means warts too have an individualistic and immunological basis. Warts can affect people at any age but most common in children and teenagers. Warts can be ugly, uncomfortable, potentially contagious and some people feel abashed. Warts may be single, multiple, cauliflower like or smooth and are usually managed by applying external ointment or surgical excision procedure. Warts comes under sycotic miasm. Although it is a local disease, but an individualized homoeopathic treatment can eradicate the warts locally and internally. Hence, the search for a safe, cost-effective treatment where good health comes naturally ends here. The cases discussed below comprises of filiform warts, oral mucosal wart and common warts which were treated with Thuja occidentalis, Causticum and Thuja occidentalis respectively. These case series show how effectively homoeopathic remedies works and provide positive results in warts.

KEYWORDS: Warts, Human Papilloma Virus, Individualisation, Homoeopathy.

INTRODUCTION

Viral warts are benign skin protuberances caused by human papilloma virus.¹ Warts can affect skin as well as mucous membrane. The HPV virus has over 100 of subtypes based on the type of virus, mode of entry, and immune status of host², but only few types can cause warts at selective anatomical sites: Some of which are mentioned below³. Myrmecia warts caused by HPV subtype 1 which is generally found on pressure point of foot, sometimes painful in nature⁴. Common warts are caused by HPV subtype 2, 4, 57 which is generally found in dorsum of hand and

feet, around the finger nail, toe. If found in oral cavity it is termed as oral mucosal warts^{4,5}. Filiform warts are caused by HPV subtype 1,2,4,27,29 which have a thread-like, spiky appearance; as they often appear on the face, they are usually considered to be incommensurate^{4,5}. Plantar warts are generally found on the ankles, toe and soles of the feet. Because of the pressure on the soles of your feet due to body weight, plantar warts do not grow outward like other kinds of warts and are pushed inward when you stand or walk and hence painful⁵. Mosaic warts are whitish, usually found on the padded portion of the sole or under the

toes which may spread and cover the entire sole. These warts are flatter than plantar warts, and they rarely hurt while walking⁵. Flat warts are light brown coloured; small, slightly raised warts that are often just a few millimeters wide which are commonly found on the face, particularly on the forehead and cheeks⁵. Genital warts are sexually transmitted and affect only the genital area which are small hard nodules with rough surfaces⁵.

According to Ayurveda, this ailment can be compared with Charmakeela in which the pathogenesis of this disease is due to vitiation of Vata along with Kapha over the skin which causes the development of hard nail like structures called Charmakeela. Sushruta has mentioned four types of treatments in Ayurveda, i.e., bheshaja (medicines), ksharakarma (Application of alkali preparation), Agni karma (Cauterization) and Shastrakarma (Surgery) as chikitsopakarma for Asrha (piles) in Sushruta samhitha sutra sthana and he has given more emphasis on ksharakarma which also holds good for treatment of Charmakeela. It is described that the attainment of total management is by using the internal drugs, external applications and *Kshrakarma* (Ligation around the base of the wart) and *Agnikarma* (Thermal cauterization)⁶.

In this modern civilization various types of treatment and procedures are available in modern medicine such as applying *liquid nitrogen*, *salicylic acid* and *podophyllin*, CO₂ laser surgery, interferon injections and loop electrosurgical excision procedure⁷.

Homoeopathic concept

According to homeopathic principle we treat patient as a whole i.e., mental as well as physical generals are taken and symptoms are evaluated according to the severity. The evaluated symptoms are conjoint together in one as totality of symptoms. After the totality, a similia similibus remedy i.e. the selected medicine corresponds to the peculiar, uncommon,

singular and distinguishing (characteristic) symptoms of the disease is selected⁸.

Warts are classified under one-sided disease, i.e., diseases which have very few symptoms. They are further categorized as external-local maladies, i.e., changes and ailments that appear on the external parts of the body⁹.

There are lots of drugs mentioned in homoeopathic materia medica, some of them are mentioned below

- **Thuja occidentalis:** Warts like excrescences, which are soft, pulpy & very sensitive, burn, itch & bleed easily. Horny excrescences that form on the hands & split open, and crack around the base¹⁰. Warts large, seedy, pedunculated¹¹. Thuja is a remedy, which tends to alter the sycotic constitution, to change the soil on which this poison grows. Warts or condylomata appear on genitals, anus about the perineum, and upon mucous surface. These warts may have a seedy look, or may be of a cauliflower shape. Cauliflower like excrescences especially apt to grow from the cervix uteri. In other cases, these warts are moist and ooze a glutinous, foul-smelling fluid¹².
- **Nitric acid:** Nitric acid is indicated in large, jagged, pedunculated, bleeding readily on washing, moist, oozing, sticking pain¹³. Warts form in and around the nostrils. Nitric acid resembles thuja in the condylomata or warts. Nitric acid has, however to distinguish it from Thuja more aching pain in the bones, especially in those localities devoid of muscular tissue covering, as along the tibia, and over the sternum and cranium. Nitric acid is the highly corrosive acid, eating into the flesh. Hence it has been used for the removal of warts, tumors, ulcers and exuberant granulations. Warts develop, and these are almost always more or less pediculated¹⁴.

- **Causticum:** Large, jagged, often pedunculated, bleeding easily on tips of finger & nose exuding moisture, small, all over the body, on eyelids, face, on the nose¹⁵. Causticum also acts on skin, one of its most characteristic symptoms being warts. It is useful in the cure of these hypertrophy of the papillae when they occur on the hand and face¹⁶. Deep burns and their effects. Patient is sympathetic and anxious¹⁷.
- **Natrum muriaticum:** Warts on palms of hand¹⁸. greasy skin, oily especially on hairy parts¹⁹.
- **Dulcumara:** Warts, fleshy, large, smooth on face or back of hands & finger²⁰.
- **Calcarea carbonica:** warts on face & hands²¹.

Case no- 1: A Case of Filiform Warts

A 34-year-old male reported to NIH OPD on 3rd January 2019 with multiple small warts below the chin at the muscular triangle area of neck. Six months ago, one small wart appeared gradually the warts increased in number and had spread the in front of muscular triangle area of neck. The patient had already taken various mode of treatment such as burn by applying acid but it reappeared.

On local examination

- Location of warts – At the muscular triangle area of neck.
- Pattern of distribution – spread out unevenly.
- Shape of warts – irregular

- Surface of warts – uneven, cauliflower like
- Pain - Painless
- Discharge – Absent
- Itching – Absent
- Other systemic examinations were normal.

The diagnosis of viral warts was based on pattern of distribution following the guidelines of ICD-10, code B-07.9²².

The characteristic mental and physical generals are as follows: -

- Cauliflower like growth on the at the muscular triangle area of neck.
- Intolerance of milk which causes gastric intolerance.
- Stool hard, irregular & passes 3 to 4 days interval.
- Mother had several warts on neck.
- Sour eructation.
- Craves for onions.
- Sleeplessness.
- Anxious dreams.
- Tendency to catch cold easily.
- Gets tired easily.
- Multiple joint pain.
- Lean, thin constitution.

On reportorial analysis using Zomeo, repertorial software²³ Thuja Occidentalis scored 42 marks covering most of the rubrics i.e., 12. According to miasmatic consideration, the person is psoro sycotic but sycotic miasm is dominant. Thuja is a great anti- sycotic remedy. Therefore, patient was prescribed Thuja Occidentalis 30C/ 2doses, for consecutive 2 days on 3rd January 2019. The patient was asked to report after one month for follow up.

TABLE 1: REPERTORIAL SHEET CASE NO.1

Follow ups:

Sr. no.	Date	Medicine	Follow ups
1.	10/02/2019	Placebo	The size of the warts decreased. Stools were soft and regular.
2.	22/03/2019	Thuja Occidentalis 200/ 2 doses O.D X 2 days	No significant change from the last visit. Multiple Joint pains remain same.
3.	25/04/2019	Placebo	Some of the warts which were comparatively smaller disappeared and few remains. Multiple joint pains reduced. Sour eructation much reduced.
4.	29/05/2019	Thuja Occidentalis 200/ 2 doses O.D X 2 days	The remaining warts became much smaller than before. Multiple joint pains much reduced than before.
5.	05/07/2019	Placebo	No complaints of joint pain and no sour eructation. The warts disappeared.

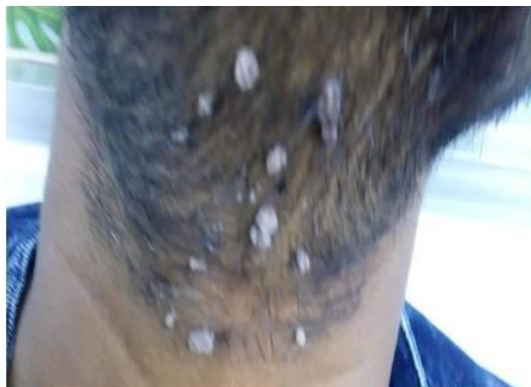

FIGURE 1A. Showing multiple warts below the chin at the muscular triangle area of neck before treatment.

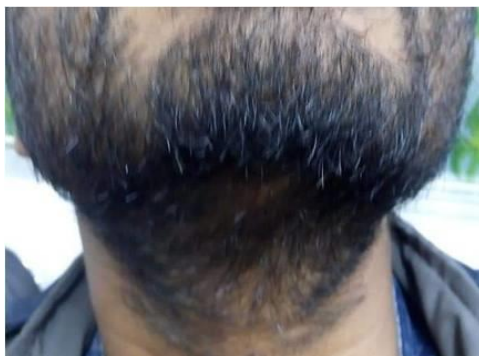

FIGURE 1B. Multiple warts gets clear after 7 months treatment.

Case no- 2: A Case of Oral Mucosal Warts

A 10-year-old girl came to NIH OPD on 22nd March 2019 with a single pea sized wart hanging below the tongue. Eight months ago, patient sensed a small pin sized growth below her tongue and ignored it as it was painless. Eventually as the time passed, the growth increased in size and is of a pea and has become painful. The texture is smooth with oval shaped hanging below the tongue. As the patient had complained of headache during studying, she was asked to visit the OPD with 15 days interval.

On local examination

- Location of warts-Below the tongue.
- Pattern of distribution – Single wart hanging below the tongue
- Shape of warts – Pedunculated
- Surface of warts –Smooth.
- Pain - Painful
- Discharge – Absent

- Itching – Absent
- Other systemic examinations were normal.

The characteristic mental and physical generals are as follows: -

- Frontal headache which was increasing during studying.
- Sympathetic in nature.
- Desire for egg, meat.
- Aversion for sweet.
- Great thirst for large quantity of water at frequent interval.
- Stool hard, irregular, passes 1 to 2 days interval

- Aggravation on consuming hot foods and drinks.
- Hasty hurried.
- Very hot patient.

After a thorough case taking and reportorial analysis, “Causticum” has scored highest marks (31) covering 11 rubrics. The mental, physical and particular general symptomologies were well covered by this remedy. Hence, the most appropriate remedy for this case was “Causticum”. Patient was prescribed Causticum 200C/4doses, for consecutive 4 days on 22nd March 2019. The patient was asked to report after one month for follow up.

The screenshot shows a software interface for homeopathic repertorial analysis. The main window displays a table of results for the rubric 'Causticum'. The table has columns for various remedies: Caust, Nit-ac, Lyc, Thuja, Med, Sulph, Ars, Calc, Phos, Arg-n, Bell, and Staph. The 'Caust' column shows a score of 31, which is the highest among all remedies listed. The table also includes a list of symptoms covered by the remedy, such as '[Complete] [Skin]Warts, condylomata: (191)' and '[Complete] [Generalities]Heated, warmed, hot, becoming Agg.: (226)'. The interface includes various toolbars and a sidebar with navigation options.

TABLE 2: REPERTOTRIAL SHEET CASE NO. 2

Follow ups:

Sr. no.	Date	Medicine	Follow ups
1.	26/04/2019	Placebo	The size of the wart slightly decreased
2.	01/06/2019	Causticum 200/4 doses. O. D×4 days To be taken every morning, empty stomach.	No significant change from the last visit
3.	13/07/2019	Placebo	The growth reduced half in size and the frontal headache is significantly less than before.
4.	25/08/2019	Placebo	The growth almost disappeared
5.	29/09/2019	Placebo	The growth disappeared completely with no complaints of frontal headache.

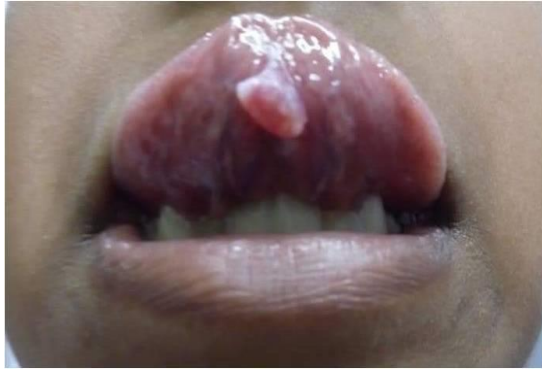

FIGURE: 2A. Showing single pea sized wart hanging below the tongue before treatment

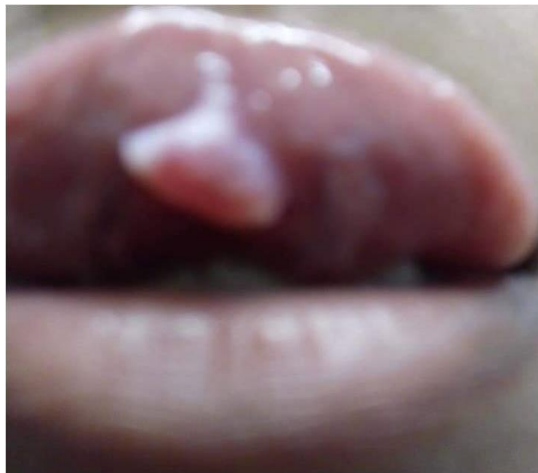


FIGURE: 2B. During treatment (phase 1) Showing no change after first visit

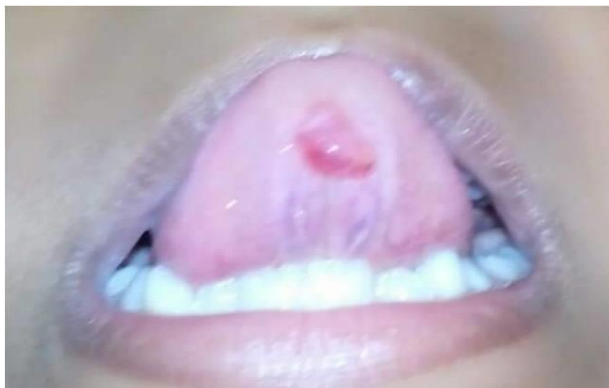

FIGURE: 2C. During treatment (phase 2) size of the wart is getting reduced

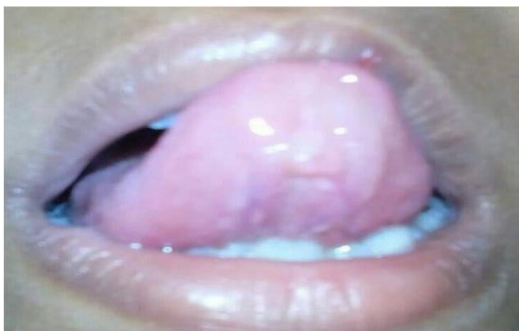

FIGURE: 2D. Oral mucosal warts get clear after 6 months treatment

Case no-3: A Case of Common Warts

A 12-year-old boy reported to NIH OPD on 12th March 2019 with cauliflower like growth on the medial aspect of left axilla for 6 months. Initially there was a pin point sized lesion and then several small, cauliflower like warts appeared on the medial aspect of left arm and eventually it started growing in size and formed cluster. Before visiting our OPD the patient had already gone through several allopathic treatments with no satisfactory result.

On local examination

- Location of warts – On the medial aspect of left axilla.
- Pattern of distribution – Clustered cauliflower like growth
- Shape of warts – irregular
- Surface of warts – uneven, cauliflower like
- Pain - Painless
- Discharge – Absent
- Itching – Absent
- Other systemic examinations were normal.

The characteristic mental and physical generals are as follows: -

- Mentally very active.
- Fear of darkness.
- Dreams of falling.
- Preferred salty food, cold drinks.
- Aversion to bathing.
- Religious.
- Hot patient.
- Sweat profuse on head and face and offensive.
- Brittle nails.

On reportorial analysis scored highest marks 30 covering most of the rubrics 9. According to miasmatic diagnosis patient is psoro-sycotic but sycotic symptoms are more prominent. Thuja Occidentalis is a great anti- sycotic remedy. Therefore, the treatment started with anti- sycotic medicine. Patient was prescribed Thuja Occidentalis 200C/ 4doses, for consecutive

4 days on 12th March 2019. The patient was up asked to report after one month for follow

TABLE 3: REPERTOTRIAL SHEET CASE NO.3

Follow ups:

Sr. no.	Date	Medicine	Follow ups
1.	18/04/2019	Placebo	Cluster reduced in size.
2.	17/05/2019	ThujaOccidentalis200/2 doses O. D×2 days To be taken every morning, empty stomach	Growth was same as the last visit. No significant changes.
3.	24/06/2019	Placebo	Cluster reduced half of its original size of the first visit. Sweat less than before.
4.	02/08/2019	Thuja Occidentalis 1M/1doses. O. D× 1 days To be taken at morning, empty stomach.	No significant changes from the last visit.
5.	06/09/2019	Placebo	Growth disappeared with significant hyperpigmentation of the specific area. Offensive ness of perspiration less than before.

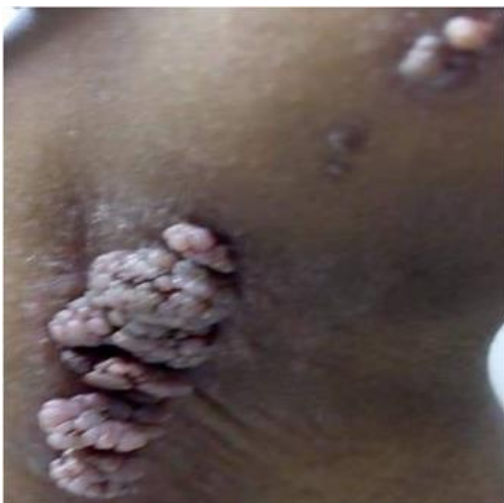

FIGURE: 3A. Showing multiple cauliflower like growth on the medial aspect of left axilla before treatment

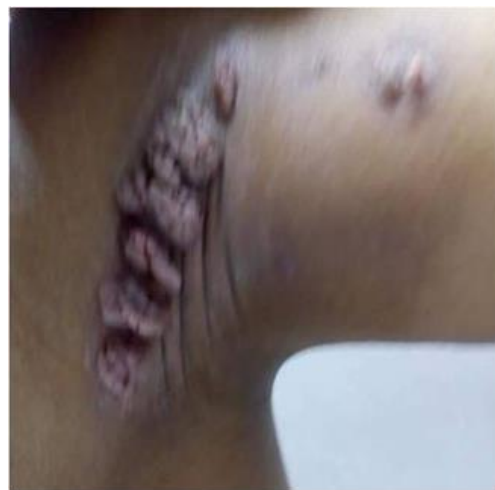

FIGURE: 3B. Showing size of cauliflower like growth reduced during treatment

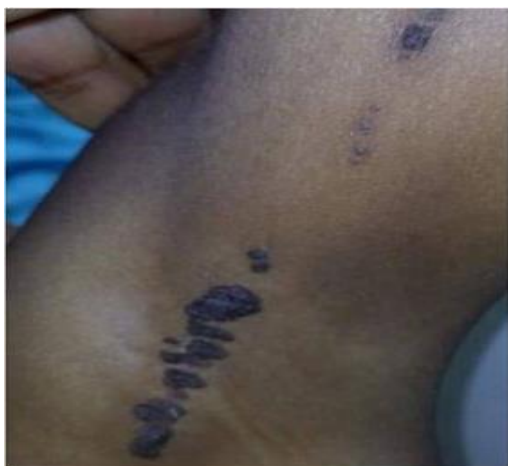

FIGURE: 3C. Cauliflower like growth leaving a hyper pigmented mark after 6 months treatment

CONCLUSION

These case series suggest usefulness of homeopathic treatment as a complementary and alternative therapy. These case series show a positive result in homeopathy where in conventional methods it needs to apply various external ointment and many other things. However, this is a case series and requires randomized control study (RCT) which may take up for future scientific validation.

Declaration by Authors

Acknowledgement: None

Source of Funding: None

Conflict of Interest: The authors declare no conflict of interest.

REFERENCES

1. Mahajan N, Mahajan A, Bhinda A, Salodiya S. Homeopathic treatment of viral warts with *Calcarea phosphorica*. *Indian J Res Homoeopathy* 2020; 14:279-86.
2. **Khanna N.** Illustrated Synopsis of Dermatology and Sexually Transmitted Diseases .4th ed. Amsterdam, Netherlands: Elsevier; 2011.91-5
3. Ahmad M. Al Aboud; Pramod K. Nigam. Wart. National Library of Medicine. Available at: <https://www.ncbi.nlm.nih.gov/books/NBK431047/>. August 8, 2022. Accessed November 20, 2022.
4. Lawrence Leung. Treating common warts – options and evidence. Reprinted from *Australian Family Physician* December 2010; 39:12.
5. NCBI Bookshelf. A service of the National Library of Medicine, National Institutes of Health. Warts: Overview. *InformedHealth.org* [Internet]. Cologne, Germany: Institute for Quality and Efficiency in Health Care (IQWiG); 2006-. Available at: <https://www.ncbi.nlm.nih.gov/books/NBK279586/?report=printable>. November 7, 2019. Accessed November 20, 2022
6. Vijayshankar B.V, Muralidhara Sharma, Chandrashekar R*, Manohar V.R. A prospective study of prathisaraneeya apamarga kshara in comparison with prathisaraneeya palasha kshara in patients with charmakeela (warts) and kadara (corns). *The Journal of Phytopharmacology* 2014; 3(5): 330-336
7. Shaikh MI. Case studies for treatment of warts with Homeopathy. *Indian J Res Homoeopathy* 2016;10: 272-8.
8. Hahnemann S. *Organon of Medicine*. 5th Ed. New Delhi: B. Jain Publishers; 1983.126. §153.
9. Hahnemann S. *Organon of Medicine*. 5th Ed. New Delhi: B. Jain Publishers; 1983.134. §185.
10. Kent.J.T. *Lectures on homeopathic material medica*. Indian edition. New Delhi: Indian Books and periodicals publishers; 2015.994.
11. Allen. H.C. *Keynotes and Characteristics with Comparisons of some of the leading remedies of the material medica with bowel nosodes*. 8th Ed. New Delhi: B. Jain Publishers; 2014.294.
12. Farrington. E. A. *A clinical material medica*. 8th Ed. New Delhi: Indian Books and periodicals publishers; July 2013.309.
13. Allen. H.C. *Keynotes and Characteristics with Comparisons of some of the leading remedies of the material medica with bowel nosodes*. 8th Ed. New Delhi: B. Jain Publishers; 2014.206.
14. Farrington. E. A. *A clinical material medica*. 8th Ed. New Delhi: Indian Books and periodicals publishers; July 2013.310, 533,535.
15. Allen. H.C. *Keynotes and Characteristics with Comparisons of some of the leading remedies of the material medica with bowel nosodes*. 8th Ed. New Delhi: B. Jain Publishers; 2014.90.

16. Farrington. E. A. A clinical material medica. 8th Ed. New Delhi: Indian Books and periodicals publishers; July 2013.735.
 17. Oza PM. Homeopathic management of warts. Indian J Drugs Dermatol 2016; 2:45-7.
 18. Allen. H.C. Keynotes and Characteristics with Comparisons of some of the leading remedies of the material medica with bowel nosodes. 8th Ed. New Delhi: B. Jain Publishers; 2014.201.
 19. Boericke. W. Pocket manual of homoeopathic material medica and repertory. 10thEd. New Delhi: B. Jain Publishers; 2012. 461.
 20. Allen. H.C. Keynotes and Characteristics with Comparisons of some of the leading remedies of the material medica with bowel nosodes. 8th Ed. New Delhi: B. Jain Publishers; 2014.121.
 21. Boericke. W. Pocket manual of homoeopathic material medica and repertory. 10thEd. New Delhi: B. Jain Publishers;2012.147
 22. Diagnosis code for viral warts. Available at: <https://www.icd10data.com/ICD10CM/Codes/A00-B99/B00-B09/B07-/B07.9> Accessed October 15, 2022
 23. Zomeo, Copyright © 2012 Mind Technologies.
- How to cite this article: Mousumi Das, Ananya Paramanya. Case series of warts and its individualised homoeopathic treatment. *Int J Health Sci Res.* 2023; 13(11):162-170. DOI: <https://doi.org/10.52403/ijhsr.20231120>
