

Renal Vascular Amyloidosis - A Brainstormer Manifestation of Autoimmune Diseases Spectrum

Khan Fatima¹, Singhai Atin¹, Gupta Vaibhav¹, Babu Suresh¹, Dhakad Urmila²

¹Department of Pathology, King George's Medical University, Lucknow, UP, India

²Department of Rheumatology, King George's Medical University, Lucknow, UP, India

Corresponding Author: Atin Singhai

DOI: <https://doi.org/10.52403/ijhsr.20231012>

ABSTRACT

Chronic autoimmune diseases serve as a severe threat in long-term leading to renal manifestations. Renal vascular amyloidosis in itself is fatal with amyloid deposition occurs predominantly in renal arteries and arterioles. Renal vascular amyloidosis being an uncommon condition presents as diagnostic and therapeutic challenge for pathologists as well as clinicians. It presents with renal insufficiency without significant proteinuria, whereas glomerular amyloidosis presents with nephrotic range proteinuria. We present a case of renal vascular amyloidosis as a rare complication of long-term Psoriatic arthritis and Inflammatory bowel disease as well as presentation of amyloid deposition around arterioles of glomeruli instead of conventional nodular arrangement. This case highlights the importance of regular follow up and screening of patients with chronic autoimmune diseases on treatment to decrease renal morbidities and thereby reducing renal transplantation.

Keywords: Amyloidosis, Autoimmune, Vessels

INTRODUCTION

Amyloidosis constitutes a heterogeneous group of diseases characterized by abnormal folding of protein that undergoes mutation and renders it prone to self-aggregation to form protofilaments which interact with extracellular environment to facilitate aggregation and fibril buildup. The most common form of systemic amyloidosis is Light chain (AL) amyloidosis. [1] The incidence of renal amyloidosis is more in Western population as compared to developing countries like India with primary amyloidosis being the most common cause of systemic amyloidosis in West [2] contrary to secondary amyloidosis remains the most common source in India. [3]

Renal vascular amyloidosis being an uncommon condition presents as diagnostic and therapeutic challenge for pathologists as well as clinicians. It presents with renal insufficiency without significant proteinuria,

whereas glomerular amyloidosis presents with nephrotic range proteinuria and hence diagnosed early. Amyloid deposition occurs predominantly in renal arteries and arterioles along with insignificant glomerular deposits. The prevalence of vascular limited disease ranges from 12.5 to 28.9% in AA amyloidosis, [4] and the renal prognosis is better in vascular involvement. It is characterized by elevated serum creatinine, decreased eGFR with minimal or no proteinuria.

Studies reveal that vascular amyloidosis is associated with various diseases (Crohn's disease, Behcet's disease, Rheumatoid arthritis) and long-term hemodialysis. The entity is diagnosed on renal biopsy section stained with Congo Red and visualized under polarized microscope. Further Electron microscopy studies depict the tunicae involved by the amyloid. [5]

Integration of clinical and pathological findings helps in prompt diagnosis of renal vascular amyloidosis associated with autoimmune systemic manifestations and its management is based on multidisciplinary approach involving the management of underlying cause which results in retarding the progression of disease and thus salvaging the renal function. Hereby, we present a case of renal vascular amyloidosis as a complication of long-standing autoimmune conditions (Psoriatic arthritis and Inflammatory bowel disease).

CASE REPORT

A 51 years old male presented with pedal oedema and nephrotic range proteinuria with prevalent history of chronic Psoriatic arthritis and Inflammatory bowel disease for 12 years. He had severe Psoriatic arthritis with exacerbation of joints pain every 7-8 months for 12 years and had been on treatment with methotrexate during acute events.

Laboratory tests showed; Hb 10.5 g/dl, serum iron 30 microgram/dl, transferrin level 200 mg/dl. The 24-hour urinary protein excretion was 7.5 g, serum albumin

13 g/l, the creatine clearance was 1.3 ml/s and ultrasound examination of the kidneys were normal. The ESR was 130 mm/h and CRP was 105 mg/dl. Tests for viral markers like Hepatitis A, B, C were normal. Serological tests for antinuclear antibody, dsDNA and rheumatoid factor were also negative.

Renal biopsy was performed which revealed all glomeruli showing uniform affection in the form of moderate mesangial expansion with eosinophilic acellular deposition seen around few afferent arteriole entering glomeruli as well as capillaries of almost all glomeruli. Congo red positive acellular deposits depicted apple green birefringence around arteriole and capillaries on polaroid light. There were few minor blood vessels which also showed significant Congo red positive proteinaceous depositions in their wall. Immunological association with lambda light chain positivity was also seen on Immunofluorescence.

Following the diagnosis of renal vascular amyloidosis, he was treated with Colchicine and Infliximab and patient showed significant improvement with regression of pedal oedema and proteinuria.

RESULT

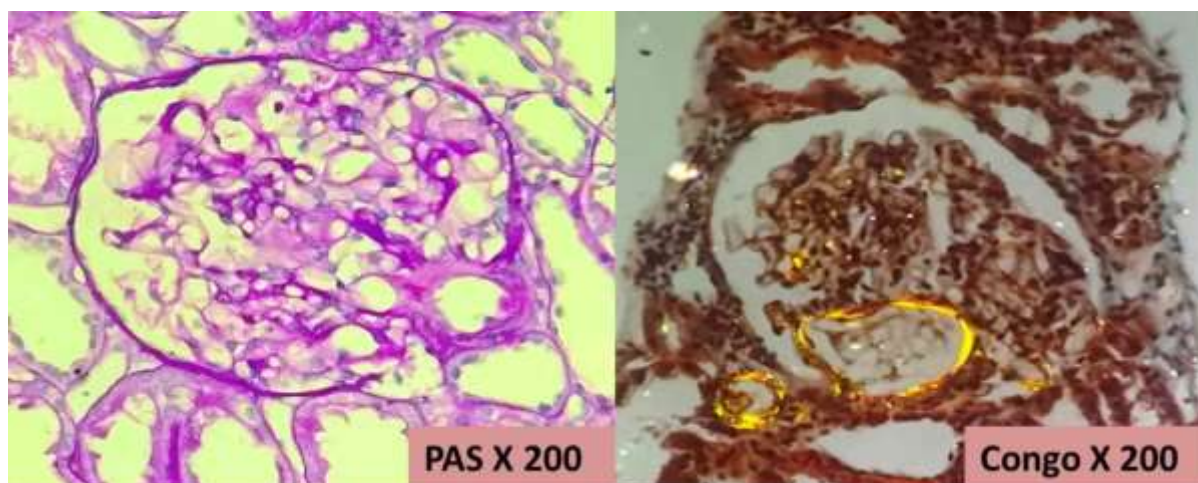


Figure 1- (20X) PAS positive acellular deposition seen around afferent arteriole and glomerular capillaries. (20X) CongoRed show apple green birefringence around afferent arteriole, few glomerular capillaries as well as in the vessel outside glomerulus.

DISCUSSION

Amyloidosis itself is a rare condition and presenting as a complication in association with various autoimmune conditions is extremely rare. The earliest report considering renal amyloidosis associated with systemic manifestation of Psoriasis was published in 1965 by Moise et al [6] and with Inflammatory bowel disease published in 1936 by Moschkowitz. [7] Amyloid is characterized by extracellular infiltration by fibrillary material that shows positive staining with Congo Red and Apple green birefringence under polarized light. Usually, amyloid deposition is seen as nodular deposition in mesangium of glomerulus but in our case presented with amyloid deposition around afferent arterioles of almost all glomeruli and around renal vessels. Amyloidosis can be hereditary or acquired with acquired being the most common. Kidney being the most common organ to be involved by systemic amyloidosis so the patients are always at risk of requiring renal replacement therapy. Psoriasis is an immunomediated disease mostly affecting the skin and at times the joints. Renal involvement in psoriasis has aroused keen interest. Psoriatic arthritis is a rare cause of renal amyloidosis with only few cases reported so far in the literature. [8] Renal disturbances in Psoriatic arthritis is mostly drug induced i.e., methotrexate, cyclosporine etc. [9] Long term cases of psoriatic arthritis are worrisome as in long period renal involvement starts and once renal involvement in the form of amyloidosis has been reached then renal hemodialysis and renal transplantation is last and final step.

Renal vascular amyloidosis is a well-known but rare extra-intestinal complication of Inflammatory bowel disease. Mostly Crohn's disease affects renal parenchyma but few literatures of renal amyloidosis with Ulcerative colitis have also been reported. [10]

Here in our case, patient had long term history of on and off joints pain in association with psoriatic arthritis and was

on methotrexate which alone caused renal manifestations on long term consumption. And on top of that patient also had Inflammatory bowel disease which also served as a triggering factor in etiology of renal vascular amyloidosis.

Amyloidosis associated with light chain (AL) is generally associated with Multiple myeloma and systemic amyloidosis (AA) is associated with various chronic inflammatory conditions (Rheumatoid arthritis, Psoriatic arthritis, Inflammatory bowel disease but lambda light chain deposition was seen on immunofluorescence in our case which goes contrary to secondary amyloidosis.

CONCLUSION

The exact etiology of amyloidosis is not clear but excess of antigenic stimulation has been found as an association with it. Renal amyloidosis serves as a fatal complication of long-term autoimmune conditions. Hereby, regular follow up and screening of patients should be done if patient have chronic autoimmune diseases to warrant early diagnosis of renal manifestations and significantly reduces morbidities.

Declaration by Authors

Acknowledgement: None

Source of Funding: None

Conflict of Interest: The authors declare no conflict of interest.

REFERENCES

1. Dember LM. Modern treatment of amyloidosis: unresolved questions. *J Am Soc Nephrol* 2009;1;20(3):469-72.
2. Gertz MA, Lacy MQ, Dispenzieri A, Hayman SR. Amyloidosis: diagnosis and management. *Clin Lymphoma Myeloma Leuk* 2005;1;6(3):208-19.
3. Chugh KS, Datta BN, Singhal PC, Jain SK, Sakhuja V, Dash SC. Pattern of renal amyloidosis in Indian patients. *Postgrad Med J* 1981; 663:31-5.
4. Eirin A, Irazabal MV, Gertz MA, Dispenzieri A, Lacy MQ, Kumar S, et al. Clinical features of patients with immunoglobulin light chain amyloidosis

- (AL) with vascular-limited deposition in the kidney. *Nephrol Dial Transplant* 2012;1;27(3):1097-101.
5. Hopfer H, Wiech T, Mihatsch MJ. Renal amyloidosis revisited: amyloid distribution, dynamics and biochemical type. *Nephrol Dial Transplant* 2011;1;26(9):2877-84.
 6. Moise R. Rheumatisme psoriasique et amylose. *Strasbourg Med* 1965; 16:245-53.
 7. Shorvon PJ. Amyloidosis and inflammatory bowel disease. *Am J Dig Dis* 1977; 22:209-13.
 8. Bergis M, Dega H, Planquois V, Benichou O, Dubertret L. Amyloidosis complicating psoriatic arthritis. *Ann Dermat Venereol* 2003;1(130):1039-42.
 9. Zachariae H, Hansen HE, Sogaard H, Olsen S. Kidney biopsies in methotrexate-treated psoriatics. *Dermat* 1990;181(4):273-6.
 10. Oikonomou K, Kapsoritakis A, Eleftheriadis T, Stefanidis I, Potamianos S. Renal manifestations and complications of inflammatory bowel disease. *Inflam bowel dis* 2011;17(4):1034-45.
- How to cite this article: Khan Fatima, Singhai Atin, Gupta Vaibhav, Babu Suresh, Dhakad Urmila. Renal vascular amyloidosis - a brainstormer manifestation of autoimmune diseases spectrum. *Int J Health Sci Res.* 2023; 13(10):89-92. DOI: [10.52403/ijhsr.20231012](https://doi.org/10.52403/ijhsr.20231012)
