

# A Case Report of Appendicitis and Management by Alternative Treatment of Medicine

Dr. Tanmay Sarkar<sup>1</sup>, Dr. Abhinandan Das<sup>2</sup>

<sup>1</sup>Lecturer-Department of Homoeopathic Pharmacy, Metropolitan Homoeopathic Medical College and Hospital, Ramchandrapur, Sodepur, Kolkata, West Bengal 700110, India

<sup>2</sup>Lecturer-Department of Physiology and Biochemistry, Bengal Homoeopathic Medical College and Hospital, MXC8+7G2, Ismile, Shatabdi Nagar, Asansol, West Bengal 713301, India

Corresponding Author: Dr. Tanmay Sarkar

DOI: <https://doi.org/10.52403/ijhsr.20220926>

## ABSTRACT

**Introduction:** Appendicitis is a common cause of abdominal pain. Large scale appendicitis patients are going to be treated surgically but sometimes complications are inherent to post-operative treatment. The most common postoperative complications are wound infection, intra-abdominal abscess, retrocecal abscess, intestinal perforation with peritonitis, bleeding, and adhesions ileus caused by intra-abdominal adhesions, which vary in frequency between open and laparoscopic appendectomy. At present-day it is treated safely in Homoeopathic medicine.

**Case Summary:** We are going to represent a case report of recurrent Acute Appendicitis which was successfully treated by the Individualized Homoeopathic Remedies. The results were evident within a few weeks, which further elucidated the role of constitutional treatment in homoeopathy.

**Keywords:** Homoeopathy, Calcarea Carbonica, Lycopodium Clavatum, Magnesium Phosphoricum, Nux Vomica, Appendicitis, Centesimal Scale, Ultrasonography.

## INTRODUCTION

The Vermiform appendix is a finger-like, blind-ended tube connected to the posteromedial wall of the cecum, about 30 mm below the ileocecal valve. The tip of the appendix is variable in position and might lie in a retrocecal, subcecal, retroileal, preileal or pelvic location. The variability in location may influence the clinical presentation of appendicitis [1] [2]. Appendectomy is the gold standard of treatment for acute appendicitis whereby, an inflamed appendix is removed [3]. Appendix is the reservoir for beneficial gut bacteria. The most common bacteria that can cause acute appendicitis are intestinal bacteria including Escherichia Coli and bacteria belonging to the Bactericides Fragilis group [4]. Their onset is sudden and has a definite course & quick expression of action. They

terminated within a short time either with complete recovery or after the death of the patient [5]. Appendectomy is re-inflammation of the residual appendiceal tissue after months to years. Appendicitis is the most common cause of acute abdomen requiring surgery. Prompt diagnosis is necessary as delayed diagnosis may lead to increased morbidity and mortality due to complications like perforation, gangrene, and phlegm on formation [6]. There are some postoperative complications after appendectomy including wound infection, intra-abdominal abscess, retrocecal abscess, intestinal perforation with peritonitis, bleeding and adhesions occurred. Appendectomy is very dangerous for Comorbidity patients as well. So, here is the beauty of homeopathic management in acute appendicitis. In the Aphorism, no. 72

& 73 were described the acute disease are the result of a rapid morbid process of the deranged vital force [7, 8]. Meanwhile, Homoeopathic intervention can manage appendicitis within a few weeks & it's shown through this case report with supporting documents.

### CASE REPORT/ PATIENT INFORMATION

A 19 years old Indian Hindu unmarried female patient comes to my O.P.D with severe right lower abdominal pain, tenderness & General weakness. Pain aggravated by the Jerking since last 2 weeks. Nausea & loss of appetite present. Low back pain with sometimes burning sensation in the throat. There was no history of trauma. She visited a surgeon who recommended surgical treatment. Occupationally she is a student. **USG shows-** Blind ended tender tubular structure resembling an appendix is seen in the right iliac fossa with a thickened wall. Impression- Appendicitis.

#### Past History

She has been suffering from Chickenpox at the age of 10 years and it's treated by homoeopathic medicine. Skin disease is treated by Allopathic medicine.

#### Family History

Her father suffers from Hypertension & Mother suffers from Osteoarthritis.

#### Mental Symptom

Nerves anxiety, restlessness and desire to escape. She is talkative, mistrustful, fearful, melancholy with grief.

#### Physical generals

Her appetite is Moderate. Desire- Spicy food, salted things, hot food, boiled egg, Aversion- Sweet. Thirst- Moderate (1-2 litre/ day). Her Tongue is Clean & moist, Thermal relation- Chilly, Urine- Normal, Sweat- mainly on the upper lip, she sleeps well enough/Normal, there is no specific Dream. Her stool is regular & semisolid.

#### Menstrual History

Menses flow Regularly, Amount- Normal, Duration to stay 5days & menstrual discharge bright red blood & felling very hot.

#### Totality of Symptoms

1. Talkative, mistrustful, fearful melancholy with grief.
2. Desire for salted things, spicy food, hot food, and boiled eggs
3. Chilly patient.
4. Clean and moist tongue.
5. Severe pain and tenderness in right lower abdomen.
6. Nausea and loss of appetite.

#### Discussion about choosing the drug-

Homoeopathic remedies are purely chosen on the bases of Totality of Symptoms. The remedies are Calcarea Carbonica, Lycopodium Clavatum, Magnesium Phosphoricum, Nux Vomica.

Consultation	Date	Medicine	Doses	Improvement
1 <sup>st</sup>	07/04/2021	Belladonna-30C, Calc. Carb- 200C	6 doses TDS, after 5 days 2 doses OD	Pain abdomen with severe tenderness
2 <sup>nd</sup>	18/04/2021	Magnesium Phosphoricum-6X	4tabs TDS	No pain with slight tenderness
3 <sup>rd</sup>	01/05/2021	Calc. Carb- 0/2	21 doses OD	No pain and no tenderness
4 <sup>th</sup>	23/05/2021	Calc. Carb- 200C	2doses OD	No pain and no tenderness
5 <sup>th</sup>	07/06/2021	Calc. Carb- 1M	2doses OD	Again pain starts with tenderness
6 <sup>th</sup>	27/06/2021	Lycopodium- 200C, (SOS) Belladonna-200C, Magnesium Phosphoricum- 3X	2doses OD, 6doses TDS, 4tabs TDS	Burning sensation in throat, body ache, pain abdomen without tenderness
7 <sup>th</sup>	19/07/2021	Lycopodium- 1M, Magnesium Phosphoricum- 3X	2doses OD, 4tabs TDS	No pain, no tenderness, no burning sensation
8 <sup>th</sup>	08/08/2021	Lycopodium- 10M, Magnesium Phosphoricum- 3X	2doses OD, 4tabs TDS	No pain, no tenderness
9 <sup>th</sup>	31/08/2021	Magnesium Phosphoricum- 3X	4tabs TDS	No pain, no tenderness
10 <sup>th</sup>	13/09/2021	Nux Vomica- 30C	6doses TDS	Pain abdomen before stool
11 <sup>th</sup>	02/11/2021	Saqlac-30C	6 doses TDS	Ultrasonography shows- no significant abnormality

## USG Report Shows

Blind-ended tender tubular structure resembling an appendix is seen in the right iliac fossa with a thickened wall.  
Impression- Appendicitis.

Fig.1 Before Homoeopathic treatment.

No significant abnormality.

Fig.2 After Homoeopathic treatment.

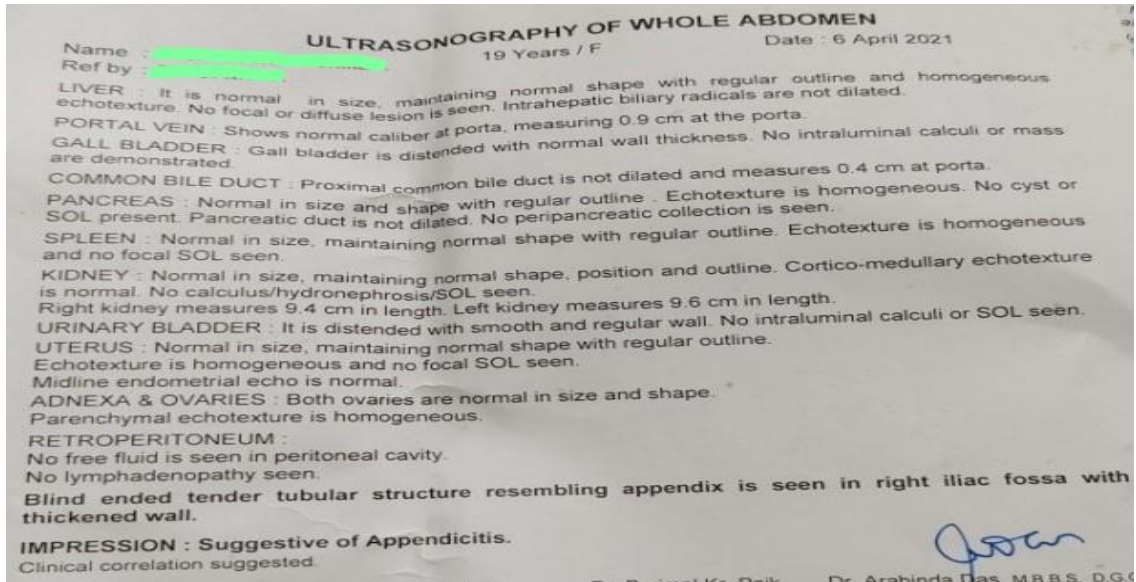


Fig.1 BEFORE HOMOEOPATHIC TREATMENT

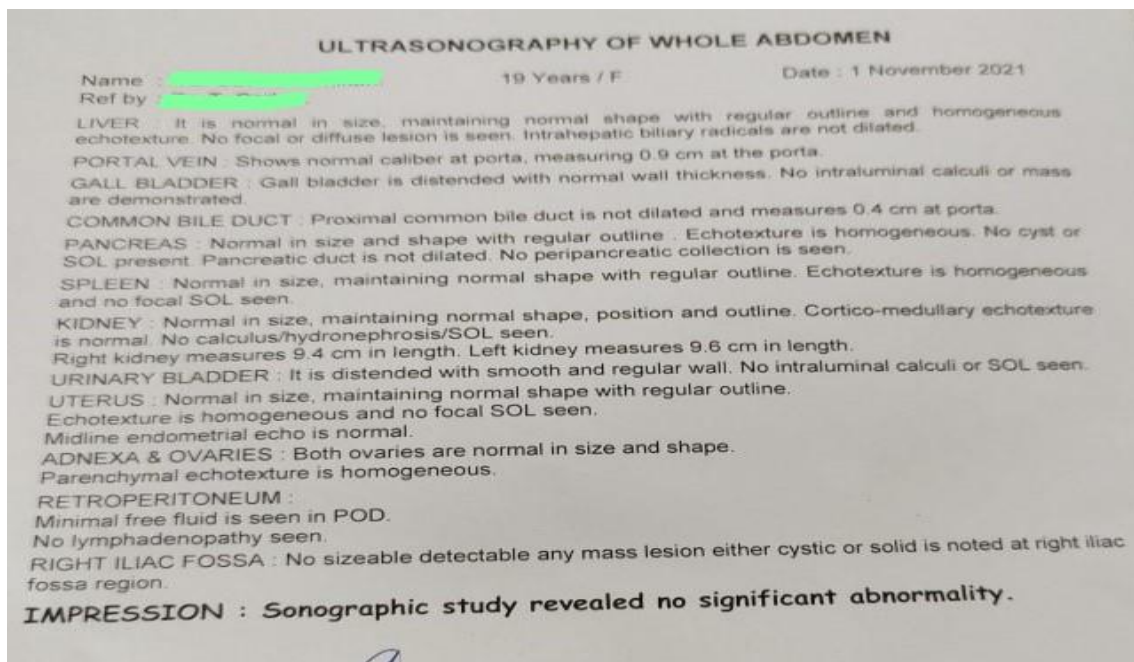


Fig.2 AFTER HOMOEOPATHIC TREATMENT

## DISCUSSION

Clinically, it is a disease with an acute onset of pain, which is initially per umbilical but later shifts to the right iliac fossa associated with anorexia, nausea and vomiting with a physical finding of marked tenderness at the right iliac fossa [9]. The incidence of

appendicitis gradually rises from birth, peaks in the late 10 years and gradually declines in the geriatric years. It is most prevalent in the 10-19-year-old age group. In recent years, the number of cases in patients aged 20-69 has increased to 6.3% [10]. Acute Appendicitis means the sudden

onset of inflammation in the appendix & In the Majority of the case this condition is called Acute Abdomen. It is probably in the majority of cases caused by an obstruction of the lumen [11]. Some Postoperative complications occurred after appendectomy including wound infection, intra-abdominal abscess, retrocecal abscess, intestinal perforation with peritonitis, bleeding and adhesions occurred [12]. Appendectomy is very dangerous for comorbidity patients as well. In that particular case, Homoeopathy works tremendously well. So, we are going to represent a case report on Acute Appendicitis. After the case taking totality of the symptom was done & prescribed based on it. *Belladonna-30C, Calc. Carb-200C* was prescribed when the symptom is severe pain with tenderness in the abdomen, after 1 week the pain was gone but tenderness remained. In 3<sup>rd</sup> follow up the patient was in good health, with no pain & no tenderness happened.

## CONCLUSION

In present day Homoeopathy is the great system of the alternative system of medicine. In this case, we present how a surgical case is treated with Homoeopathic medicines. This case illustrates for potential benefits and utility of homoeopathic treatment for Appendicitis.

**Acknowledgement:** None

**Conflict of Interest:** None

**Source of Funding:** None

## REFERENCES

1. Buschard K, Kjaeldgaard A. Investigation and analysis of the position, fixation, length and embryology of the vermiform appendix. *Acta Chirurgica Scandinavica*. 1973 Jan 1;139(3):293-8.
2. Guidry SP, Poole GV. The anatomy of appendicitis. *The American surgeon*. 1994 Jan 1;60(1):68-71.
3. Naveen K, Sareesh NN, Satheesha BN, Murlimanju BV, Suhani S, Mamatha H, Sampath PK. Appendicitis and appendectomy: A retrospective survey in South Indian population. *J Surg Acad*. 2013;3(2):10-3.
4. Nakhamiyayev V, Galldin L, Chiarello M, Lumba A, Gorecki PJ. Laparoscopic appendectomy is the preferred approach for appendicitis: a retrospective review of two practice patterns. *Surgical endoscopy*. 2010 Apr;24(4):859-64.
5. [http://nhp.gov.in/Classification-of-diseases\\_mtl](http://nhp.gov.in/Classification-of-diseases_mtl)
6. Kumar R, Chauhan R. Clinico-Epidemiological Profile of Acute Appendicitis in a Tertiary Care Hospital in North India.
7. Hahnemann Samuel, Translated from the fifth edition, with an Appendix, by R.E. Dodgeon; "Organon of Medicine".
8. Banerjea Kumar Subrata, "Miasmatic Prescribing"
9. Obsa MS, Adema BG, Shanka GM, Lake EA, Azeze GA, Fite RO. Prevalence of acute appendicitis among patient admitted for acute abdomen in Ethiopia: systematic review and meta-analysis. *International Journal of Surgery Open*. 2020 Jan 1;26:154-60.
10. Lohar HP, Calcuttawala MA, Nirhale DS, Athavale VS, Malhotra M, Priyadarshi N. Epidemiological aspects of appendicitis in a rural setup. *Medical Journal of Dr. DY Patil University*. 2014 Nov 1;7(6):753.
11. Nakhamiyayev V, Galldin L, Chiarello M, Lumba A, Gorecki PJ. Laparoscopic appendectomy is the preferred approach for appendicitis: a retrospective review of two practice patterns. *Surgical endoscopy*. 2010 Apr;24(4):859-64.
12. Kafae M, Kheirkhah MT, Balali R, Gharibzadeh S. Conflict of interest as a cognitive bias. *Accountability in Research*. 2022 Aug 18;29(6):379-96.

How to cite this article: Tanmay Sarkar, Abhinandan Das. A case report of appendicitis and management by alternative treatment of medicine. *Int J Health Sci Res*. 2022; 12(9):190-193.  
DOI: <https://doi.org/10.52403/ijhsr.20220926>

\*\*\*\*\*