

Mirror Therapy in Postherpetic Neuralgia: A Case Report

Sharmila Chaudhuri¹, C.S. Ram²

¹Assistant Professor, Department of Physiotherapy, I.T.S Institute of Health & Allied Sciences, Uttar Pradesh, India

²Professor, Department of Physiotherapy, I.T.S Institute of Health & Allied Sciences, Uttar Pradesh, India

Corresponding Author: Sharmila Chaudhuri

DOI: <https://doi.org/10.52403/ijhsr.20220818>

ABSTRACT

Herpes zoster is a disease caused by the reactivation of the latent varicella-zoster virus in the cranial or spinal sensory ganglion. It is characterized by pain full rash, postherpetic neuralgia and affects 10-20% of all people. The incidence rate varies from one to two cases per 1000 in young adults to 10 times this figure in the elderly. Risk of Herpes increases with old age, malignancies, immunosuppressants, autoimmune disorders such as systemic lupus erythematosus (SLE), or HIV infection. Here there is a case of a 63-year-old woman with symptoms of post herpetic neuralgia 3weeks after the infection involving the C5-C6 dermatome. The present article highlight neuralgia as one of the complications of herpes infection and the role of physiotherapy along with mirror therapy in the patient's functional improvement. Outcome measures were, range of motion (ROM) measured by Goniometer, muscle strength measured by manual muscle test (MMT), pain measured by Numeric pain rating scale (NRPS), and improvement in the functions measured by patient-specific functional scale (PFPS). Early diagnosis and 6 weeks of physiotherapy intervention showed marked improvement in pain, ROM, muscle strength, and patient-specific functional score and prevented further complications

Keywords: [Herpes Zoster, Post herpetic neuralgia, Mirror therapy, Physiotherapy]

INTRODUCTION

Herpes zoster is a disease caused by the reactivation of the latent varicella-zoster virus cranial or spinal in the sensory ganglion. It is characterized by pain full rash, postherpetic neuralgia and affects 10-20% of all people. The incidence rate varies from one to two cases per 1000 in young adults to 10 times this figure in the elderly. Risk of Herpes increases with old age, malignancies, immunosuppressants, autoimmune disorders such as systemic lupus erythematosus (SLE), or HIV infection^[1]. Postherpetic neuralgia can, not only affect the quality of life but also causes functional impairment due to the spread of infection from the dorsal horn cell to the

anterior horn cell. The purpose of this study is the identification and early intervention of postherpetic neuralgia and to prevent secondary complications.

CASE REPORT

A 63-year-old lady came into the physiotherapy department with pain and difficulty doing activities with the left upper limb for the past 20 days. According to the patient, she had a herpes infection of the left upper limb 3weeks back followed by pain and sudden weakness of the left upper limb. The patient was initially prescribed acyclovir for a period of 2 weeks and later managed by Gabapentin and analgesic for the next 4 weeks by a neurologist. She had

no past medical history of diabetes, hypertension, or any other cardiovascular diseases. There was no history of any recent surgeries or trauma. She was endomorphic in built, non-smoker and non-alcoholic, married, and having two children. The pain score was 7 measured on the NRPS scale [2]. On observation, the skin was dry and scaly with recovered rashes on the posterior left forearm, arm, and tip of the thumb. There was no marked wasting of the Left upper limb as compared to the right upper limb. Informed consent was taken from the patient. The examination found the weakness of the left shoulder abductor 2+/5, and elbow flexors 2+/5, in line with the myotome distribution of C5 and C6. MMT was used to evaluate the strength of the shoulder, elbow, wrist, and finger muscles [3]. Deep tendon reflexes for bilateral upper limb were intact with the absence of any neurological deficit although she was

having pins and needle sensation in the thumb. There was a restricted range of motion of the left shoulder, along with the elbow and the fingers. Both active and passive ROM was measured with the help of a goniometer[4]. Mild Oedema was present on the dorsal aspect of the hand. Exquisite pain was present on flexion of the thumb and the patient was not able to make a fist. The patient was asked to rate the functional limitation in day-to-day activity on the PFPS [5]. The patient underwent physiotherapy sessions for 6 weeks, 6 days a week, each session was 60 minutes in duration. Physiotherapy sessions included thermotherapy, mirror therapy, range of motion exercises, progressive resistance, and stretching exercises (Fig 1). Initially, hot pack was given for first week for 20 min to relax the muscle.

Fig. 1: Patient undergoing Mirror therapy

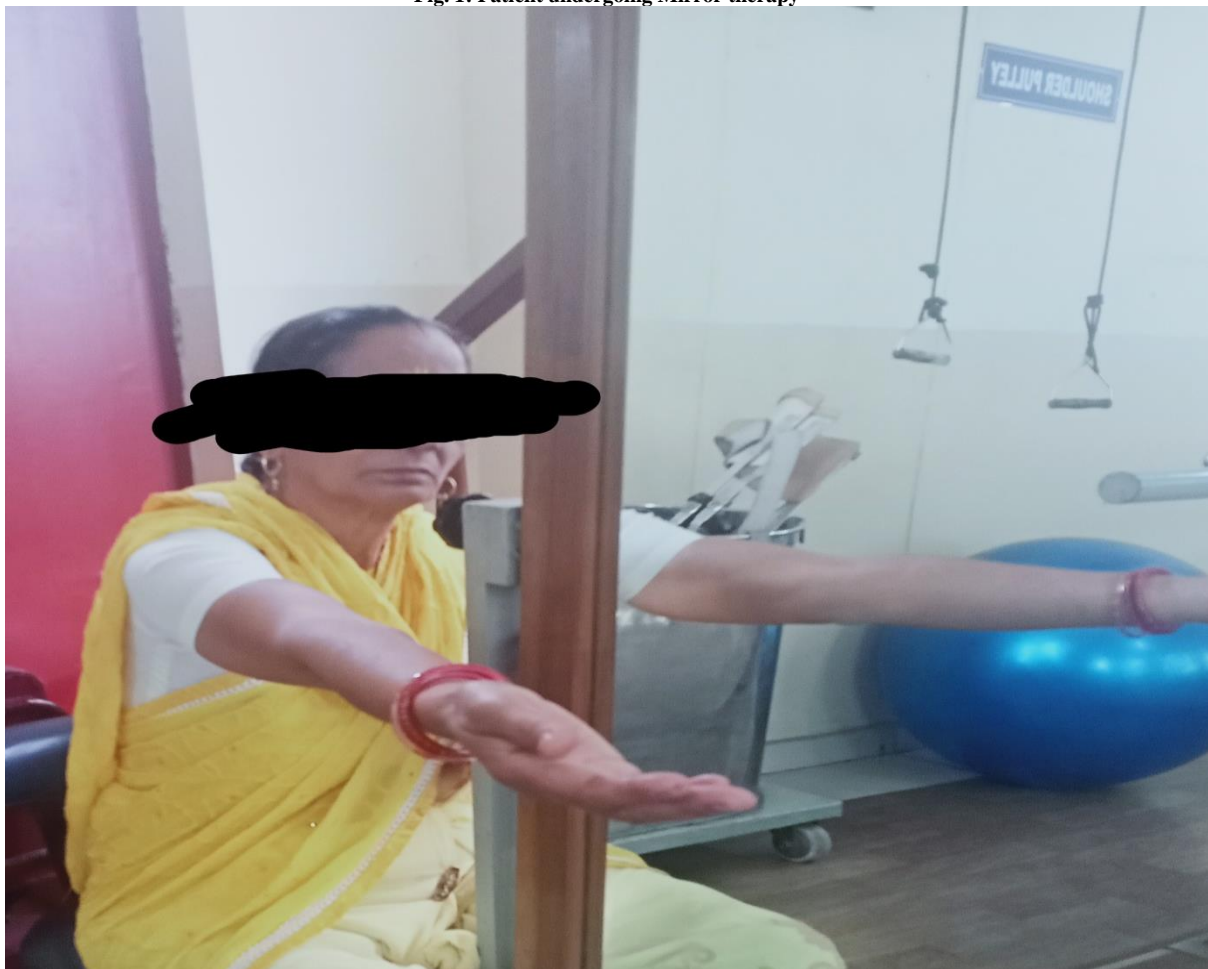


Table:1 Mirror therapy Exercise Protocol

1 st week	Active range of motion exercises for shoulder, elbow, wrist, thumb and finger were given. A dosage of 10 repetitions twice a day
2 nd -4 th week	Range of motion exercises was continued but the frequency of exercise was increased to 20 times twice a day. The patient was asked to do different activities with the help of Thera putty to facilitate gripping activities.
5 th -6 th week	Progressive resisted exercises were started for the abductor of the shoulder, flexors of the elbow, and wrist. Initially weight was given starting from .5kg which was progressed to 1.5 kg. A hand therapy exercise ball was given to improve the grip and fine motor skills. The finger spring exerciser was started with minimum resistance and was progressed according to the tolerance. Task-oriented functional activities were started to make the patient fully independent and do her household chores like holding a glass, grooming, eating, cleaning, putting objects in upper shelves etc.

After 6 weeks the patient was put on the home program, the patient was advised to do rubber band exercises in which a rubber band was placed between the index finger and the thumb, and the patient was asked to stretch the rubber band for improving the strength of the fingers. Sponge ball exercises were explained to improve the grip. Strengthening exercises with a bottle filled with water were taught to the patient for the shoulder, elbow, and wrist. The patient was advised to do a follow-up every 15 days.

RESULT

Results

After intensive physiotherapy sessions, the NRPS score was reduced to 1 and the patient-specific functional score improved from 1 to 6 (Fig 2). The patient was able to do overhead activities along with improved gross hand motor functions like holding a glass, bathing, eating, grooming, putting things on upper shelves, etc. After 6 weeks there was a marked improvement in the shoulder, elbow, and finger movements and strength

Fig 2 Pain and functional score improvement pre and post-treatment

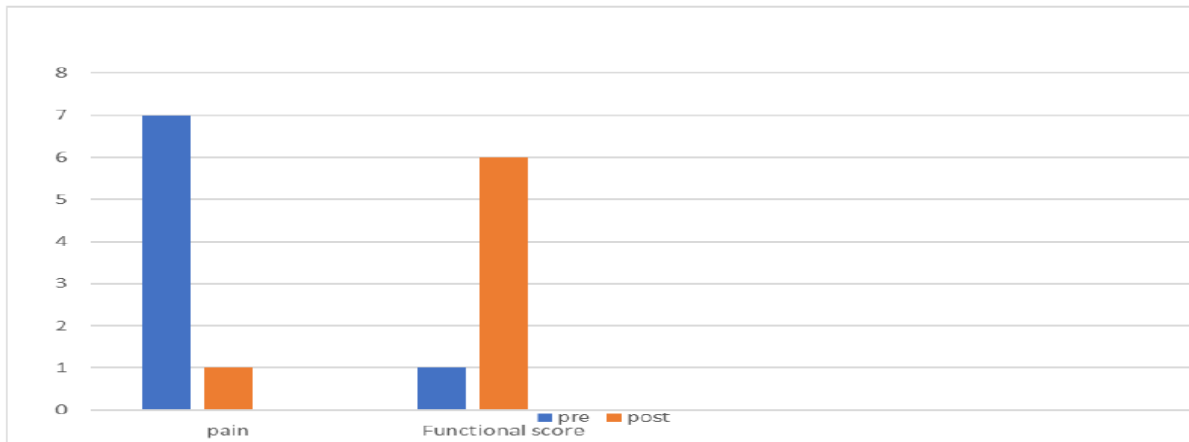


Table:3 Range of motion improvement on treatment various joint pre and post treatment

	Pre-treatment		Post treatment	
	Active	Passive	Active	Passive
Shoulder Flexion	0-95	0-160	0-150	0-175
Shoulder Abduction	0-80	0-150	0-140	0-150
Shoulder External Rotation	0-40	0-70	0-60	0-70
Shoulder Internal Rotation	0-55	0-70	0-65	0-70
Elbow Flexion	0-20	0-50	0-110	0-120
Elbow Extension	WNL	WNL	WNL	WNL
Supination	0-50	0-70	0-60	0-70
pronation	WNL	WNL	WNL	WNL
Wrist flexion	0-35	0-70	0-50	0-70
Wrist Extension	0-55	0-70	0-65	0-70
MCP flexion	0-20	0-60	0-40	0-70
MCP extension	0-5	0-15	0-15	0-15
Thumb flexion	0-10	0-50	0-35	0-50
Thumb extension	0-5	0-15	0-10	0-15
Thumb abduction	0-5	0-50	0-25	0-50

WNL-With in normal limit

Table:4 Strength of muscles improvement on various joint pre and post-treatment

Strength of Muscles		
	Pre- treatment	Post- treatment
Shoulder Flexors	3/5	4/5
Shoulder Abductors	2+/5	4/5
Elbow Flexors	2+/5	4/5
Elbow Extensors	WNL	WNL
Finger Flexor	3/5	3+/5
Finger Extensor	3/5	4/5
Thumb Flexor	2/5	4/5
Thumb Extensor	3/5	4/5

DISCUSSION

The most common complications of Herpes are postherpetic neuralgia, followed by peripheral motor neuropathy, cranial nerve palsies, myelitis, etc. Foster et al in their case report mentioned the presence of algoneurodystrophy following herpes zoster. Pain can lead to immobilization which may further progress to dystrophy of the muscle [6]. However, in this case, no disuse atrophy was seen as early intervention prevented disuse atrophy due to pain from postherpetic neuralgia. Richardson 1954 mentioned in his case report that disuse alone can lead to trophic changes in bones, subcutaneous tissue, and skin [7]. The treatment for segmental paresis includes analgesic for post-herpetic neuralgia, protection of the weakened muscles, maintenance of range-of-movement exercises, and a program of graduated strengthening exercises. In this case, thermotherapy along with mirror therapy was given to reduce the pain and stiffness in the joints. The effect of mirror therapy on post herpetic neuralgia have not been reported. Ramachandran and Rogers-Ramachandran (1996) introduced mirror therapy as an innovative treatment intervention for rehabilitation [8]. In this therapy, the patient observes the mirror image of the unaffected side, which results in activation of visual and somatosensory area leading to the increased motor activity of the affected limb. Mirror therapy has been found to be effective in reducing pain and functional improvement of patients with stroke and complex regional pain syndrome [9]. As soon as the pain was reduced progressive resisted exercises were started 4th week onwards. A gradual increase in the range of motion along with a progressive

increase in the resistance helped the patient to regain her strength. In this case mirror therapy along with conventional therapy was found to be effective in reduction of pain and further improvement of the patient. Although Complete or near-normal recovery occurs in 2/3rd of the patient, but if untreated it may take many months to recover, leading to various complications [10]. In this case due to early intervention, the patient was able to do all the overhead activities along with improved gross and fine hand motor functions by the end of 6 weeks. Task-oriented activities helped the patient to regain hand motor functions. One of the main limitations of the study was the short duration of the study, which was of 6 weeks and after that, the patient was put under the home program.

CONCLUSION

Besides conventional treatment, mirror therapy is very helpful in the management of post herpetic neuralgia. This is particularly important for elderly patients as early intervention will prevent various complications like contractures, disuse atrophy and improved the quality of life.

Acknowledgement: None

Conflict of Interest: None

REFERENCES

1. Chapman JR, Norvell DC, Hermsmeyer JT, Bransford RJ, DeVine J, McGirt MJ, et al. Evaluating Common Outcomes for Measuring Treatment Success for Chronic Low Back Pain: Spine. 2011 Oct;36:S54–68.
2. Aitkens S, Lord J, Bernauer E, Fowler WM, Lieberman JS, Berck P. Relationship of manual muscle testing to objective strength measurements. Muscle Nerve. 1989 Mar;12(3):173–7.
3. Gajdosik RL, Bohannon RW. Clinical Measurement of Range of Motion. Physical Therapy. 1987 Dec 1;67(12):1867–72.
4. Horn KK, Jennings S, Richardson G, van Vliet D, Hefford C, Abbott JH. The Patient-Specific Functional Scale: Psychometrics, Clinimetrics, and Application as a Clinical

- Outcome Measure. *J Orthop Sports Phys Ther.* 2012 Jan;42(1):30-D17.
5. Foster O, Askaria A, Lanham J, Perry D. Algoneurodystrophy following herpes zoster. *Postgraduate Medical Journal.* 1989 Jul 1;65(765):478–80.
 6. Richardson AT. Shoulder-Hand Syndrome Following Herpes Zoster. *Rheumatology.* 1954;2(4):132–4.
 7. Synaesthesia in phantom limbs induced with mirrors. *Proc R Soc Lond B.* 1996 Apr 22;263(1369):377–86.
 8. Saha S, Sur M, Ray Chaudhuri G, Agarwal S. Effects of mirror therapy on oedema, pain and functional activities in patients with poststroke shoulder-hand syndrome: A randomized controlled trial. *Physiother Res Int* [Internet]. 2021 Jul [cited 2022 Jul 13];26(3). Available from: <https://onlinelibrary.wiley.com/doi/10.1002/pri.1902>
 9. Purbasari B, Kurniawan SN. Herpes Zoster Radiculopathy in a Systemic Lupus Erythematosus Patient – A Case Report. *European Neurological Review.* :4.

How to cite this article: Sharmila Chaudhuri, C.S. Ram. Mirror therapy in postherpetic neuralgia: a case report. *Int J Health Sci Res.* 2022; 12(8):122-126.
DOI: <https://doi.org/10.52403/ijhsr.20220818>
