

# Ectopic Deciduosis of Rectus Abdominis Muscle Mimicking Metastatic Nodules

Nanda Patil<sup>1</sup>, Shubhang Monpara<sup>2</sup>, Nidhi Goswami<sup>2</sup>

<sup>1</sup>Professor, Department of Pathology, Krishna Institute of Medical Sciences, Deemed to Be University, Karad.

<sup>2</sup>Tutor, Department of Pathology, Krishna Institute of Medical Sciences, Deemed to Be University, Karad.

Corresponding Author: Nidhi Goswami

DOI: <https://doi.org/10.52403/ijhsr.20220816>

## ABSTRACT

Ectopic decidual tissue can occur outside the endometrium on the surface of uterus, ovaries, peritoneum, fallopian tubes or appendix. Most cases present with incidental finding during cesarean section and does not require treatment. However, deciduosis on the surface of peritoneum or muscle tissue can mimic metastatic deposits and histopathological examination is required for confirmation of diagnosis. We present a case of ectopic deciduosis of rectus abdominis muscle which was clinically suspected as metastatic deposits.

**KEYWORDS:** Deciduosis, Ectopic localization, Metastatic deposits, Rectus muscle.

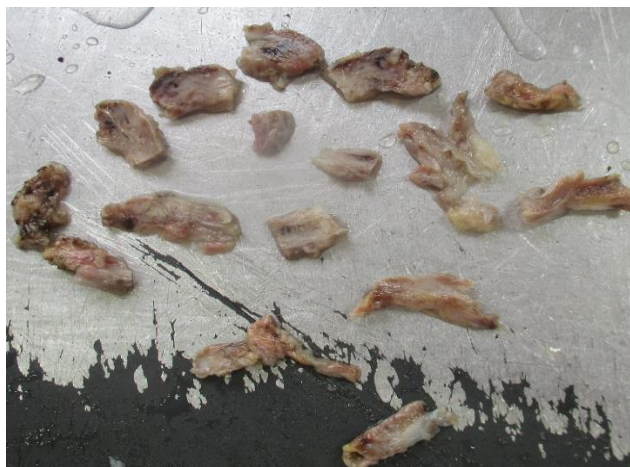## CASE REPORT

A 23 years old female patient (G2P1L1) presented with pain in lower abdomen with nine months of amenorrhea. USG abdomen revealed deposits on rectus abdominis muscle mimicking metastatic nodules. LSCS was done, during the procedure small yellowish white nodular deposits were observed on the surface of rectus abdominis

muscle. Considering them as a metastatic deposits, bits of rectus muscle were sent for histopathological examination.

## Histopathological report

We received bits of rectus muscle totally measuring 6 x 3 x 1.5 cm. Serial sectioning revealed multiple yellowish white deposits aggregate measuring 3.9 x 1.6 x 0.8 cm.



Gross examination – yellowish white deposits on the surface of rectus abdominis muscle received in pieces.

Microscopy of these nodules revealed sheets of decidual tissue infiltrating the muscle fibres with focal inflammatory reaction.

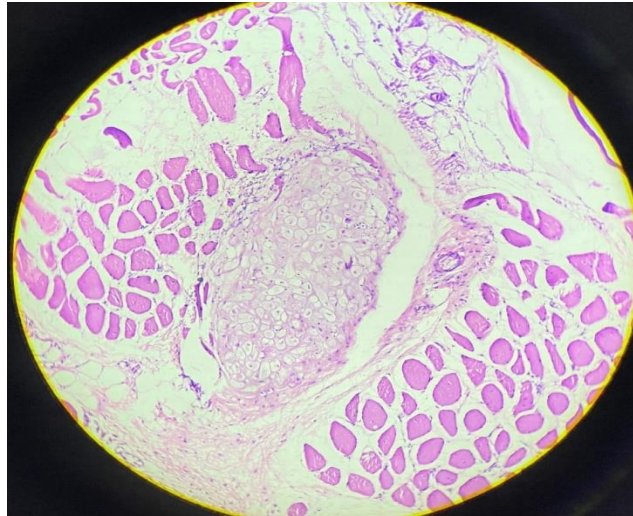


Figure 2:

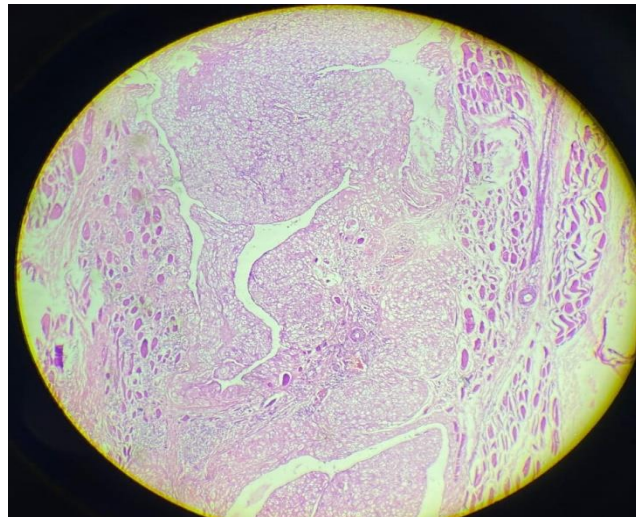


Figure 3:

Microscopy - Sheets of decidual tissue infiltrating in the muscle fibres (100 x H and E).

Considering the histopathological features, diagnosis was given as ectopic decidualis of rectus abdominis muscle.

### DISCUSSION

Ectopic decidualis is presence of decidual tissue outside the uterus [1,2]. Pathogenesis of this condition is not clear but is thought to be a progesterone induced metaplasia of the coelomic stroma [3]. Sites of ectopic decidualis are surface of uterus, ovaries, fallopian tubes as well as peritoneum. On

rare occasion it can be observed in lymph nodes, lungs, kidneys, skin and other organs [4,5,6]. Ectopic decidualis most of the times does not cause any symptoms and resolves spontaneously 4 to 6 weeks after delivery [7]. Ectopic decidual tissue on the wall of appendix can present as acute abdomen [8]. Peritoneal and muscle involvement can mimic peritoneal metastasis and mislead clinicians [9,10]. Other urgent manifestations of this condition are tubo ovarian abscess, intraperitoneal haemorrhage, bowel obstruction and dystocia [11]. In our case patient presented with decidualis of rectus abdominis muscle

with pain in abdomen. Pelvic ultrasonography or magnetic resonance imaging may be helpful to detect the lesion. However small size of nodule may lead to missing of the lesion.

Microscopic appearance of ectopic decidua can be easily mistaken for a tumor as it appears as yellowish white nodules or plaques. In the present case ectopic decidualis was involving rectus abdominis muscle and was detected on ultrasonography as metastatic deposits. The correct diagnosis was possible with histopathological examination.

### CONCLUSION

Ectopic decidualis is pregnancy related, self limited disease which mimics metastatic deposits on gross examination and radiological investigations.

Histopathological examination confirms diagnosis and avoids further unnecessary treatment.

**Acknowledgement:** None

**Conflict of Interest:** None

### REFERENCES

1. P. Zaytsev and J. B. Taxy, "Pregnancy-associated ectopic decidua, *Am. J. Surg. Pathol.* 1987. 11, (7) 526–530.
2. F. Bolat, T. Canpolat, and E. Tarim, "Pregnancy-related peritoneal ectopic decidua (decidualis): morphological and clinical evaluation, *Turk. Patoloji Derg.* 2012. 28, (1), 56–60.
3. Kondi-Pafiti, D. Grapsa, K. Kontogianni-Katsarou, K. Papadias, and E. Kairi-Vassilatou, "Ectopic decidua mimicking metastatic lesions—report of three cases and review of the literature, *Eur. J. Gynaecol. Oncol.* 2005. 26, (4), 459–461.
4. G. A. Markou, I. Goubin-Versini, O. M. Carbutaru, C. Karatzios, J. M. Muray, and

- M. Fysekidis, "Macroscopic decidualis in pregnancy is finally a common entity, *Eur. J. Obstet. Gynecol. Reprod. Biol.* 2016. 197, 54–58.
5. D. B. Flieder, C. A. Moran, W. D. Travis, M. N. Koss, and E. J. Mark, "Pleuro-pulmonary endometriosis and pulmonary ectopic decidualis: a clinicopathologic and immunohistochemical study of 10 cases with emphasis on diagnostic pit-falls, *Hum. Pathol.* 1998. 29, (12). 1495–1503.
6. K. P. Fair, J. W. Patterson, R. J. Murphy, and R. J. Rudd, "Cutaneous decidualis, *J. Am. Acad. Dermatol.* 2000. 43, (1), 102–107.
7. A. Büttner, R. Bässler, and C. Theele, "Pregnancy-associated ectopic decidua (decidualis) of the greater omentum, *Pathol. Res. Pract.* 1999. 189, (3), 352–359.
8. E. Dogan, E. Okyay, B. Saatli, S. Olgan, S. Sarioglu, and M. Koyuncuoglu, "Tubal ovarian abscesses formation from decidualized ovarian endometrioma after appendiceal endometriosis presenting as acute appendicitis in pregnancy," *Iran. J. Reprod. Med.* 2012, 10, (3), 275–278.
9. D. B. Cruz, T. Dhamer, V. W. da Rocha, and R. F. Dupont, "Diffuse peritoneal decidualis mimicking metastatic lesions" *Clin. Case Rep.* 2014. 51, 519–520.
10. L. J. Adhikari and R. Shen, "Florid diffuse peritoneal decidualis mimicking carcinomatosis in a primigravida patient: a case report and review of the literature, *Int. J. Clin. Exp. Pathol.* 2013. 6, (11), 2615–2619.
11. S. M. O'Leary, "Ectopic decidualization causing massive postpartum intraperitoneal haemorrhage, *Obstet. Gynecol.* 2006. 108, Supplement, 776–779.

How to cite this article: Nanda Patil, Shubhang Monpara, Nidhi Goswami. Ectopic decidualis of rectus abdominis muscle mimicking metastatic nodules. *Int J Health Sci Res.* 2022; 12(8):115-117.  
DOI: <https://doi.org/10.52403/ijhsr.20220816>

\*\*\*\*\*