

# Indigenous Orthotic Management of Torticollis: A Case Study

Jibanjeet Mohanty<sup>1</sup>, Lalitkumar Nayak<sup>2</sup>

<sup>1</sup>Assistant Professor, Prosthetics and Orthotics Training,  
Mobility India Rehabilitation Research & Training Center, Bangalore, India

<sup>2</sup>Prosthetist and Orthotist, Composite Regional Center, Patna

Corresponding Author: Jibanjeet Mohanty

DOI: <https://doi.org/10.52403/ijhsr.20220535>

## ABSTRACT

Torticollis is a condition with the neck muscles that causes the head to tilt downward and lateral with transverse plane rotation. Moreover, such involvement is due to the contracture of sternocleidomastoid muscle which may cause many complications in the later stage of life such as neurological conditions from compressed nerve, chronic pain, difficulty in performing routine task etc. Therefore, immediately after the investigation conservative treatment through braces and physiotherapy play an important role in reducing the complications. The purpose of the study is to fabricate an indigenous torticollis brace to control the unwanted motion of neck and correct the deformity.

**Key words:** Torticollis, Torticollis brace

## INTRODUCTION

Torticollis is a congenital shortening of the sternocleidomastoid muscle, which causes the head to bend to one side and rotate in the opposite direction. This disorder, often known as "wry neck" syndrome, appears immediately after delivery<sup>[1]</sup>. Torticollis can be hereditary, acquired, or idiopathic (occurring without a recognised cause), and it can strike at any age. Torticollis acquired after trauma or sickness is far more difficult to treat. Surgical release of the tight sternocleidomastoid muscle is usually recommended, followed by rigorous physical therapy to lengthen the contracture. Frequently, the surgeon is interested in treating the abnormality by gently repositioning the head in correct position. Many traditional cervical orthoses such as Static rotational control cervical orthosis, tubular orthosis, Buckminster- Brown orthosis, on the other hand, are static and

have limited adjustability, comfort, and convenience of usage<sup>[2,3,4]</sup>. As a result, these orthoses can only keep the head and neck in the same position for the duration of the immobilization. An improved orthosis must be light, less bulky, dynamic, and easily adjustable in all planes, so that it not only retains the head and neck in a corrected posture but also has the ability to exert corrective pressures to achieve further correction, or over-correction<sup>[5]</sup>.

## METHODOLOGY

### Case Description

The subject was a 12-year-old male who was having idiopathic torticollis which causes the shortening of length of the sternocleidomastoid muscle of the right side. As a result, the head tilts towards right side and rotate to the opposite side. He was finding difficulty in performing activities of daily living. Also he was complaining about numbness over the upper extremity.

### Objective of the study

- To design and fabricate a multi adjustable torticollis brace that must hold the head in correct position and provide corrective force to correct the deformity.
- To relieve the numbness over upper extremity and ease the activities of daily living.

### Design Concept

The orthosis is designed without sacrificing the biomechanical principle. As we know the cervical spine is much more flexible than the remainder of the spine and it supports a head that weighs 10 Pounds or more, therefore by the application of any

external or internal forces on the surrounding structures lead to injury, degeneration and inflammatory paralytic, neoplastic and infectious disorders. This orthosis is designed in such a manner that, it can realign the cervical spine and cervico - occipital joint and can relieve gravitational stress by weight transfer (Fig 1). It can also maintain the head in any desired position with respect to cervical flexion, lateral flexion and transverse rotation due to its indigenous design (Fig 2). Along with that it has the provision for height adjustment and has proper facilitation for Donning and doffing due to the strapping system (Fig 3).




Fig 1: Torticollis orthosis




Fig 2: Parts of torticollis orthosis



Fig 3: strapping and padding material

- Temporal Head A-P
- Temporal Head M-L
- Base of Neck to Mandible A-P
- Temporal Head Circumference

Normal casting procedure was followed. Cling film was applied over the head, base of neck and over shoulder (Fig4). Then necessary markings were done followed by the application of pop bandages (Fig5,6). Proper holding position was maintained during plaster impression for correction.

### Fabrication Procedure

After assessment and evaluation following measurements were taken for the fabrication of the orthosis



Fig 4: casting preparation

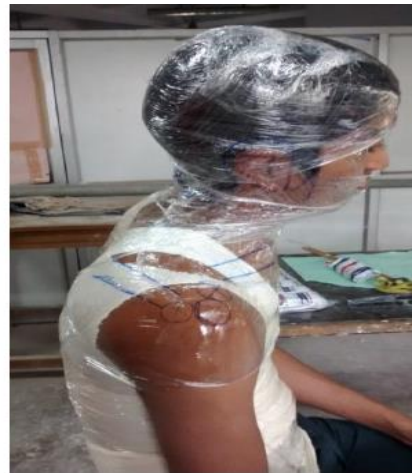

Fig 5: Marking landmarks

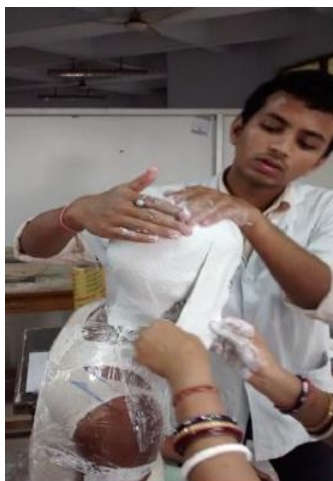

Fig 6: Casting



Fig 7: moulding

No specific modification was done. Only smoothening of the surface was done. Moulding was done by 4 mm. polypropylene sheet (Fig 7). After the moulding of head and shoulder piece it is trimmed in such a manner that both the

components will confirm proper fit and comfort to the patient. After the fabrication of proper helmet and shoulder piece, multiplane adjustable torticollis joint is fabricated (Mount with connector) with mild steel.

In the proximal mount there is the provision for height adjustment and in the distal mount there is the provision for rotational adjustment. In between the proximal and distal mount, there is a connector which is responsible for antero-posterior and lateral angular adjustment. Size-I orthotic hip joint is used to make the connector and there is the provision for angular adjustment in 15 degree interval up to 60 degrees. Also there is a provision for locking at the joint in desired position. The 1 inch velcro straps were attached with the nylon webbing for proper suspension and adjustment over the head and shoulder.

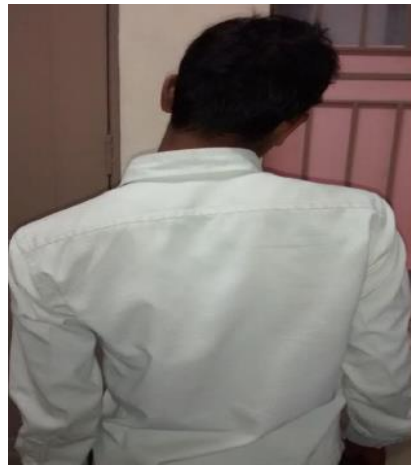

Fig 8: Subject without orthosis



Fig 9: Subject with orthosis

After the attachment of D-ring and velcro strap, colourful Ethaflex is attached inside the helmet and shoulder piece for comfort and cosmesis.

## RESULT

After the successful fabrication it has trialled over the subject and seen that, the contracture can be corrected gradually by adjustment in cervical flexion and transverse rotation angle (Fig 8, 9). The subject found it comfortable while performing activities of daily living and numbness over upper extremity is reduced.

## DISCUSSION

The traditional orthoses for torticollis were ugly, heavy, bulky and difficult to apply. To overcome the problems the new dynamic torticollis brace is designed and developed for the management of muscular torticollis. There is the facility to adjust in cervical flexion, lateral flexion and transverse rotation. This freedom of rotation allows treatment to begin in a neutral rotation position, and progressively stretches a tight sternocleidomastoid muscle by slowly increasing the rotation angle. Though it incorporates better facility for correction and easy handling

## CONCLUSION

This design is cable enough to hold the head in correct position while correcting

the torticollis. The indigenous design helps the subject to perform the activities of daily living at ease and reduces radiating pain or numbness over the upper extremity by maintains the correct posture of the neck. For the better result, it should be used along with physical therapy. However, the efficacy of the orthosis can be found after several fitment and timely follow-up.

**Acknowledgement:** None

**Conflict of Interest:** None

**Source of Funding:** None

## REFERENCES

1. Stassen LF, Kerawala CJ. New surgical technique for the correction of congenital muscular torticollis (wry neck). British

- Journal of Oral and Maxillofacial Surgery. 2000 Apr 1;38(2):142
2. Torticollis CM. Static Rotational Control Cervical Orthosis for the Treatment of Congenital Muscular Torticollis and Associated Plagiocephaly and Hemihypoplasia. Orthotics and Prosthetics!. 1982:13.
  3. Kuo AA, Tritasavit S, Graham JM. Congenital muscular torticollis and positional plagiocephaly. Pediatrics in review. 2014 Feb 1;35(2):79-87.
  4. Joshi CH, Mathur LC, Oberoi LC. Role of CephaloCervico Thoracic Dynamic Splint in Management of Congenital Torticollis. OrthProsth. 1984 Jan 1;38:54-7.
  5. Cheng CY, Ho KW, Leung KK. Multi-adjustable post-operative orthosis for congenital muscular torticollis. Prosthetics and Orthotics International. 1993 Jan 1;17(2):115-9.
- How to cite this article: Jibanjeet Mohanty, Lalitkumar Nayak. Indigenous orthotic management of torticollis: a case study. *Int J Health Sci Res.* 2022; 12(5):327-331. DOI: <https://doi.org/10.52403/ijhsr.20220535>

\*\*\*\*\*