

Symplastic Leiomyoma of Uterus - A Rare Case with Review of Literature

Nanda Patil¹, Avinash Mane², Parin Upadhyay³, Pallavi Bhosale³

¹Professor, ²Assistant Professor, ³Tutor, Department of Pathology, KIMS Deemed to be University, Karad.

Corresponding Author: Parin Upadhyay

DOI: <https://doi.org/10.52403/ijhsr.20220335>

ABSTRACT

Symplastic leiomyoma is a rare variant of leiomyoma, also called as atypical or bizarre leiomyoma. Recently introduced term is leiomyoma with bizarre nuclei. These are leiomyomas which show cells with moderate to severe cytoplasmic atypia, but absence of cell necrosis and lower mitotic activity. We present a case of symplastic leiomyoma in a 45-year old female patient who presented with menorrhagia and abdominal pain.

Key Words: Leiomyoma, Symplastic, Myometrium

INTRODUCTION

Leiomyomas of the uterus are benign smooth muscle tumors that arise because of monoclonal proliferation of smooth muscle cells¹. Numerous histologic types of uterine leiomyomas have been described. Symplastic leiomyoma is a rare variant of leiomyoma which shows nuclear atypia and giant cells with minimal mitosis. We present this case to highlight its rarity, unique microscopic features and management.

CASE REPORT

A 45-year old female presented with abdominal pain and menorrhagia since 4 year 2 months. Her ultrasonography revealed multiple uterine fibroids involving anterior and lateral wall of uterus. A large exophytic fibroid was seen at posterior wall measuring 8 x 7 x 7 cm. A specimen of panhysterectomy was received for histopathological examination which revealed 2 intramural and 2 subserosal fibroids (Fig 1). Largest subserosal fibroid was 10.5 x 7 x 6.5 cm. Cut section was

grey- white, firm and revealed whorled appearance.

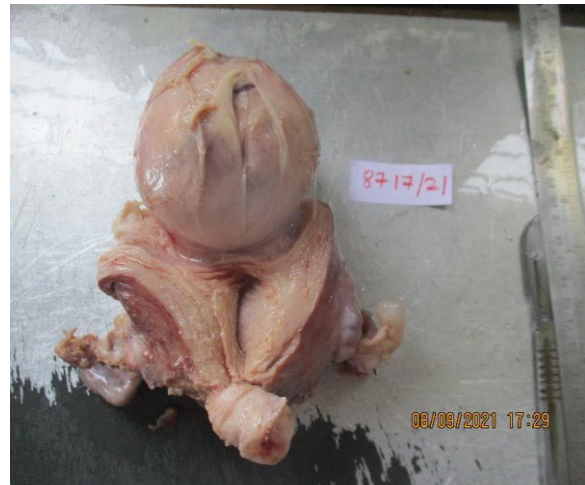

Fig. 1. Gross specimen showing a large Symplastic Leiomyoma arising from posterior wall of uterus.

Microscopy of largest fibroid revealed spindle shaped neoplastic cells arranged in fascicles, showing moderate to severe cytological atypia. Nuclei showed bizarre forms i.e. large hyperchromatic nuclei, coarse chromatin, multiple large nuclei forming giant cells were noted (Fig 2 & 3). However no mitotic figures were seen. Also, areas of necrosis were absent considering these features diagnosis for

largest fibroid was given as leiomyoma with bizarre nuclei. (Symplastic leiomyoma) Other three fibroids did not reveal nuclear atypia and were diagnosed as leiomyomas.

Sections from endometrium and bilateral ovaries did not reveal any significant pathology. Both fallopian tubes showed features of chronic non-specific salpingitis.

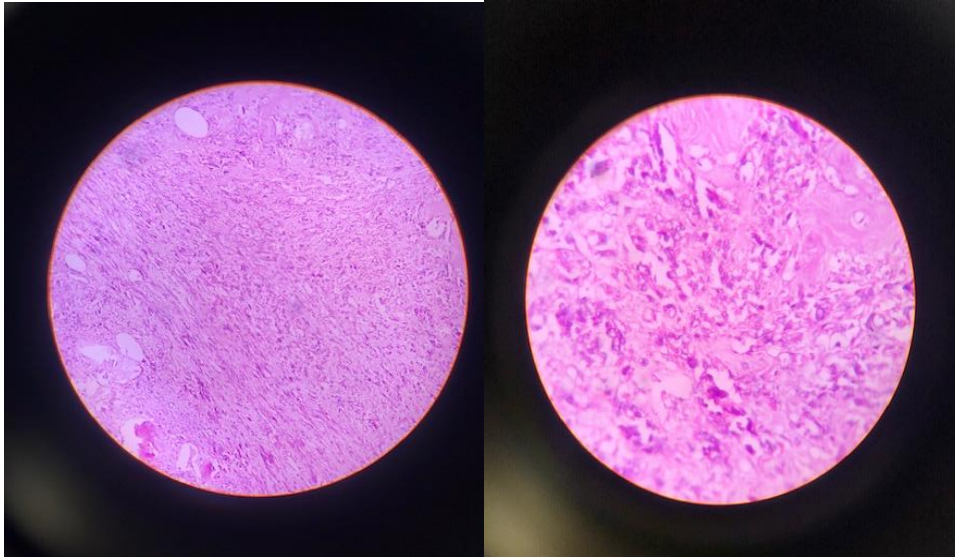


Fig.2 & 3: Spindle shaped neoplastic cells in fascicles (100x H&E), bizarre nuclear forms with giant cells (400X H&E).

DISCUSSION

The term atypical leiomyoma was first introduced by Taylor and Norris in 1966 to denote the presence of cytoplasmic atypia. Subsequent terminologies for this tumor were introduced as bizarre leiomyoma by Christopherson in 1971 and symplastic leiomyoma by Burns^{2,3}. Bell, Kempson and Hendrickson revised a classification scheme to distinguish between various categories of smooth muscle tumors of uterus^{4,5}. They included 3 criteria i.e. degree of cytological atypia, presence or absence of coagulative necrosis and mitotic index. Symplastic leiomyomas should be diagnosed when neoplastic cells show moderate to severe cytoplasmic atypia, no coagulative necrosis and <10 mitotic figures / 10 high power field.

Regularity of tumor margins, with absence of coagulative necrosis and low mitotic activity differentiates symplastic leiomyoma from leiomyosarcoma. Our case also revealed similar features. In spite of cytological atypia, clinical presentation of symplastic leiomyomas is same as leiomyoma without nuclear atypia⁶. Introduction of pelvic ultrasonography and

MRI help in making diagnosis. The incidence of malignant transformation of leiomyomas is 0.2 % and remains same for symplastic leiomyoma⁷.

Treatment protocol for these cases include gonadotropin releasing agonists, hysteroscopic removal or hysterectomy.

CONCLUSION

Symplastic leiomyoma is a rare tumor of uterine smooth muscles. Histopathological examination helps to give definitive diagnosis. Although histomorphological features of symplastic leiomyoma closely mimic leiomyosarcoma, absence of necrosis and low mitosis rules out malignancy.

Symplastic leiomyomas reveal very low risk of malignant transformation.

Acknowledgement: None

Conflict of Interest: None

Source of Funding: None

REFERENCES

1. Katke RD. Rare case presentation of symplastic leiomyoma in nulliparous female. Clin Cancer Investig J 2016;5:323-6.
2. Mamalingam M, Goldberg LJ. Atypical pilar leiomyoma: cutaneous counterpart of uterine symplastic leiomyoma?. Am J Dermatopathol 2001;23:299-303
3. Scully RE, Bonfiglio TA, Kurman RJ, et al. Histologic Typing of Female Genital Tract Tumors. World Health Organisation International Histologic Classification of Tumors. Second edition Berlin: Springer-Verlag; 1994.
4. Bell SW, Kempson RL, Hendrickson MR. Problematic uterine smooth muscle neoplasms: a clinicopathologic study of 213 cases. Am J Surg Pathol 1994;18:535-58.
5. Kondi-Pafiti A, Grapsa D, Kairi- Vassilatou E, et al. Mesenchymal tumors of the uterine corpus with heterologous and hematopoietic components: a study of ten cases and review of the literature. Eur J Gynaecol Oncol 2006; 27:73-7.
6. Chandralekha Biswas. Symplastoc leiomyoma of Uterus: A Rare Histologic Variant. JMSCR Vol 5, Issue 08, Page 27145-27147, August.
7. Rammesh-Rommani S, Mokni M, Stita W, Traibesi A, Hammisa S, Sriha B, et al. Uterine smooth muscle tumors: retrospective epidemiological and pathological study of 2760 cases. J Gynecol Obstet Biol Reprod (Paris). 2005;34:568-71.

How to cite this article: Patil N, Mane A, Upadhyay P et.al. Symplastic leiomyoma of uterus – a rare case with review of literature. *Int J Health Sci Res.* 2022; 12(3): 250-252. DOI: <https://doi.org/10.52403/ijhsr.20220335>
