

Bilateral Mooren's Ulcer Managed Conservatively - A Case Report

Dr Faiza Syed Jafar¹, Dr Alhaj Farhath Tasneem¹, Dr Meghana Kotesh¹

¹Department of Ophthalmology, Vydehi Institute of Medical Sciences and Research Centre, Bangalore, India

Corresponding Author: Dr Faiza Syed Jafar

DOI: <https://doi.org/10.52403/ijhsr.20221221>

ABSTRACT

Background: Mooren's ulcer is a rare type of peripheral ulcerative keratitis of unknown etiology.

Case: This is a case of a 76-year-old male who presented to the ophthalmology out-patient department with complaints of redness in both eyes. Visual acuity was 6/18 and 6/12 in the right and left eye respectively. Slit lamp examination of the both eyes revealed areas of peripheral corneal thinning in both eyes with clean floor, no slough and presence of limbitis. Anterior and posterior segments of both eyes were otherwise unremarkable. Investigations revealed no significant findings. A diagnosis of bilateral Mooren's ulcer was made and the patient was managed conservatively with oral and topical steroids as well as topical immunosuppressants. Patient's symptoms improved and signs showed now worsening and steroids were gradually tapered.

Conclusion: Mooren's ulcer is a diagnosis of exclusion. Once diagnosed, aggressive immunosuppressive medication should be started to retard progression and allow for better quality of life

Keywords: bilateral Mooren's ulcer, peripheral ulcerative keratitis, cyclosporine eye drops

INTRODUCTION

Mooren's ulcer is a rare type of peripheral ulcerative keratitis characterised by a painful marginal corneal ulcer with undermined borders, progressing first circumferentially then centrally.¹ Despite its characteristic clinical presentation, it remains a diagnosis of exclusion, hence a thorough medical history, physical examination and appropriate laboratory investigations must be performed to rule out underlying systemic conditions causing peripheral ulcerative keratitis.¹

CASE REPORT

A 76-year-old male who was a known case of systemic hypertension presented to the ophthalmology out-patient department with complaints of redness and burning sensation in both eyes (right eye more than left), insidious in onset and gradually progressive

and associated with watering and photophobia for the last six months. There was no history of ocular trauma or prior ocular surgeries.

On examination, visual acuity was 6/18p in the right eye, 6/12 in the left eye and both eyes improved to 6/6p with pinhole. Automated Refractometer readings were +2.00 (sph)/-1.00 (cyl) x 66 (OD) and +1.25(sph)/-0.50 (cyl) x 57 (OS). Slit lamp examination of the right eye revealed an area of peripheral corneal thinning extending into the deep stroma from seven o'clock to nine o'clock position with overhanging edges, stromal infiltration and no vascularisation. Floor of the ulcer was clean with no slough. Slit lamp examination of the left eye showed a smaller yet similar area of peripheral corneal thinning extending from eight o'clock to nine o'clock position with overhanging edges, clean floor

and no slough. (Fig. 1) In both eyes, limbal involvement was seen but no scleritis, and the anterior and posterior segments were otherwise unremarkable.

Schirmer's I test and Tear Breakup Time was normal in both eyes. Fluorescein staining of both eyes showed no corneal staining. Ocular motility and intraocular pressures (recorded with noncontact gonometer) were normal in both eyes. Autokeratometry and pachymetry were also done on both eyes. Pachymetry findings confirmed thinning of the cornea corresponding to the location of the ulcer, as described in Table 1. A battery of investigations was ordered, including complete blood count, urine routine and microscopy, HIV, HbsAg, HCV, ESR, VDRL, RA factor, X- ray chest and joints, ANCA, ANA with no significant findings.

Table 1: Autorefractometry readings in both eyes

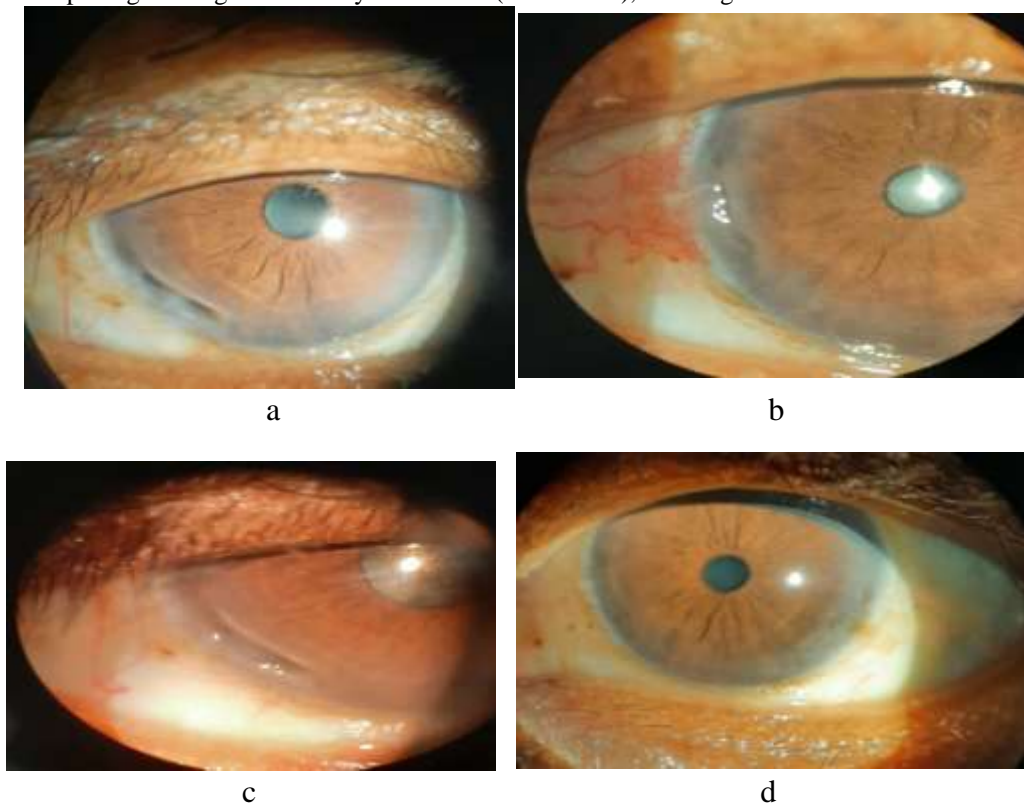
Autorefractometry	Right	Left
K1	44.00	44.00
K2	44.25	44.75
Axis	60	88

Table 2: Pachymetry readings in both eyes

Pachymetry	Right (in microns)	Left (in microns)
Center	559	560
Superior	555	569
Nasal	599	576
Inferior	520	547
Temporal	575	590

A diagnosis of bilateral Mooren's ulcer was then made and systemic immunosuppressive therapy was started with oral prednisolone at a dose of 1 mg / kg / day as well as topical immunosuppressive therapy with prednisolone acetate (1%) eye drops hourly and cyclosporine (0.1%) eye drops four time daily, topical cycloplegic with homatropine (2%) eye drops once daily and prophylactic topical antibiotic therapy with moxifloxacin (0.5%) eye drops in both eyes. Steroids were gradually tapered. The patient was followed up 1, 2 and 4 weeks following initiation of treatment and reported improvement of symptoms as well as no further worsening of clinical signs. (Fig. 1)

Figure 1: (a) and (b) are slit-lamp images of right and left eye at week 0 (first visit). Note the peripheral corneal ulcerations in both eyes showing overhanging edges, stromal infiltration, clean floor and no slough. (c) and (d) are slit-lamp images of right and left eye at week 4 (fourth visit), showing no further advancement of ulceration.



DISCUSSION

Mooren's ulcer is a rare disorder, typically seen in healthy, adult men with no evidence of systemic disease. However, Mooren's ulcer can occur at any age and in both sexes. Wood and Kaufman classified Mooren's ulcer into two clinical types. The benign or typical type tends to be unilateral or non-simultaneously bilateral with mild to moderate symptoms which are fairly responsive to treatment but with a guarded prognosis. Studies have shown that unilateral involvement is usually associated with a history of ocular trauma. The malignant or atypical type is more severe in presentation, seen bilaterally in 75% of cases, progressive despite treatment and associated with agonizing pain.²

A more recent classification was proposed by Watson, who divided Mooren's ulcer into three types based on the clinical presentation and anterior segment fluorescein angiographic findings.³ Unilateral Mooren's ulceration (UM) is a painful progressive corneal ulceration seen in elderly patients and is associated with non-perfusion of the superficial vascular plexus of the anterior segment. Bilateral aggressive Mooren's ulceration (BAM) affects young patients and presents with vascular leakage and new vessel formation, extending into the base of the ulcer. Bilateral indolent Mooren's ulceration (BIM), is typically seen in middle-aged patients presenting with bilateral progressive peripheral corneal guttering with little inflammatory response. The normal vascular architecture remains unchanged except an extension of new vessels into the ulcer.

Typically, the lesion begins as an infiltration of the peripheral anterior corneal stroma which gradually progresses circumferentially leaving no room between the cornea and the limbus. The central margin of the ulcer has an overhanging edge. The anterior stroma eventually melts resulting in a thinned residual stroma which ultimately undergoes vascularization by vessels originating from the cornea. The

ulcer initially progresses circumferentially then centrally and can proliferate if left untreated. There is associated limbitis and perhaps conjunctival hyperaemia, but no evidence of scleritis. In severe cases, anterior uveitis may be seen as well as cataract and secondary glaucoma.⁴

The exact aetiology of Mooren's ulcer is unknown. Historically, ocular trauma had been proposed as a potential inciter, though recent studies suggest an autoimmune response to altered corneal antigens. Some studies have also suggested a correlation with Hepatitis C infection.⁵

Mooren's ulcer must be differentiated from other types of peripheral ulcerative keratitis (PUK). Terrien's marginal degeneration is a similar type of peripheral corneal ulceration characterized by painless progressive non-inflammatory corneal thinning with a high degree of against-the-rule astigmatism and no limbal involvement, presenting a clear zone between the margin of the ulcer and the limbus. Pellucid corneal degeneration is another kind of noninflammatory, nonhereditary cause of corneal ectasia often confused for keratoconus, presenting with bilateral inferior peripheral corneal thinning with no limbitis and a clear zone between the ulcer and the limbus. Corneal dellen may also sometimes show a similar presentation to Mooren's ulcer, but they are typically peripheral excavations in the cornea which occur secondary to tear film abnormalities caused by limbal elevations. Systemic conditions like rheumatoid arthritis also present with peripheral ulcerative keratitis, but it is almost always associated with scleritis.² Having considered all possible differentials, the diagnosis of Bilateral Indolent Mooren's ulcer was made in the presenting case.

The treatment of Mooren's ulcer involves a stepwise approach. Medical management is primarily with systemic and topical steroids and immunosuppressants. In refractory cases, surgical treatment is considered in the form of conjunctival resection and amniotic membrane transplantation Lamellar keratectomy and lamellar scleral autograft

have also been described, though their efficacy in severe cases is yet to be determined.⁶

The initial course of steroid therapy is topical prednisolone (1%) eye drops administered hourly in association with topical cycloplegics and prophylactic antibiotics. Several studies have shown the efficacy of adding topical cyclosporine (0.05%) eye drops as well. If topical steroids alone are ineffective, systemic steroids are recommended in the form of oral prednisolone at a daily dose of 60-100 mg. Studies have also shown the benefit of systemic immunosuppressants in severe cases, namely cyclophosphamide (2 mg/kg body weight/day), methotrexate (7.5-5 mg once a week) and azathioprine (2 mg/kg body weight/day). If the ulcer is deep, a therapeutic soft contact lens or patching of the eye may be helpful.⁶

If the ulcer progresses in spite of steroid regimen, conjunctival resection should be performed. This involves excision of the conjunctiva adjacent to the ulcer or 360° circumferential limbal conjunctival peritomy in severe cases, the rationale being that the conjunctiva adjacent to the ulcer contains inflammatory cells which may be producing cytokines against the cornea which may worsen the inflammation.⁶

Small corneal perforations or impending perforations may be treated with tissue adhesive substances such as isobutyl cyanoacrylate and the placement of a soft contact lens. If the perforation is too large for the tissue adhesive to close the leak, a patch graft may be necessary.⁶

In this case, the patient was started on systemic and topical steroids (prednisolone acetate 1% eye drops hourly) as well as topical immunosuppressants (cyclosporine 0.1% eye drops 4 times daily) and topical cycloplegics and antibiotic therapy. He was followed up regularly 1, 2 and 4 weeks after initiation of treatment and was found to have a significant improvement in his symptoms as well as no further progression of the ulcer. As such, the patient was

managed conservatively and advised regular and timely follow-up.

CONCLUSION

Although the clinical appearance is characteristic, Mooren's ulcer remains a diagnosis of exclusion and all causes of peripheral ulcerative keratitis must be ruled out. Advancements in treatment modalities of Mooren's ulcer ensure a much better prognosis in these patients and in many cases, reduces the risk of visual loss. Early diagnosis and judicious treatment is crucial in ensuring this, as is regular monitoring and follow-up of the patients. Not all cases will require surgical intervention, but if medical management alone fails to control the progression of the ulcer, then further management must be initiated promptly. Proactive management can help avoid calamitous outcomes.

Declaration by Authors

Ethical Approval: Not Applicable

Acknowledgement: None

Source of Funding: None

Conflict of Interest: The authors declare no conflict of interest.

REFERENCES

1. Lewallen S, Courtright P. Problems with current concepts of the epidemiology of Mooren's corneal ulcer. *Ann Ophthalmol* 1990;22: 52-5.
2. Chow CY, Foster CS. Mooren's ulcer. *Int Ophthalmol Clin* 1996; 36:1-13.
3. Watson PG. *Eye*. 1997; (Pt 3):349-56.
4. Wood TO, Kaufman HE. Mooren's ulcer. *Am J Ophthalmol* 1971; 71: 417-422.
5. Wilson SE, Lee WM, Murakami C, Weng J, Moninger GA. Mooren-type hepatitis C virus-associated corneal ulceration. *Ophthalmology*. 1994 Apr 1;101(4):736-45.
6. Sangwan VS, Zafirakis P, Foster CS. Mooren's ulcer: Current concepts in management. *Indian J Ophthalmol* 1997;45:7-7

How to cite this article: Faiza Syed Jafar, Alhaj Farhath Tasneem, Meghana Kotesh. Bilateral Mooren's ulcer managed conservatively - a case report. *Int J Health Sci Res*. 2022; 12(12):128-131. DOI: <https://doi.org/10.52403/ijhsr.20221221>
