

Management of Severe Diastasis Recti Abdominis by Abdominal Strengthening Exercise in Women after Postpartum Period: A Case Study

Vinal Charpot¹

¹Lecturer, Physiotherapist, Government Physiotherapy College and Government Spine Institute, Civil Hospital, Ahmadabad.

ABSTRACT

Background: Abnormal gap between two rectus abdominal muscle at the level of umbilicus, above or below umbilicus called diastasis recti. It reduces the integrity and functional strength of the abdominal wall and can aggravate low back pain and later on pelvic instability. If the exercises are given to avoid the complications and reduce abnormal separation in early postpartum phase it will be most effective way to correct DRAM. But if these abdominal exercises have not been given on early phase then there will be no improvement in severe DRAM.

Materials and Methods: In this case study it was design to find out effect of abdominal strengthening exercise in women after postpartum period. 39 year old lady was diagnosed with severe diastasis recti after one year of her last delivery. In this study finger palpation method was used to examine DRAM then abdominal strengthening exercises were given for 8 weeks.

Result: By finger palpation method it was found that this lady had severe DRAM at the level of umbilicus, above and below gap between two rectus abdominis muscle was more than 4 fingers. After completion of the exercise protocol it was found that there was no improvement in DRAM after 8 weeks but there is significant reduction in low back pain according to NPRS.

Conclusion: The result of this case study shows that abdominal strengthening exercises are not effective in reducing severe diastasis recti in after post partum period. But there was definite reduction in low back pain. So it is not support the prescription of an abdominal strengthening exercise in severe diastasis recti in very late post partum period of time.

Key Words: Diastasis Recti Abdominis, Abdominal Strengthening Exercises, Low Back Pain, NPRS

INTRODUCTION

Pregnancy is the most important duration of women's life. During pregnancy the uterus slowly grows out of the pelvic region during the fourth month of the pregnancy and continues to take over ample portions of the abdomen until delivery.¹

When coupling the prolonged stress of progressive weight gain with an increase in hormone production associated with pregnancy, it should not come as a surprise that diastasis rectus is found so frequently during and after pregnancy.²

Rectus abdominis diastasis is an excessive gap between the bellies of rectus

abdominis at the level of the umbilicus. It normally appears in the pregnancy at the second stage of labor can extend the whole length of linea alba.³

The most common complication faced by postnatal women is diastasis of rectus abdominal muscle.⁴

Any separation larger than 2 cm or 2 finger width is considered significant. It can occur above, below and at the level of umbilicus.⁵

The causative factors for diastasis recti during pregnancy are increased level of relaxing, progesterone and estrogen

hormones that causes soften of connective tissues and weakening of the linea alba.^{6,7}

Coupled with hormonal softening of linea Alba thus the continuously increasing stretch placed on the abdominal wall by growing fetus. As result, amount of tension on an already weakened structure produces predisposition to separation and results in diastasis recti.^{8,9}

For the treatment of diastasis recti, there is a surgical option, in which the correction is made by means of abdominoplasty or laparoscopy.¹⁰

Conservative treatment could be an alternative to surgery, with there being no consensus as to which is the best option, further studies being necessary to assess different treatments for diastasis recti.

There is no guideline for the treatment of diastasis recti,¹¹

But studies suggest that transverse abdominis muscle training could help restore their function in lumbopelvic stability, during load transfer, and reduce the gap between the rectus muscles.^{12,13}

The treatment aimed to reducing diastasis recti in the postpartum period reported in the scientific literature, are scare. There are studies to confirm the positive influence of exercise on reducing the inter recti distance but it has not been assessed which abdominal exercise is the most effective.^{14,15}

Diastasis recti can be corrected conservatively and surgically. In extreme cases, diastasis recti are corrected during the cosmetic surgery procedure known as an abdominoplasty commonly it is reoffered to as the 'tummy tuck'.¹⁶

AIM AND OBJECTIVES:

To find out effect of abdominal strengthening exercises in correction of severe diastasis recti in women after postpartum period

OBJECTIVES:

1. Abdominal strengthening exercises are effective in correction of diastasis recti.

2. Abdominal exercises are not effective in correction of diastasis recti.

3. To find out effect of abdominal exercises in reduction of low back pain

HISTORY

The subject for this study was 38 year old lady professionally she was nurse. She had history of two pregnancy .both were caesarean section

First caesarean section was done in 7/7/2013. Then second caesarean section was done in 9/9/2016. Before first pregnancy she had history of two abortions and then again before second pregnancy she had history of two abortions. After second C.S she had no complain regarding abdominal muscle till one year. In November 2017 gradually she felt that she became over weighted and her abdominal muscles was getting floppy .she had also a complained of mild backache. She was giving history like since last 4 to 5 months I m feeling that my abdominal muscle are getting separate while I m doing any physical activity like sitting from bed, coughing, lifting something from ground. As she was nurse she had some knowledge that this is something abnormal which is going to increasing day by day. One day she went to her GP. He referred her to physiotherapy department for weight control and fitness purpose. In physiotherapy department she was diagnosed with severe diastasis recti condition by physiotherapist. Then she was regularly come to physiotherapy department for treatment proposes.

Height- 150 cm

Weight – 79 kg

Present medical history: significant of bronchial asthma since last 25 years

2 attacks of asthma per year

Taking bronchodilators (sos)

Previous surgical history: caesarean section in 2013 and 2016

Family and social history: due to complain of abdominal muscle weakness posture

became lordotic. She felt so shy due to bad posture and gait.

ASSESSMENT:

The whole procedure to examine diastasis recti was explained to the subject and consent form was taken. Diastasis recti palpation by finger palpation method was performed to check for abnormal gap between two rectus abdominis muscle and their inter recti distance. Figure 1

ABNORMAL SAPARATION OF TWO RECTUS ABDOMINIS MUSCLE

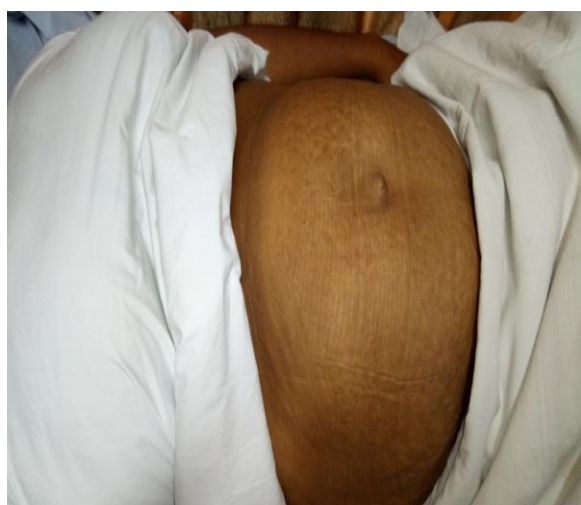


FIGURE 1

FINGER PALPATION METHOD (To check gap between two rectus abdominis muscle)

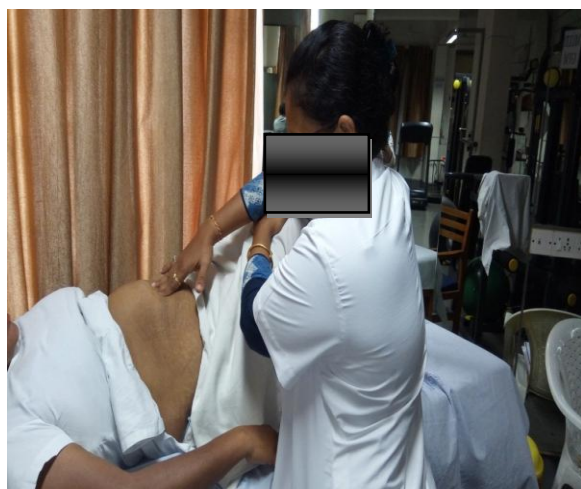

FIGURE 2

In finger palpation method subject was in crook lying position with pillow

beneath head and feet resting on plinth. The subject was instructed to lift her head and shoulder off the plinth, reaching towards her knees with outstretched arm until the spine of scapulae cleared the surface. Figure 2

Physiotherapist palpates the finger horizontally on linea Alba in such a way that, finger width could fit the distance between the internal borders of two rectus abdominis muscles.

The number of fingers that can be placed between muscle bellies has been documented. Using center of umbilicus as reference, measurement were taken in, one being 4.5 cm above umbilicus and 4.5 cm below umbilicus.

Three trials were taken for each assessment and then mean was recorded. After completion of procedure participants were asked to lower down the head and return to normal position¹⁷

Subject was allowed to take rest at any time if she feels fatigue.

According to table 1 and table 2 , it has been found that this lady had severe diastasis recti

TABLE 1: CLASSIFICATION OF DIASTASIS RECTI ABDOMINIS

Rath classification		
Level	Age < 45	Age > 45
Above umbilicus	10 mm	15 mm
At umbilicus	27 mm	27 mm
Below umbilicus	9 mm	14 mm

TABLE 2: DIASTASIS RECTI CLASSIFY ACCORDING TO RANNEY .B.¹⁸

SEVEREITY OF DIASTASIS RECTI	
<3 CM	MILD
3-5 CM	MODERATE
> 5 CM	SEVEREE

FOR LOW BACK PAIN:

NPRS: This scale has been used in this study to find out severity of back pain.

According to NPRS this lady had low back pain score was 5.

PROCEDURE:

Exercise protocol:

Abdominal exercises

Type of exercises- static abdominal exercise, head lift, head lift with posterior

pelvic tilt exercise, pelvic clock exercise, planks

Frequency- 5 times /week for 8 weeks

Duration- 30 minutes/day

STATIC ABDOMONAL EXERCISE:

Subject was in crook lying position and arm along the side. She was asked to draw in abdominal by pressing lumbar region down on the plinth for 10 sec. in this position the subject was told to place fingers on her abdominal wall at waist line. Then she was asked to contract lower abdominal wall by gently drawing inwards the area beneath. She has to maintain this contraction for 10 seconds along with normal breathing pattern during exercise¹⁹ Repetition 5 to 7 times per day.

HEAD LIFT AND HEAD LIFT WITH PELVIC TILT:

Subject was asked to take crook lying position with both arms crossed over the abdomen for support rectus abdominis muscle. Then instruction was given to her that exhale and lift her head and scapula off the floor or point just before budge appeared ,and asked to contract abdominal muscle and press lumbar region down on plinth .then slowly lowered her head and relaxed.²⁰ Repetition 5 to 7 times per day.

PELVIC CLOCK EXERCISE:

Subject was asked to take crook lying position with arm besides. She was instructed that imaging that face of clock on their abdominal area. The umbilicus was 12 o clocks and pubic symphysis was 6 o clock. Then she had to start doing gentle weight shifting towards umbilicus then towards left hip as like 3 o clock, towards right hip as like 9 o clock. Same like that she was instructed to do this exercise 5 to 7 times.^{19, 20}

PLANK EXERCISE:

Subject was in front supported position resting on forearm with her shoulder directed over elbow, back and bottom in straight line position. She was

instructed to draw in lower abdomen, straighten her legs out behind them and lift up her hip to form straight line from her shoulder to ankle.

Try to balance on her forearm and toes with her abdomen and back working together to keep their body straight. Maintain this position for 10 second and then lowers down and return to relaxed position.²⁰

DATA ANALYSIS:

The result was analyzed on the basis of pre and post intervention by using finger palpation method.

The result of finger palpation method shown diastasis rectus gap at above, at and below umbilicus pre intervention was 4.3 cm, 4.9 and 5.1 cm respectively. And post intervention diastasis rectus gap was almost same as pre intervention. Strangely after following the 8 weeks abdominal strengthening exercise protocol there was not found any significant improvement in diastasis recti in this study. There was significant improvement shown in low back pain that was pre intervention NPRS scale was 5 and post intervention NPRS score was 2. It showed reduced low back pain after abdominal strengthening exercise.

FINGER PALPATION METHOD:

Table 3: pre and post intervention values by finger palpation method after 8 weeks treatment duration

S.N	LEVEL	PRE	POST	TYPE
1	ABOVE UMBILICUS	4.3 cm	4.3 cm	MODERATE
2	AT THE UMBILICUS	4.9 cm	4.9 cm	SEVERE
3	BELOW UMBILICUS	5.1 cm	5.1 cm	SEVERE

NPRS SCALE

Table 4: pre and post NPRS score for low back pain after 8 weeks treatment duration

S.N	PRE INTERVANTION	POST INTERVANTION
1	5	2

DISCUSSION

This study found that diastasis recti were not significantly reduced after giving 8 weeks abdominal exercise. Table 3

In this case study finger palpation method was used to examine diastasis recti .it was most often to measure the inter rectus distance.²¹

Recently Mota et al shows that finger palpation has sufficient reliability to use in clinical practice. Another study done by Cynthiya M. Chairello, stated that digital nylon caliper is reliable and validate tool for measuring inter recti distance.²²

In this study it has been found that there was significant reduction in back pain according to NPRS SCALE. Table 4

Many studies have been proven that there was reduction of waistline, despite presenting other symptoms related to the diastasis recti, such as lower back pain or urinary incontinence.²²

According to Spanish national institute of statistics published in 2015, in which the percentage of natural births much higher than caesarean section .this raises the issue of whether the caesarean section is a risk factor for diastasis recti. This coincides with Candido et al. (2005), who indicated that the cesarean section led to a greater risk to suffer an increasing in the inter rectus distance during the post partum period.²³

In this study the exercise program had been not found significantly effective starting from first week of treatment and there was no change into inter rectus distance at weeks 4 and weeks 8. On other word the abdominal exercise was not effective in severe diastasis recti abdominis.²⁴

Regarding the number of children, no relationship was found with diastasis recti, although having several births is considered a risk factor for wider diastase recti.

According to Leon SC et al many women participating in study had diastase recti for years, and this fact confirms that the diastasis recti does not resolve on its own after 8 weeks from delivery.^{25,26}

In early postpartum period DRAM had been found significantly improved but in late period like after one year of last delivery, then abdominal exercise is not

effective in severe diastasis recti abdominis²⁶

Limitation

The assessment method is finger palpation method, which has high validity but there are other more precise methods, such as digital palpation with vernier caliper and ultrasound.

Further experimental study with control group is needed it is also another limitation of this case study. However the fact that some women had DRAM for years could be considered control, because if no treatment was received, the diastasis recti would not spontaneously resolve, except the first weeks after giving birth.²⁵

CONCLUSION

The abdominal exercise program was not effective in severe diastasis recti in women after postpartum period. There was significant improvement in reduction of back pain.

The results were obtained starting from first week of treatment to 8th weeks, and they were not shown any improvement in DRAM until the 8th weeks.

Acknowledgement: None

Conflict of Interest: None

Source of Funding: None

Declaration of Patient Consent

Appropriate patient consent was taken prior to publication in the journal.

REFERENCES

1. Biossonnault, J.S And Blackhawk, M.J. Incidence Of Diastasis Recti Abdominis During The Childbearing Year.Phys Thera. 1988; 68(7); 1082- 1086.
2. Hannoford, And Tozer, J. An Investigation Of Incidence, Degree And Possible Predisposing Factors Of Rectus Diastasis In The Immediate Post Partum Period .J Nal Onset Gynecology Special Group Of The Australian Physiotherapy Association.1985;4: 29-32

3. Noble E. Essential Exercises For The Child Bearing Year. 4 Cape Cod: New Live Images; 1.
4. Mental J, Barton S .Physiotherapy In Obstetrics And Gynecology. 2 Nd Editions 2004.
5. Biossonnault S J Blaschak Jm. Incidence Of Diastasis Recti Abdominis During The Child Bearing Year. Journal Of American Physical Therapy Association .1998; 68:1082-1086.
6. Chearello Mc ,Flzone A L, Mc Caslin E K ,Patel M, Ulerly K .The Effect Of An Exercise Program On Diastasis Recti Abdominis In Pregnant Women. Journal Of Women's Health Physical Therapy .2015: 29 (1): 11-16
7. Parkee Am ,Lynn Millar A , Dugan S .Diastasis Rectus Abdominis And Lumbar Pelvic Pain And Dysfunction Are They Related .Journal Of Women's Health Physical Therapy .2008-9:32-(1)
8. Pascoal A. .G, Dionisio S, Cordeir F, Mota P. Inter Recti Distance In Postpartum Women Can Be Reduced By Isometric Contraction Of Abdominal Muscle; A Preliminary Case Control Study. Published By Elsevier. Physiotherapy:100(2014)344-348
9. Mishra A, Maria L, Umar M, Kanwal R. Prevalence Of Diastasis Recti Among Pregnant Female Presenting At Holy Family Hospital Rawalpindi. International Journal Of Rehabilitation Science.03 (1):26-31.
10. Akram J, Matzen Sh. Rectus Abdominis Diastasis. J Plast Surg Hand Surg. 2014;48: 163-9
11. Litos K, Progressive Therapeutic Exercise Program For Successful Treatment Of A Postpartum Women With A Severe Diastasis Recti Abdominis .J Women's Health Physiother.2014;38(2):58-73
12. Chiarelloc., Falzone La,Mscaslin K,Patel Mn ,Ullery Kr .Effects Of An Exercise Program On Diastasis Recti Abdominis In Pregnant Women .J Women S Health Phys Ther.2005; 29(1):11-6
13. Lee D, Hodges Pw. Behavior Of The Linea Alba During A Curl Up Task In Diastasis Rectus Abdominis: An Observational Study. J Orthop Sports Phys Ther.2016;46(7):580-9
14. Acharry N, Krishnan Kutty R. Abdominal Exercise With Bracing. A Therapeutic Efficacy In Reducing Diastasis Recti Among Postnatal Females. International Journal Of Physiotherapy And Research ,2015;3(2):999-1005
15. Khandale Sm Hande D. Effects Of Abdominal Exercise On Reduction Of Diastasis Recti In Postnatal Women .Int J Health Sci Res.2016 ;6(6):182-91
16. Boot Camp And Military Fitness Institute: Diastasis Recti: An Overview; 21 Sep.2015
17. Kisner C, Lynn Allen Colby .Therapeutic Exercise, Women's Health: Obstetrics And Pelvic Floor. 5 Th Editions 2007; 797-824.
18. Ranney B And Rath. Diastasis Recti And Umbilical Hernia Causes, Recognition And Repair.
19. Kosery M.El S, Abd El -Aziz A, Abdominal Muscle Exercise Program And Electrical Stimulation In Postnatal Diastasis Recti .Faculty Of Physiotherapy, Cairo University.12(2);2007 Jul.
20. Youssef M A ,Sabbour Ad, Kamel M R.Muscle Activity In Upper And Lower Portions Of Rectus Abdominis During Abdominal Exercises In Postnatal Women Having Diastasis Recti .Bull.Fac.Ph Cairo University.8(1)Jan .2003
21. Albrecht M ,Eberhardt L, Horn L, Donnelly Y C .Lowe D. Diastasis Of Rectus Abdominis : A Survey Of Women S Health Specialties For Current Physical Therapy Clinical; Practice For Postpartum Women's, Journal Of Women' S Health And Physical Therapy .2012;36;Pt 3 ,Pp131-141.
22. Cynthia M.Chiarello , J . Adrienne Mcauley .Concurrent Validity Of Caliper And Ultrasound Imaging To Measure Interrecti Distance.Journal Of Orthopedic And Sports Physical Therapy.43(7); 2013,495-503
23. Richardson Ca , Snijders Cj ,Hides Ja , Damen L,Puas Ms ,Storm J .The Relation Between The Transverses Abdominis Muscles, Sacroiliac Joint Mechanics ,And

- Low Back Pain .Spine.2002;27 (4);399-405
24. Spitznagle Tm,Leong Fc ,Van Diellen Lr .Prevalence Of Disatasis Recti Abdominis In Urogynecological Patient Population .Into Urogynecol J Pelvic Floor Dysfunction.2007;18:93)321-8
25. Candido G.Lo T ,Janssen P.Risk Factor For Diastasis Of The Recti Abdominis .J Assoc Chart Physiotherapy Women Health. 2005:97
26. Mota P, Pascoal Ag,Sancho F , K .Test – Retest And Interarater Reliability Of 2 – Dimension Ultrasound Measurements Of Distance Between Rectus Abdominis In Women .J Orthop Sports Phys There. 2012;42(11):940-6
27. Leon Sc, De La Hoz Gca Et Al. Effects Of An Exercise Program On Diastasis Recti In Women. Int J Health Sci Res.2019: 9(10):90-99
- How to cite this article: Charpot V. Management of severe diastasis recti abdominis by abdominal strengthening exercise in women after postpartum period: a case study. *Int J Health Sci Res.* 2021; 11(6): 367-373. DOI: <https://doi.org/10.52403/ijhsr.20210655>
