

Epidermoid Cyst of Vocal Cord - A Rare Case Report

Anu Agarwal¹, Sujata Raychaudhuri², Reetika Menia¹, Akanksha Bajaj¹

¹Tutor, ²Associate Professor, Dept. of Pathology, ESIC Medical College and Hospital, Faridabad, Haryana.

Corresponding Author: Anu Agarwal

ABSTRACT

Vocal cord swellings are a commonly encountered clinical entity. However, Vocal cord cysts are rare. Also, these are mostly retention cysts caused by obstruction of a glandular duct. We hereby report a case of vocal cord cyst which was diagnosed as retention cyst clinically. However, on excision followed by histopathological examination a diagnosis of epidermoid cyst was made. This case is reported due to the finding of a very rare entity and also to re-emphasize the importance of histopathology as gold standard in examination of lesions.

Keywords: Vocal cord cyst, epidermoid cyst, Vocal cord swelling

INTRODUCTION

Cysts of the vocal cord are rare. These constitute approximately 5% of all benign laryngeal lesions ^[1]. Generally the intracordal cysts described in the literature consist of retention or mucus cysts, most probably caused by obstruction of a glandular duct. These retention cysts are considered the most frequent type of vocal cord cysts. These may occur spontaneously during upper respiratory tract infection or with vocal abuse. The retention cyst tends to be translucent and can be easily visualised on indirect laryngoscopy. These are usually lined by cuboidal or columnar epithelium ^[2]. Epidermoid cysts being less evident on indirect laryngoscopy have been infrequently reported in the literature ^[3]. These are derived from the congenital cell rests in the subepithelium of fourth and fifth branchial arches or from burying of epithelium in the healing injured mucosa. They contain accumulated keratin giving a white colour, and are lined by stratified squamous epithelium ^[2]. Till date there are only few case reports/series on vocal cord

cysts. We hereby, report a case of epidermoid cyst of vocal cord.

CASE PRESENTATION

A 32 year female presented with hoarseness of voice for past 6 months. There were no symptoms suggestive of any thyroid disorder. On examination, no thyroid swelling was present. On Indirect laryngoscopy, vocal cords appeared normal, except for mild inflammation in left vocal cord. Patient was advised anti-inflammatory medications. On follow up, there was no improvement of voice. This led the clinicians to undergo fiberoptic endoscopy of larynx. The findings were suggestive of left intracordal cyst measuring 0.8x0.5cm. Patient was operated and specimen sent for histopathology. On histopathological examination, sections showed a cyst lined by stratified squamous epithelium (figure 1, figure 2), filled completely with keratinous material (figure 3). No adnexal structures were identified and a diagnosis of 'Epidermoid Cyst of True vocal cord' was given.

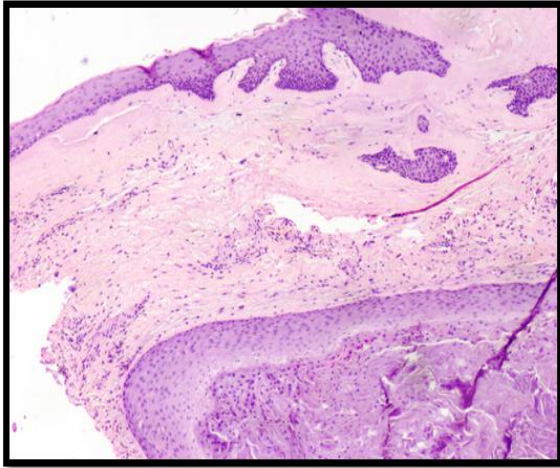


Figure 1 (10X): H and E stained section from vocal cord shows surface lined by stratified squamous epithelium with underlying stroma containing an epidermoid cyst.

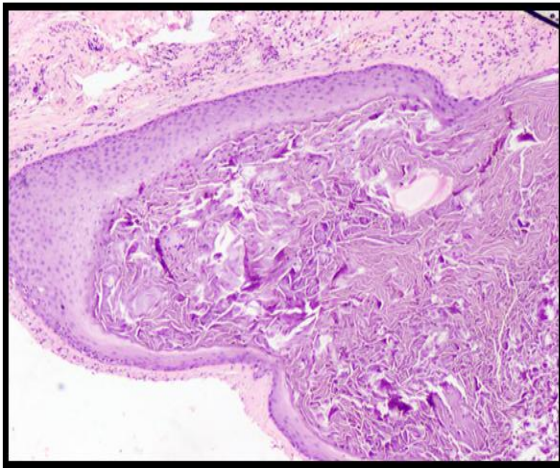


Figure 2 (10x): H and E stained section showing cyst lined by stratified squamous epithelium and filled with keratin.

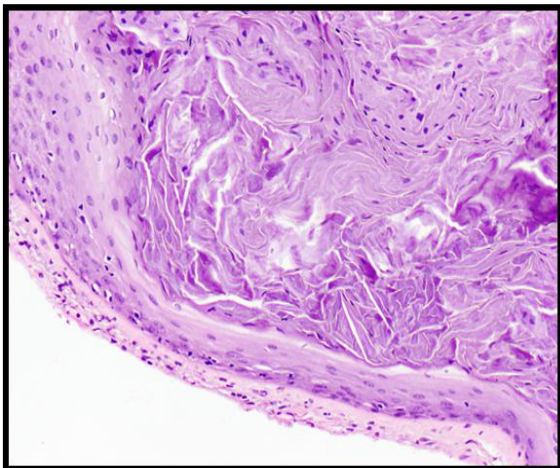


Figure 3 (40X): H and E stained section showing keratinous cyst. The keratin shows interspersed parakeratotic cells.

DISCUSSION

Laryngeal cysts were first reported by Verneuil in 1852^[4]. Occurring over a wide age range, they are reported most

frequently in the epiglottis and true cord. The majority of the epidermoid cysts of the vocal cords show female preponderance^[5]. There is a high incidence of left vocal cord involvement than right vocal cord. Generally the cyst is located in the middle third of cord just beneath the free border of the vocal fold.^[6]

Epidermoid cysts of the vocal cord have been classified into two. True epidermoid cysts that are lined by normal malpighian epithelium and filled with keratinous material. The other one is Epidermoid Inclusion cyst, consisting of a solid malpighian epidermoid formation without keratin. Pertaining to pathogenesis, there are two theories. First one presumes that the development of epidermoid cyst inside vocal cord results from microtraumatism from vocal abuse, inflammation or direct trauma. The squamous cells from outer vocal cords enter the breached area and start growing into a cyst, similar to that seen in epithelial inclusion cyst in skin.^[7]

The second hypothesis suggests that there are congenital rests of squamous epithelium that may grow into epidermoid cyst. This hypothesis is supported by the fact that these cysts are congenital in few cases^{[8][9]}.

Recently, Shevero et al has proposed a new histological classification: A: cysts lined by columnar epithelium with mucous content; B: lined by columnar epithelium with cilia; C: lined by squamous epithelium without keratinization; D: lined by squamous epithelium with keratinisation^[10].

Patients usually present with hoarseness, increased effort of vocalization, pain and soreness with excessive voice use. On indirect laryngoscopy, a cyst may appear as fullness in the vocal fold. In a dysphonic patient, an intracordal cyst should be suspected when no obvious lesion is found on indirect laryngoscopy. Treatment requires a multidisciplinary approach. Medical management aims at elimination of irritants and inflammatory conditions such as allergy and reflux laryngitis and

maintaining good vocal hygiene. Speech therapy is needed for reduction of voice abuse and improvement of vocal efficiency. Vocal cord cysts typically do not respond to only conservative management unlike nodules and polyps. Surgical removal is the mainstay of treatment. Complete removal of the cyst with maximum preservation of superficial lamina propria enhances the vocal outcome. In addition, the deep layers of the lamina propria harbor fibroblasts that produce extracellular proteins. Efforts are made to avoid dissection in this layer so as to prevent scarring along the vocal ligament [2].

CONCLUSION

Epidermoid inclusion cysts are not rare but are infrequently reported in literature. During history taking, attention must be given to long standing stable dysphonia. Histopathological study of these cysts helps in understanding the pathogenesis. Surgical removal with microdissection is the treatment of choice combined with voice re-education. Total excision of the cyst must be performed to avoid the chances of recurrence.

Acknowledgement: None

Conflict of Interest: None

Source of Funding: None

Declaration of Patient Consent

Appropriate patient consent was taken prior to publication in the journal.

REFERENCES

1. Hollinger PH, Johnson KC: benign tumours of the Larynx. *An n Otol* 1951; 60:496-509.
2. Nirurkar NK and Shukla SC. Subepithelial Vocal Fold Cyst: A Pearl on a String?. 2012; 2.
3. Monday LA, Cornut G, Bouchayer M, Roch JB. Epidermoid cysts of the vocal cords. *Ann Otol Rhinol Laryngol*. 1983 Mar-Apr;92(2 Pt 1):124-7.
4. Myerson MC: Cysts of the larynx. *Arch Otolaryngol* 1933; 18:281-290
5. Boucha Yer M. Cornut G. Witzing E. Lovie R, Roch JB. Bastian RW. Epidermoid Cysts, Sulci and Mucosal Bridges of the true vocal cords. *Laryngoscope* 1985 ; 95 : 1087.
6. Rashid Patigaroo, Ab & Nazir A.Khan, Murtaza. (2001). Epidermoid Cyst of the Vocal Cord: An Undiag. Clinical Entity. *JK Science : Journal of Medical Education & Research*.
7. Ash JE, Raum M. An atlas of otolaryngologic pathology. 4th ed. Washington: American Registry of Pathology, 1956.
8. Bouchayer M, Cornut G. Cystes et pseudolystes de la corde vocale (a propos de 32 cas). *Compte-rendu des Seances du congres francais d'O.R.L.: Arnette'Paris*, 1974
9. Cornut G, Bouchayer M. Indications phoniatriques etrésultats fonctionnels de la microchirurgie laryng6e. *Bulletind'audiophonologie* 1977; 7:5-52.
10. Shvero J, Koren R, Hadar T, Yaniv E, Sandbank J, Feinmesser R et al. Clinicopathologic study and classification of vocal cord cysts. *Pathol Res Pract*. 2000; 196(2):95-8.

How to cite this article: Agarwal A, Raychaudhuri S, Menia R et.al. Epidermoid cyst of vocal cord- a rare case report. *Int J Health Sci Res*. 2021; 11(6): 309-311. DOI: <https://doi.org/10.52403/ijhsr.20210645>
