

Routine Histopathological Examination of Appendix: The Practice That Cannot Be Ignored

Maryam Adam Mohamed Ali¹, Sameer Ahmed A.H Ansari², Khalid Al Sindi³,
Suha Hejres⁴

¹Senior House Officer, Department of Pathology, King Hamad University Hospital, Bahrain

²Senior Registrar, Department of Pathology, King Hamad University Hospital, Bahrain.

³Head of Histopathology, Department of Pathology, King Hamad University Hospital, Bahrain

⁴Head of Department, Department of Pathology, King Hamad University Hospital, Bahrain

Corresponding Author: Sameer Ahmed A.H Ansari

ABSTRACT

Background: Acute appendicitis is a global disease that is usually caused by luminal obstruction with fecoliths.

Aim: The aim of this study is to estimate the incidence of unusual findings in appendectomy specimens that can affect patient's morbidity and mortality.

Methods and Material: This is a retrospective study of 340 appendectomies that were performed from January 2018 to December 2019 at King Hamad University Hospital (KHUH). Histopathological reports were reviewed and final diagnosis, age and gender were recorded.

Results: Of the 340 appendectomy specimens, acute appendicitis was the most prevalent finding 62.64% (and showed significant correlation with both genders P value <0.001). Unusual findings were seen in (8.49%) cases and the commonest unexpected finding was fibrous obliteration (4.11%) followed by carcinoid (1.76%).

Conclusions: this study revealed that although majority of appendectomy cases fall in the spectrum of inflammatory cases with low incidence of unusual findings, it is atmost importance to perform the histopathological examination as it still change the course of treatment and affect the overall prognosis of the patients.

Key-words: Acute appendicitis, Acute abdomen, Appendix, Histopathology, Unusual findings

INTRODUCTION

Acute appendicitis is a common cause of acute abdomen. ⁽¹⁾ The lifetime risk for it is 7% and it is mostly seen during early adulthood, ^(1,2) caused by luminal blockage, usually by fecoliths or lymphoid hyperplasia. ⁽³⁾ However, other uncommon causes like parasites and tumors are sometimes seen. ^(2,3)

Following a literature review, few studies suggested that routine histopathological examination of appendectomy specimens should be limited to those with abnormal macroscopic findings. ⁽⁴⁾ However, majority of the studies

recommended to continue histopathological examination of appendectomy specimens as unusual causes can be missed. ^(5,6) Hence, changing the management. ⁽⁷⁾

This is the first study in Kingdom of Bahrain that aims to estimate the prevalence of unusual findings of appendectomy specimens and to evaluate the overall pattern of neoplastic and non-neoplastic lesions.

SUBJECTS AND METHODS

This retrospective study was conducted at KHUH from January 2018 to December 2019. Histopathological reports

of all appendectomy specimens of 340 patients including their age and gender were reviewed electronically and retrospectively through the hospital information system. Findings were recorded as positive or negative for appendicitis according to the final histopathological report.

All positive cases for appendicitis were sub-classified into different categories including (acute appendicitis, fibrous obliteration of the appendix, perforated appendix, reactive follicular hyperplasia of the appendix, appendix with neoplastic findings).

Inclusion criteria involved patients of both gender of all ages who underwent laparoscopic or open appendectomy at KHUH or private hospitals and were the appendectomy specimens has been grossed inside KHUH laboratory and examined microscopically by KHUH histopathologist consultants. Exclusion criteria included all second opinion cases that has been reported in other hospitals and sent as frozen blocks to KHUH for re-evaluation.

Statistical Analysis

We analyzed the Data using Microsoft Excel 2010 and SPSS1 21.0 software. And using the chi-square, the level of significance was set at $p < 0.05$. Ethical approval was obtained from the Ethics Committee at KHUH.

RESULTS

Table1: Distribution of appendectomy specimens according to the age and gender

Age (years)	Male	Female	Total (number (=n))
<10	11(34.37%)	21(65.62%)	32
11-20	62(66.66%)	31(33.33%)	93
21-30	70(62.5%)	42(37.5%)	112
31-40	47(78.33%)	13(21.66%)	60
41-50	9(47.36%)	10(52.63%)	19
51-60	3(23.07%)	10(76.92%)	13
>61	8(72.72%)	3(27.27%)	11
Total	210(61.76%)	130(38.23%)	340

A total of 340 appendectomies reports were reviewed during the study period. Among these patients, 210(61.76%) were males and 130(38.23%) were females. Most appendectomies were performed to

those patients aged in their twenties followed by teenagers. The lowest number of cases was in those who are older than 60 years old. Table1

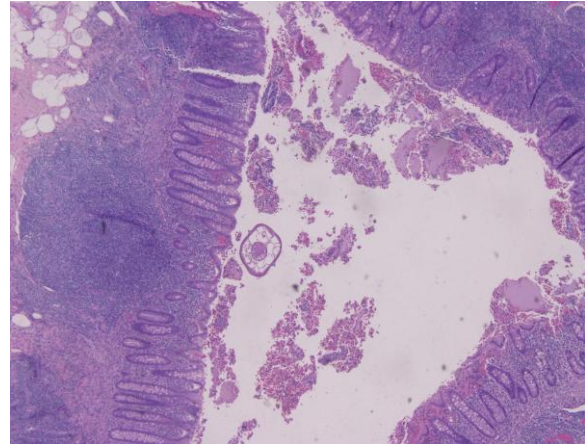


Figure 1: Section shows Enterobius vermicularis within the lumen of appendix.

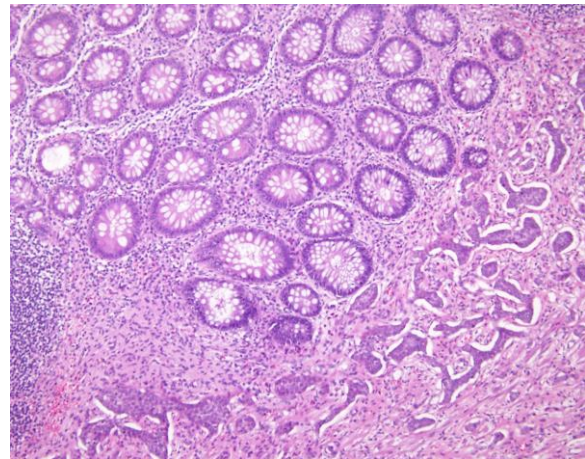


Figure 2A: Appendix showing carcinoid tumor infiltrating muscularis propria.

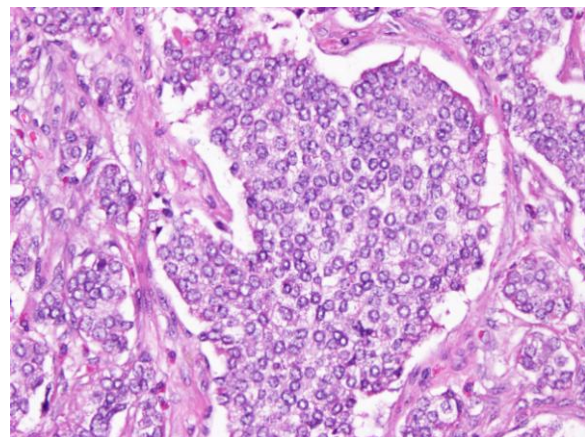


Figure 2B: Section showing nest of uniform round tumor cells with salt and pepper chromatin.

Out of 340 cases, 13(3.82%) had normal appendix and these predominantly were encountered in females 11(84.61%),

where only 2(15.38%) were noted in males. Abnormal findings associated with acute inflammation were documented in 294 out of 340 cases. These include cases of

perforated appendix, acute appendicitis, acute suppurative appendicitis, acute appendicitis with periappendicitis or serositis.

Table2: Distribution of appendectomy specimens according to their histopathological findings

Histological Diagnosis	Males (%)	Females (%)	Number of cases (%)	P-value
Acute Appendicitis	139(65.25)	74(34.74)	213(62.64)	<0.001
Acute Suppurative Appendicitis	17(60.71)	11(39.28)	28 (8.23)	0.257
Acute Appendicitis with periappendicitis or/ serositis	35(71.42)	14(28.57)	49(14.41)	0.003
Perforated appendix	3(75)	1(25)	4 (1.17)	0.317
Normal appendix	2(15.38)	11(84.61)	13 (3.82)	0.013
Fibrous obliteration of the appendix	4(28.57)	10(71.42)	14 (4.11)	0.109
Reactive follicular hyperplasia	4(100)	0	4 (1.17)	0.025
Enterobius vermicularis infestation	3(100)	0	3 (0.88)	0.163
Mucocele with focal area indefinite for low grade dysplasia	0	1(100)	1(0.29)	0.163
Carcinoid	3(50)	3(50)	6(1.76)	1.0
Low grade appendiceal mucinous neoplasm	0	2(100)	2 (0.58)	0.163
Low grade goblet cell adenocarcinoma	0	1(100)	1 (0.29)	0.163
High grade serous carcinoma	0	1(100)	1(0.29)	0.163
Signet ring cell carcinoma	0	1(100)	1(0.29)	0.163
Total	210	130	340	-

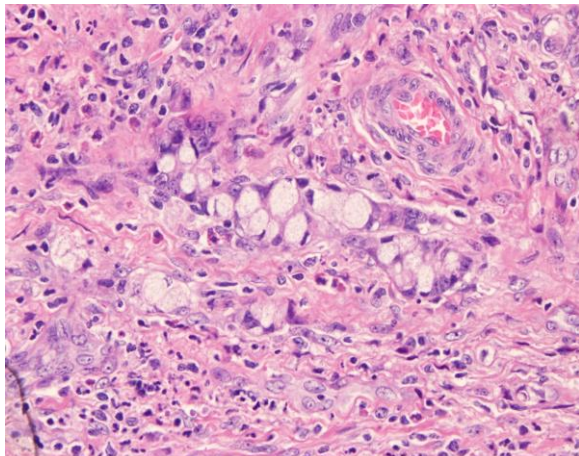


Figure 3: Section shows Goblet Cell Carcinoma surrounded by acute inflammatory cells

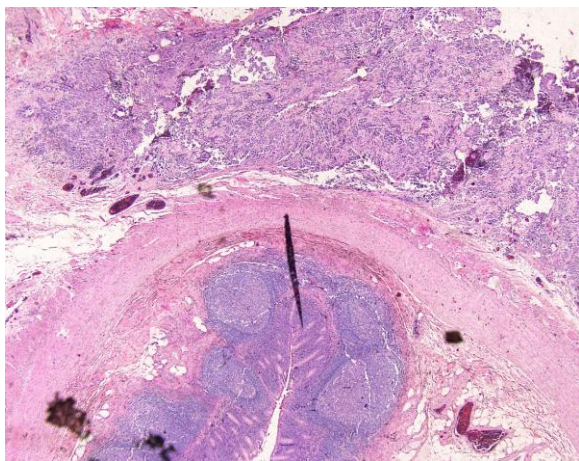


Figure 4: Section shows High grade serous carcinoma of appendix with metastatic ovarian carcinoma

Unexpected histopathological findings were seen in 33(8.49%) cases out of the total cases. The most prevalent unexpected finding was fibrous obliteration

of the appendix which constitute of 14/33 followed by carcinoid 6/33 and reactive follicular hyperplasia 4/33. Out of these 33 cases, only three males had Enterobius vermicularis (*E. vermicularis*) infestation. [figure 1] The remaining five unusual cases consist of neoplastic lesions like (carcinoid, goblet cell adenocarcinoma, serous carcinoma, mucinous neoplasm, mucocele,). Table2, [figure 2-6]

Significant correlation between gender and the following findings were seen ($P < 0.05$): acute appendicitis, acute appendicitis with periappendicitis/serositis, normal appendix and reactive follicular hyperplasia.

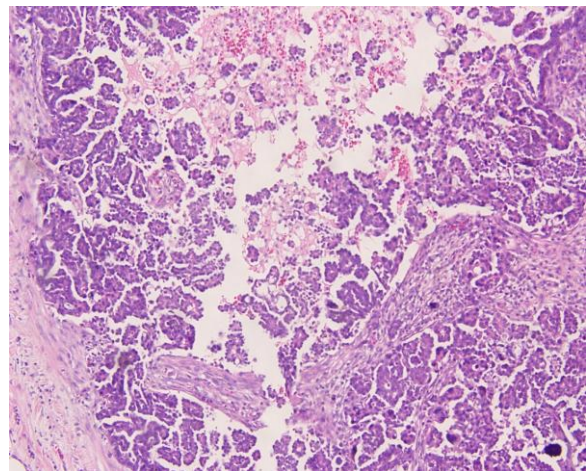


Figure 5A: Section shows Low grade appendiceal mucinous neoplasm invading muscularis propria

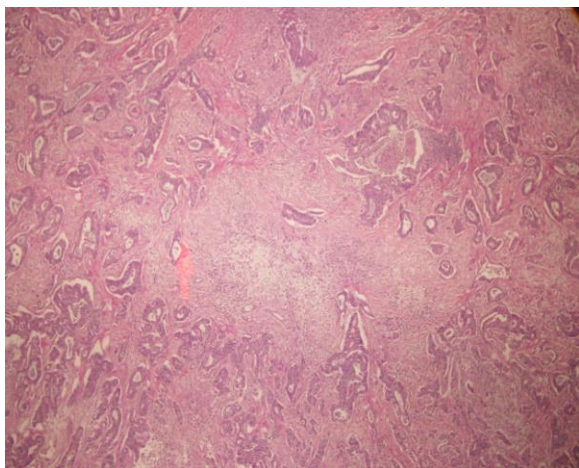


Figure 5B: Section shows Low grade appendiceal mucinous neoplasm invading muscularis propria

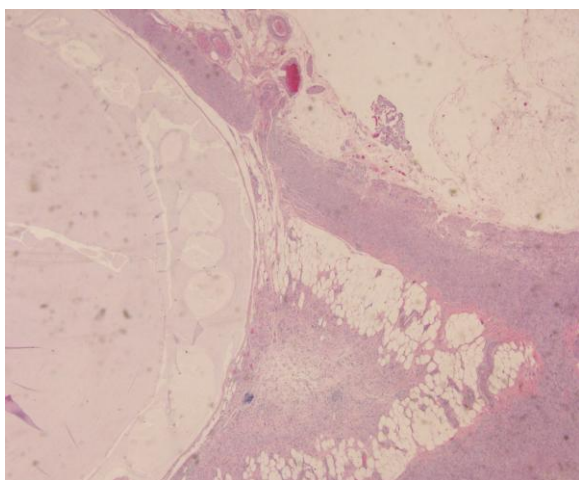


Figure 6: Section shows mucocoele with focal area indefinite for low grade dysplasia

DISCUSSION

Appendicitis is a common disease worldwide and its incidence reached its highest rate in the mid-portion of the 20th century in the western countries. (1,6) Also, the incidence of appendicitis has been escalated in many newly industrialized countries including the Middle East. (8) This might be due to many factors associated with industrialization of the societies, dietary habits, socioeconomic status and hygiene. (8)

In line with previous studies, the maximum number of appendectomy surgeries was seen in young adults and adolescence with higher frequencies in males 61.76% in comparison to females 38.23%. (9) Also, the most prevalent histopathological finding of appendectomy specimens in our study was acute

appendicitis (62.64%) followed by acute appendicitis with periappendicitis or serositis (14.41%) and acute suppurative appendicitis (8.23%). (10) In our study, the negative rate of appendicitis in appendectomy specimens is 3.82% which is at the lower limits in comparison to many previous studies. (1,11,12) This can be explained by the accurate clinical assessments in our hospital, different available diagnostic approach and expertise.

The literature showed that there is higher incidence of negative appendectomy specimens among young females. (11,13,14) Also, this was observed in our study as more females underwent appendectomy and had normal appendix during histopathological examination (84.61%) in comparison to males (15.38%).

This can be justified by the overlapping symptoms of acute appendicitis and many gynaecological conditions like abdominal pain, nausea and vomiting. Thus, highlight the importance of gynaecological referral when acute appendicitis is suspected in young adult females especially when no proper clinical judgment can be made.

On the other hand, atypical presentation of acute appendicitis can mimic other conditions and this may delay the diagnosis of acute appendicitis and lead to perforated appendix. Few studies showed higher rates of perforation among females and that was thought to be influenced by regional and culture issues where girls are more likely to be less prioritized in their families and thus cause delayed presentation to the hospital and further delay in management. (15) On the other hand, some studies did not reveal any significant relationship between delay to surgery and perforation rate. (16) Majority of studies showed higher perforation rates among males and elderly with comorbidities as they hypothesized that there is low index of suspicion of acute appendicitis in the elderly population. Additionally, it tends to be more aggressive in this age group and some elderly might not be able to communicate probably and explain their symptoms. (9,17-19)

Moreover, males group tend to have perforated appendix more frequently as they might have higher threshold for pain and thus delay the presentation to hospital. (16,17,20,21)

In the present study, slightly higher perforation rate was seen among males in comparison to females (3:1) and this might be due to the same listed reasons. However, the age group of the perforated appendix is not specified in this study and thus we cannot conclude any further correlations. Unexpected findings of appendectomy specimens including benign and malignant conditions were reported by different studies that emphasis on the importance of histopathological examination of all appendectomy specimens. (2,22,23) On the other hand, some published papers suggested histopathological examination should only be limited to the macroscopically abnormal appendix due to the low incidence of the unusual findings. (24,25)

In our study, 9.66% of the reviewed appendectomy specimens had unexpected histopathological findings. Of these, *Enterobius vermicularis* which is a widespread parasitic infection found in three cases (0.88%) in our data. While other studies presumed that it can be detected up to 41.8 % of appendectomy specimens and higher incidence rate was detected in Asia, Africa, and the Middle East countries which might be related to overcrowding and poor sanitation. (3, 4) Those infected patients should be treated with anti-helminthic medications as appendectomy alone does not treat the root of the disease. (2,23) Lymphoid hyperplasia was seen in 1.17% of cases with male predominance. This condition is usually misdiagnosed as acute appendicitis and is hypothesized to be associated with lymphoid tissue development which increases after the age of ten and in males especially after the puberty leading to functional obstruction. (7,26) The most unusual findings in our study was neurogenic appendicopathy which constituted of 4.11% of appendectomy

specimens and this is usually referred as a process of fibrous obliteration. Although, many studies indicated that it is secondary to hyperplasia of neuroendocrine cells and it is usually found as an incidental finding in asymptomatic patients. (7,26) Carcinoid tumors which is also known as the most prevalent appendiceal tumours 37 was found in 1.76% of cases. Simple appendectomy is usually sufficient for benign small carcinoid tumours; however larger tumours more than two cm is usually managed by right hemicolectomy. (26,27) Moreover, mucocele of the appendix is a rare disease accounting for 0.2 to 0.3%. (28) In our study, only one case of mucocele with focal area indefinite for low grade dysplasia was found. The management approach for benign mucocele is appendectomy with lymphadenectomy and further partial cecal resection is preserved for dilated appendicular base (> 2cm). (28)

Additionally, a similar incidence rate (0.29%) of low grade goblet cell adenocarcinoma, high grade serous carcinoma, signet ring cell carcinoma was found in the present study. And these conditions are rare and some of them are having different challenging treatment modalities. (29,30) That is why we believe that selective histopathological examination of abnormal looking appendix can miss important findings that can affects patients' morbidity and mortality and would require further management plan rather than simple appendectomy.

CONCLUSION

In summary, acute appendicitis is the commonest findings in our appendectomy specimens. The most common unusual findings were carcinoid tumours. However other unexpected findings like parasitic infection and malignant tumours were found. Histopathological examination is of a great value as it can identify the exact cause of appendicitis which sometimes requires further treatment.

Financial support and sponsorship

Nil.

Conflicts of Interest

There are no conflicts of interest.

Acknowledgement: None

Ethical Approval: Approved

REFERENCES

1. Bahar AN, Farghaly AS, Ahmed MT, et al. Normal versus pathological appendix in clinically suspected acute appendicitis “randomized controlled trials”. *Clin Surg.* 2016;1:1026. doi: <http://clinicsinsurgery.com/>.
2. Al-Fatah MA. Importance of histopathological evaluation of appendectomy specimens. *Al-Azhar Assiut Medical Journal.* 2017;15: 97-103. doi: <http://www.azmj.eg.net/article.asp?>
3. Snyder MJ, Guthrie M, Cagle S. Acute Appendicitis: Efficient Diagnosis and Management. *Am Fam Physician.* 2018; 98:25-33. doi: 30215950.
4. Acharya A, Basnet RB, Singh RB, et al. Is Routine Histopathological Examination of Appendix Mandatory?. *Journal of Gandaki Medical College-Nepal.* 2018; 11:55-5. doi: 10.3126/jgmcn.v11i02.22973
5. Swank HA, Eshuis EJ, Ubbink DT, et al. Is routine histopathological examination of appendectomy specimens useful? A systematic review of the literature. *Colorectal Diseases.* 2010; 13:1214-1221. doi: 10.1111/j.1463-1318.2010.02457.x.
6. Monajemzadeh M, Haggahi-Ashtiani MT, Montaser-Kouhsari L, et al. Pathologic evaluation of appendectomy specimens in children: is routine histopathologic examination indicated?. *Iran J Pediatr.* 2011;21:485-490. doi: 23056836
7. Kulkarni MP, Sulhyan KR, Barodawala SM, et al. Histopathological study of lesions of the appendix. *Int J Health Sci Res.* 2017;7:90- 95. doi: 23056836
8. Ferris M, Quan S, Kaplan BS, et al. The Global Incidence of Appendicitis: A Systematic Review of Population-based Studies. *Annals of Surgery.* 2017;266: 237-241. doi: 10.1097/SLA.0000000000002188
9. Marudanayagam R, Williams GT, Rees BI. Review of the pathological results of 2660 appendectomy specimens. *J Gastroenterol.* 2006;41:745-749. doi: 10.1007/s00535-006-1855-5
10. Zulkar I, Khanzada TW, Sushel C, et al. Review of the pathologic diagnoses of appendectomy specimens. *Ann King Edward Med Univ* 2009;15:168-70. doi:10.12669/pjms.314.7453
11. Alhamdani YF, Rizk HA, Algethami MR, et al. Negative Appendectomy Rate and Risk Factors That Influence Improper Diagnosis at King Abdulaziz University Hospital. *Mater Sociomed.* 2018;30:215-220. doi: 10.5455/msm.2018.30.215-220
12. Lim J, Pang Q, Alexander R. One year negative appendectomy rates at a district general hospital: A Retrospective Cohort Study. *International Journal of Surgery.* 2016;31:1-4. doi: 10.1016/j.ijso.2016.05.030
13. Joshi MK, Joshi R, Alam SE, et al. Negative Appendectomy: an Audit of Resident-Performed Surgery. How Can Its Incidence Be Minimized?. *Indian J Surg.* 2015;77:913-917. doi: 10.1007/s12262-014-1063-0
14. Osime O, Ajayi P. Incidence of negative appendectomy: experience from a company hospital in Nigeria. *Cal J Emerg Med.* 2005;6:69-73. doi: PMC2906999
15. Avci V, Ayengin K. Why is the rate of perforated appendicitis higher in girls in eastern Turkey, unlike the literature? *Turk Pediatri Arsivi.* 2019;54:40-43. doi: 10.14744/turkpediatriars.2019.82956
16. Guss DA, Richards C. Comparison of men and women presenting to an ED with acute appendicitis. *The American Journal of Emergency Medicine.* 2000;18:372-375. doi: 10.1053/ajem.2000.7323
17. Augustin T, Cagir B, Vander MTJ. Characteristics of Perforated Appendicitis: Effect of Delay Is Confounded by Age and Gender. *J Gastrointest Surg.* 2011;15:1223. doi: 10.1007/s11605-011-1486-x
18. Drake FT, Mottey NE, Farrokhi ET, et al. Time to appendectomy and risk of perforation in acute appendicitis. *JAMA Surg.* 2014;149:837-44. doi: 10.1001/jamasurg.2014.77.
19. Shirah BH, Shirah HA, Alhaidari WA. Perforated Appendix - Delay in Presentation Rather than Delay in the Surgical Intervention: Retrospective Database Analysis of 2573 Saudi Arabian Patients in

- 10 Years. *International Journal of Scientific Study*. 2016;4:32-36. doi: 10.17354/ijss/2016/183
20. Hale DA, Molloy M, Pearl RH, et al. Appendectomy: a contemporary appraisal. *Ann Surg*. 1997;225:252-261. doi: 10.1097/00000658-199703000-00003
21. Rogers AD, Hampton MI, Bunting M, et al. Audit of appendectomies at Frere Hospital. *South African Journal of Surgery*. 2008;46:74-78. doi: 2078-5151
22. Akbulut S, Tas M, Sogutcu N, et al. Unusual histopathological findings in appendectomy specimens: a retrospective analysis and literature review. *World J Gastroenterol*. 2011;17:1961-70. doi: 10.3748/wjg.v17.i15.1961
23. Limaiem F, Arfa N, Marsaoui L, et al. Unexpected Histopathological Findings in Appendectomy Specimens: a Retrospective Study of 1627 Cases. *Indian J Surg*. 2015;77(Suppl 3):1285-1290. doi: 10.1007/s12262-015-1278-8
24. Cross SS, Stone JL. Proactive management of histopathology workloads: analysis of the UK Royal College of Pathologists' recommendations on specimens of limited or no clinical value on the workload of a teaching hospital gastrointestinal pathology service. *J Clin Pathol*. 2002;55:850-852. doi: 10.1136/jcp.55.11.850
25. Zdichavsky M, Gögele H, Blank G, et al. Histological characterization of appendectomy specimens with intraoperative appearance of vascular injection. *Surg Endosc*. 2013;27:849-853. doi: 10.1007/s00464-012-2523-x
26. Emre A, Akbulut S, Bozdog Z, et al. Routine histopathologic examination of appendectomy specimens: retrospective analysis of 1255 patients. *Int Surg*. 2013;98:354-62. doi: 10.9738/INTSURG-D-13-00098.1
27. Shapiro R, Eldar S, Sadot E, et al. Appendiceal carcinoid at a large tertiary center: pathologic findings and long-term follow-up evaluation. *The American Journal of Surgery*. 2011;201:805-808. doi: 10.1016/j.amjsurg.2010.04.016
28. Filho JD, Lira ED. Mucocele of the appendix: appendectomy or colectomy?. *Journal of Coloproctology*. 2011;31. doi: <http://dx.doi.org/10.1590/S2237-93632011000300008>
29. Clift AK, Kornasiewicz O, Drymoussis P, et al. Goblet cell carcinomas of the appendix: rare but aggressive neoplasms with challenging management. *Endocr Connect*. 2018;7:268-277. doi: 10.1530/EC-17-0311
30. Kulkarni RV, Ingle SB, Siddiqui S. Primary signet ring cell carcinoma of the appendix: A rare case report. *World J Clin Cases*. 2015;3:538-541. doi: 10.12998/wjcc.v3.i6.538

How to cite this article: Maryam Adam Mohamed Ali, Sameer Ahmed A.H Ansari, Khalid Al Sindi et.al. Routine histopathological examination of appendix: the practice that cannot be ignored. *Int J Health Sci Res*. 2021; 11(4): 48-54. DOI: <https://doi.org/10.52403/ijhsr.20210406>
