

# Cat-Scratch Disease Presenting as a Post Auricular Swelling in a Young Male

Akansha Yadav<sup>1</sup>, Bhavika Verma<sup>2</sup>, Stuti Mathur<sup>3</sup>, Yogesh. G. Dabholkar<sup>4</sup>

<sup>1</sup>Junior Resident in Department of ENT at Dr. D.Y.Patil Hospital and Medical College, Nerul, Navi Mumbai

<sup>2</sup>Assistant Professor in Department of ENT at Dr. D.Y.Patil Hospital and Medical College, Nerul, Navi Mumbai

<sup>3</sup>Junior Resident in Department of ENT at Dr. D.Y.Patil Hospital and Medical College, Nerul, Navi Mumbai

<sup>4</sup>Professor and Head of Department of ENT at Dr. D.Y.Patil Hospital and Medical College, Nerul, Navi Mumbai

Corresponding Author: Akansha Yadav

## ABSTRACT

Cat-Scratch disease is a relatively common, zoonotic, infectious disease transmitted by young cats that serve as passive vectors for the *Bacillus bartonella henselae*. Cat Scratch Disease, also known as Cat scratch fever or subacute regional lymphadenitis, is a bacterial infection affecting lymph nodes that drain the sites of inoculation. This is a report of a case of cat scratch disease diagnosed by histopathology report in a patient with a history of left post auricular swelling.

**Keywords-** Cat Scratch disease, Regional Lymphadenitis, Lymph node Biopsy, Zoonoses.

## INTRODUCTION

Cat scratch disease, also known as cat scratch fever or subacute regional lymphadenitis, is a bacterial infection affecting lymph nodes that drain the sites of inoculation. *Bartonella henselae*, a gram-negative rod, is considered the principal etiologic agent [1,2]. Cat scratch disease is one of the most common causes of chronic lymphadenopathy in children and adolescents [3]. Hence, this diagnosis should be kept in mind when evaluating a patient with lymphadenitis.

## CASE REPORT

A 20yr old male patient presented to the out patient department with complaints of left post auricular swelling associated with left ear discharge since 2 months. Left ear discharge being purulent, scanty, continuous, foul smelling and occasionally blood-stained. Patient gives a history of being scratched by a cat 3 months back following which he developed left post-auricular swelling. Swelling gradually increased in size over a period of 4 weeks.

Swelling was associated with intermittent low grade fever with anorexia and generalised weakness.

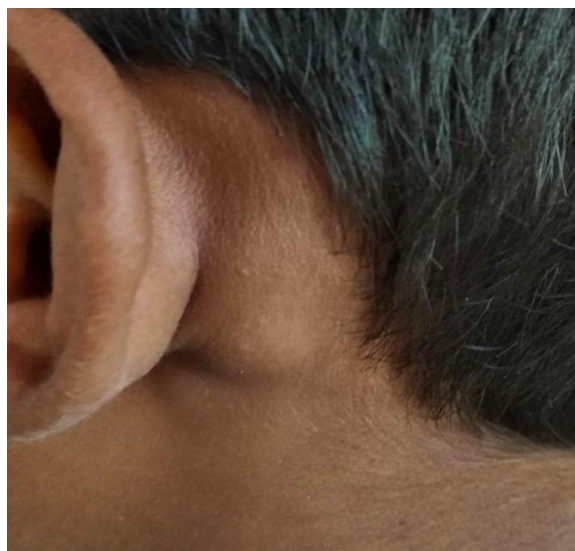

Figure 1-left postauricular swelling

On examination, 2cmX2cm left sided nodular swelling present externally which was tender and cystic on palpation. Swelling presented with well defined margins with restricted mobility. Skin over the swelling was non

erythematous. There was no discharging sinus or pointing abscess. No bruit or any pulsation was present in the swelling.

Mastoid tenderness was present but no tragal tenderness was appreciated. Facial nerve function was intact.

On otoscopic examination, Left tympanic membrane showed Grade 2 Retraction and Right ear tympanic membrane appeared intact.

#### **Interpretation of Tuning fork test:**

Rinne's negative bilaterally with 256HZ, 512HZ and 1024HZ tuning fork. Weber's test was lateralised to left ear with 512HZ and Air bone conduction test equal on both sides with 512HZ.

Pure tone audiometry result was bilateral moderate conductive hearing loss.

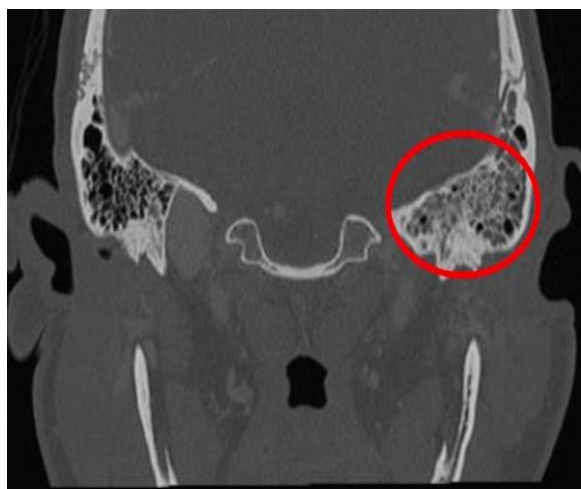

Figure 2-Left sided otomastoiditis on HRCT Temporal Bone

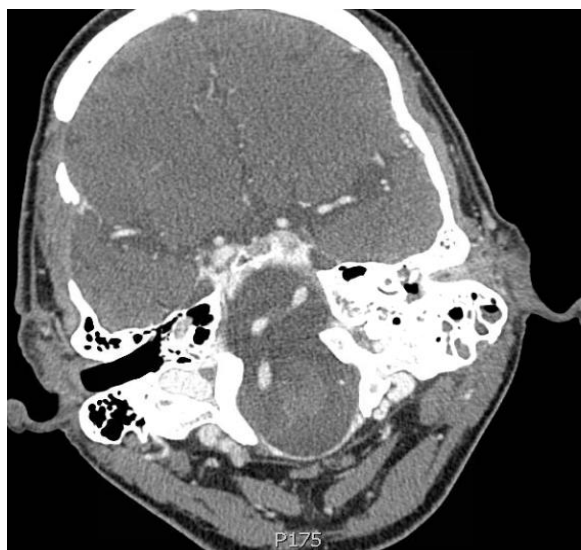

Figure 3- Hypopneumatization of left mastoid air cells with soft tissue and fluid density contents within.

HRCT temporal bone was suggestive of relative hypopneumatization of left mastoid air cells with soft tissue and fluid density contents within. Extension is seen into the entire middle ear through the aditus and antrum suggestive of oto-mastoiditis.

A 2.3 X 0.9 cm peripherally enhancing posterior auricular abscess was noted in the subcutaneous plane which was seen communicating with 3.9 cm sized bony defect involving the lateral wall of the mastoid bone.

Patient was admitted for systemic antibiotic therapy and subsequently underwent left cortical mastoidectomy under general anaesthesia.

Intraoperative findings revealed pus pocket in subcutaneous plane from which swab was taken and sent for culture and sensitivity. Granulation tissue from pus cavity over left mastoid was also removed and sent for histopathology.

Histopathology report was suggestive of dense chronic inflammatory cell infiltrate composed of lymphocytes and plasma cells and gave the impression of cat scratch disease. There was no evidence of granuloma, atypia or malignancy.

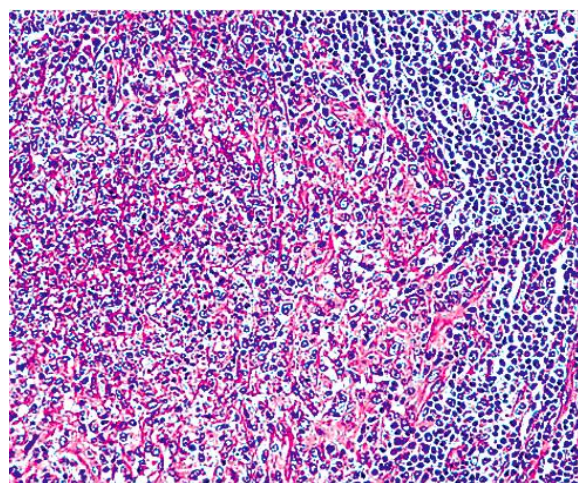


Figure 4 - Microscopic (Histology) image of lymph node biopsy

After 1 month, patient again started developing left post auricular abscess for which incision and drainage was done and pus was aspirated, dressing was done on every alternate day under antibiotic cover.

Patient recovered completely after 2 weeks of treatment. Follow up after a week was uneventful. Patient has been asymptomatic during his follow-up period.

## DISCUSSION

Cat-scratch disease is a relatively common infectious disease seen primarily in children and adolescents [3]. Clinical presentation may be rather dramatic, with the presence of an inoculation lesion and large, regional lymph nodes in one or more anatomic sites. Diagnostic tests for cat scratch disease like serology which can be performed by indirect fluorescent assay or enzyme-linked immunosorbent assay are available, but cat scratch disease is frequently diagnosed by clinical symptoms and a positive history of contact with young cats or kittens [4]. The course of cat scratch disease is self-limiting, and lymphadenitis generally resolves in 2 to 4 months with no treatment. Use of oral antibiotics such as trimethoprim-sulfamethoxazole or ciprofloxacin may be helpful in shortening the course in uncomplicated cases managed in the primary-care setting. Aggressive treatment for atypical or complicated cases of cat scratch disease is indicated. Since cat scratch disease is seasonal, clinicians may anticipate contact with patients who have symptoms of the disease and should be cognizant of asking about contact with any pets, especially cats.

Patients with cat scratch disease usually have a history of sustaining a scratch or bite from a cat (typically a kitten). The initial symptom is formation of a papule at the inoculation site, followed by solitary or regional lymphadenopathy within 1-2 weeks. In most patients, the disease resolves spontaneously within 2-4 months.

The organism has been isolated from fleas residing on infected cats. Studies have shown that flea-vectored transmission of infection among cats occurs with high efficiency and that in the absence of fleas, infected cats do not transmit the infection to uninfected cats [5].

In general, lymph nodes become enlarged in the 1-2 weeks after exposure. They are often tender and occasionally become fluctuant.

More than 90% of patients with cat scratch disease develop one or more 3- to 5-mm red-brown nontender papules at the site of inoculation 3-10 days after the bacteria are introduced [6]. These primary lesions last for 1-3 weeks then recede as lymphadenopathy appears.

Within 1-3 weeks, lymphadenopathy develops in a single node or group of regional nodes draining the inoculation site. Lymphadenopathy can be moderately tender, with erythema and increased warmth of the overlying skin. Lymphadenopathy remains regional and typically resolves within 2-4 months but may last up to 6-12 months. Rarely, it may persist for a year or more. The lymphadenitis often takes several months to resolve but most patients develop lifelong immunity to the infection. [7,8]. Approximately 10-30% of nodes may suppurate, requiring needle aspiration.

In case of any suppuration, lymph node aspiration may be required. Aspiration of suppurating nodes is both diagnostic as well as therapeutic procedure. Repeated aspirations may be performed if pus re-accumulates and pain recurs. Recurrence of suppuration can be treated by incision and drainage.

## CONCLUSION

Cat scratch disease is one of the most common causes of chronic lymphadenopathy in children and adolescents. Accurate diagnosis can be made on detailed history of patient with bite or scratch of cats. Cat scratch disease is self-limiting.

This article helps to create awareness about cat scratch disease in health practice as well as in pet owners.

## REFERENCES

1. N Busen, T Scarborough. Diagnosis and Management of Cat-Scratch Disease in Primary Care. The Internet Journal of

- Advanced Nursing Practice. 1996 Volume 1 Number 2.
2. Baranowski K, Huang B. Cat Scratch Disease. [Updated 2020 Jun 23]. In: StatPearls [Internet]. Treasure Island (FL): StatPearls Publishing; 2020 Jan.
  3. Arvand M, Kazak I, Jovanovic S, Foss HD, Liesenfeld O. Cervical cat scratch disease lymphadenitis in a patient with immunoglobulin M antibodies to *Toxoplasma gondii*. *Clin Diagn Lab Immunol*. 2002;9(2):496-498. doi:10.1128/cdli.9.2.496-498.2002
  4. Opavsky, M A. "Cat scratch disease: The story continues." *The Canadian journal of infectious diseases = Journal canadien des maladies infectieuses*. vol. 8,1 (1997): 43-9. doi:10.1155/1997/982908
  5. Brown LD, Banajee KH, Foil LD, Macaluso KR. Transmission mechanisms of an emerging insect-borne rickettsial pathogen. *Parasit Vectors*. 2016;9:237. Published 2016 Apr 26. doi:10.1186/s13071-016-1511-8
  6. Sölder B, Allerberger F, Covi B, et al. Katzenkratzkrankheit durch *Bartonella henselae* [Cat scratch disease caused by *Bartonella henselae*]. *Immun Infekt*. 1995;23(6):228-231.
  7. Barros S, de Andrade GC, Cavalcanti C, Nascimento H. Cat Scratch Disease: Not a Benign Condition. *Ocul. Immunol. Inflamm*. 2018;26(7):1115-1122.
  8. Prutsky G, Domecq JP, Mori L, Bebko S, Matzumura M, Sabouni A, Shahrour A, Erwin PJ, Boyce TG, Montori VM, Malaga G, Murad MH. Treatment outcomes of human bartonellosis: a systematic review and meta-analysis. *Int. J. Infect. Dis*. 2013 Oct;17(10):e811-9.
- How to cite this article: Yadav A, Verma B, Mathur S et.al. Cat-scratch disease presenting as a post auricular swelling in a young male. *Int J Health Sci Res*. 2021; 11(2): 287-290.

\*\*\*\*\*