

Primary Mucosal Melanoma of Oral Cavity - Case Report

Abhijit Bhanji¹, Shailesh Desai², Paritkumar Ladani³

¹Department of Surgical Pathology, Brahmakumaris Global Hospital and Research Centre, BSES MG Hospital, S. V. Road, Opposite Andheri railway station, Andheri (West) Mumbai, Maharashtra, India

²Department of Surgical Pathology, ESIS Hospital, Worli, Ganapat Jadhav Marg, B Wing, BDD Chawls, Worli, behind Poddar Hospital, Mumbai, Maharashtra

³Department of Dentistry, Brahmakumaris Global Hospital and Research Centre, BSES MG Hospital, S. V. Road, Opposite Andheri Railway Station, Andheri (West) Mumbai, Maharashtra, India

Corresponding Author: Abhijit Bhanji

ABSTRACT

Primary oral mucosal melanoma (POMM) is a rare malignant neoplasm of melanocytic origin with incidence of 0.5% of all oral malignancies. Malignant melanoma is more common among 5th to 6th decades of life with predilections more to males than females. The rarity of this lesion with mainly asymptomatic presentation leads to poor prognosis. Here is a case report presenting a malignant melanoma of oral mucosa in 49-year-old male patient on maxillary gingiva. Therefore the patient was suggested for wide alveolar excision with bilateral neck dissection. Thus dental clinicians play a major role in the identification of pigmented lesions of oral cavity as in our case. Also it is important that any pigmented lesion detected in the oral cavity with potential growth should be biopsied and thereby, submitted for histopathology to exclude malignancy. There is necessity of early detection and highly specialized treatment options that should be brought in serious consideration.

Keywords: Primary malignant melanoma, oral mucosa, melanocytes, gingiva.

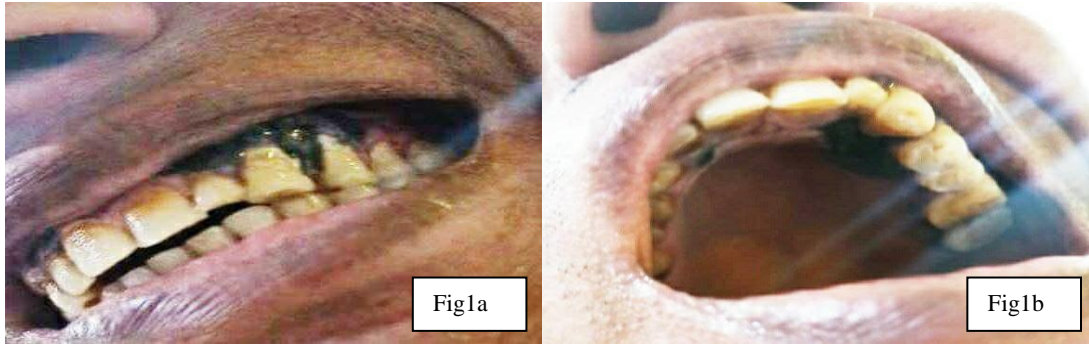INTRODUCTION

Melanoma develops from malignant change of melanocytes arising from neural crest. The cells and the corresponding neoplasms arising from the neural crest are grouped under Dispersed Neuro-Endocrine System (DNES) tumors. Incidence of melanoma of the head and neck account for 25% of all melanomas while mucosal melanomas are only less than 1% of all melanoma. However, incidence of mucosal melanoma accounts for 10% of melanoma of the head and neck. The most common sites for mucosal melanoma in order are nasal, paranasal sinuses, oral cavity, and nasopharynx of which, paranasal sinus has the worst prognosis. The nasal and oral cavity has best prognosis. Mucosal

melanoma is more common in males as compared to cutaneous melanoma are more common in females. Clinically lesions are mostly asymptomatic until ulceration and hemorrhage develops which causes delayed detection in late stages. Therefore 5-year survival is poor at approximately 15% to 30% only^[1-4].

CASE REPORT

A 49 year old male presented to department of oral and maxillofacial surgery with complaints of black pigmentation lesion in left upper labio-gingival region since 1.3 years shown in Fig (1a) and (1b) below. History of rapid growth with spread at lesion since 2 months.



History of hypertension since 2 months and on anti-hypertensives. No history of smoking, alcohol, tobacco and trauma. Local examination shows 5 X 3 cm black lesion with irregular surface present at labio-gingival region opposite 3rd molar with no ulceration. Lesion is spreading over palatal and adjacent gingival region. Similar lesion present opposite of 2nd molar.

Histopathology report of mucogingival junction biopsy showed thinned out epithelium with loss of rete ridges. There

are clusters and sheets of polygonal cells with melanin pigmentation in cytoplasm with round to oval nuclei with prominent nucleoli with atypia and mitosis. It was concluded to be malignant melanoma primarily of origin of oral mucosa with no evidence of secondary origin as seen on whole body PET scan. Immunohistochemistry was positive for S-100 protein and HMB45 protein confirming diagnosis of malignant melanoma.

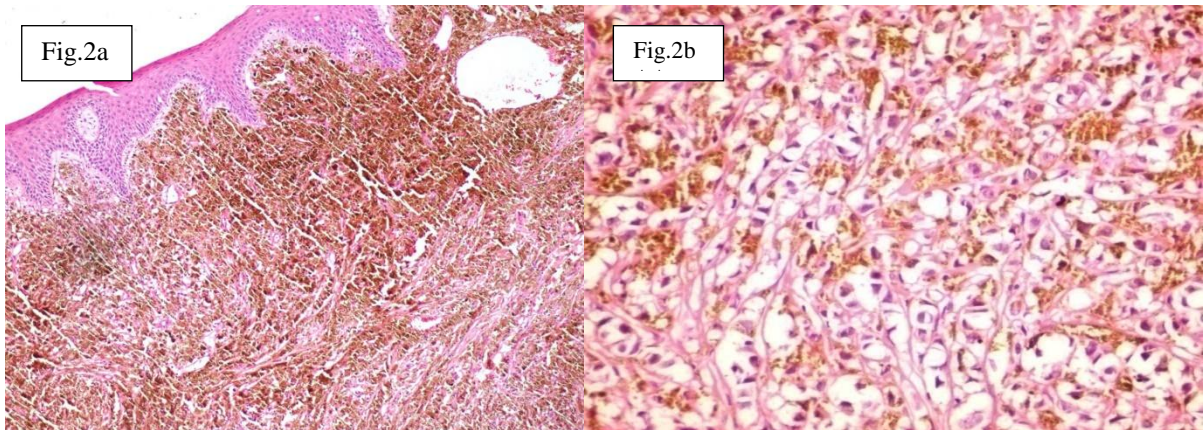


Fig (2a) under 10x & (2b) under 40x shows sheets of melanin containing pleomorphic cells in the connective tissue

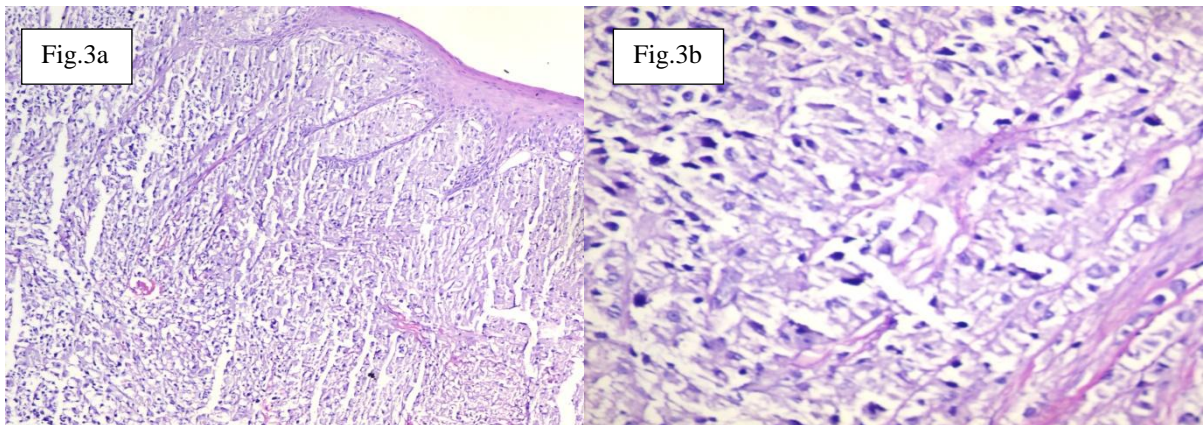
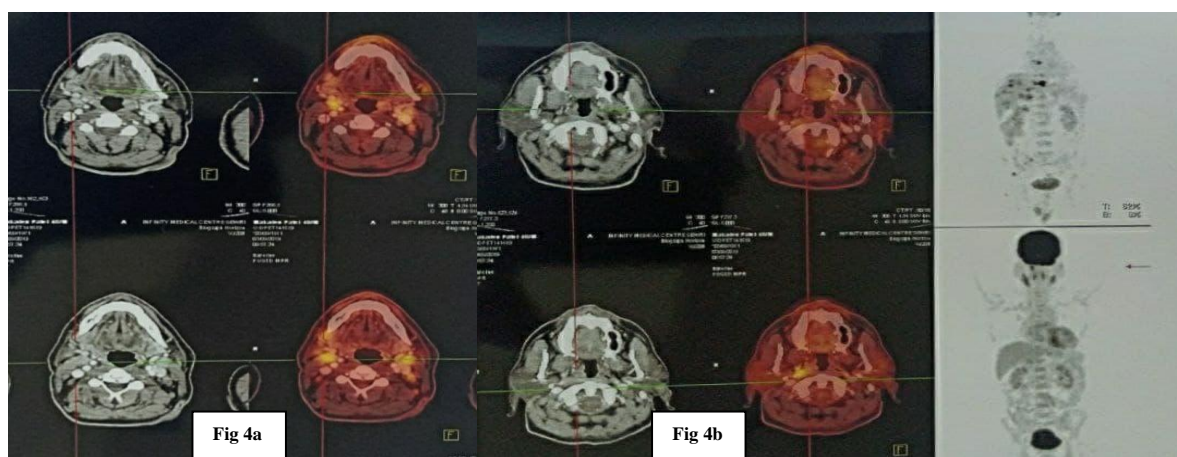


Fig (3a) under 10x & (3b) under 40x after bleaching shows sheets of pleomorphic cells in the connective tissue

PET scan suggestive of metabolically active soft tissue lesion along the posterosuperior nasopharyngeal wall

would likely be primary malignant lesion with right parapharyngeal and bilateral level IB-IV cervical lymph node metastasis.



PET scan also revealed that there metabolically sites in lungs, liver, posterior wall of gall bladder and skeleton involving right pedicle of C6, D6, D8, D9 vertebrae, sacrum, right iliac bones and right proximal femur with suspicion of metastasis depicted in fig.4a & 4b.

Biopsy from right nasopharyngeal growth done suggestive of chronic granulomatous inflammation and was inconclusive when done before mucogingival junction biopsy. Under TNM staging of head and neck cancer our patient falls under T3N1M0 staging.

Patient was advised wide alveolar excision with bilateral neck dissection as palliative care and further follow-up with chemo-radiotherapy & conservative supportive treatment.

DISCUSSION

Oral malignant melanomas are extremely rare lesions with approximately 2% of all melanomas cases have been reported in literature. [6-8] Cigarette smoking, denture irritation, and alcohol consumption are some of the suggested risk factors, but their correlation is still not established. [9] Exposures to tobacco and formaldehyde have also been suggested as causative agents for intraoral melanomas. [10] In the present case, the patient was not exposed to any of these factors and hence

the possible etiological factor for this patient is still unclear.

Some studies suggest involvement of two signalling pathways in pathogenesis of mucosal melanoma [11]. The mitogen-activated protein kinase (MAPK) pathway (RAS/MEK/ERK) is a critical growth cascade involved in oral mucosal melanoma. Second important pathway involved is the phosphatidylinositol-3-kinase-PTEN pathway (PI3K/AKT/PTEN/mTOR) involving cell death regulation. Both signalling pathways are triggered by activation of c-kit which is involved in regulation of activity of MITF (microphthalmia-associated transcription factor) that is important in melanogenesis and melanocyte function [12]. High rate of c-kit expression and MITF expression is associated with mucosal melanoma of head and neck cancers. Thus, the association of these pathways with malignant melanoma might be useful for potential targeted therapy.

The mean age of onset of malignant melanomas is 55 years & usually between the ages of 40 to 70 years. [13] The lesion is more common in men than in women with sex ratio of 3:1 [14]. In the oral cavity, most common site of malignant melanoma is palate followed by maxillary gingiva with an incidence of 80% and 91.4%, respectively [15,16]. The occurrence of

malignant melanoma on the mandibular gingiva is comparatively rare. Our patient is one of the common cases with the site of lesion in the mandibular gingiva.

The patient has noticed the pigmented lesion about one year ago and it proliferated at a rapid rate then. About 50-70% of primary oral melanomas appear as new lesions from apparently normal mucosa, whereas 30-50% cases develops from oral pigmentations for several months. Some of the pre-melanoma lesions include mucosal melanosis and a variety of melanocytic nevi. [17] About 30 to 73% patients of oral melanosis has been suggested as a predisposing factor for the development of oral mucosal melanoma. Although there is a higher occurrence of primary oral melanoma in India, there is low incidence of melanosis in India, thereby contraindicating this that melanosis act as predisposing factor in primary oral melanoma. [18]

The mucosal melanomas can show two principal patterns: (1) An *in situ* pattern in which the neoplasm is limited to the epithelium and epithelial-connective tissue interface (junctional) (2) An invasive pattern in which the neoplasm is found within the supporting connective tissue [19].

Greene *et al* [20] suggested the following criteria for a lesion to be considered as primary malignant melanoma of the oral cavity: 1) demonstration of malignant melanoma both histologically and clinically; 2) the presence of junctional activity; and 3) the inability to demonstrate any other primary site. Based on these criteria, this case could be considered as a primary oral malignant melanoma.

Primary oral melanoma is markedly aggressive and invasive that metastasizes by both local and distant metastases to sites such as lungs, liver, brain, and bones [21]. A crucial prognostic factor for oral melanomas is lymphatic metastasis at the time of diagnosis. Our case also advanced to distant metastasis involving lungs, liver and bones.

The American Joint Committee on Cancer (AJC) does not have published

guidelines for the staging of oral malignant melanomas; yet, probably due to the rare occurrence of this lesion [5]. Some suggest TNM staging of head and neck cancer with melanoma for staging of primary oral melanoma to help with further management of it.

Differential diagnosis of oral mucosal melanoma are melanosis, melanotic macule, oral nevi, racial pigmentation, smoking-associated melanosis, postinflammatory pigmentation, amalgam tattoo, drug induced melanosis caused by antimalarial drugs, phenothiazines, oral contraceptives and various cytotoxic medications, melanoacanthoma, Peutz-Jeghers syndrome, Addison's disease and Kaposi's sarcoma. These possibilities were ruled out in our case.

Surgery is the preferred treatment followed by chemotherapy, radiotherapy, and immunotherapy. It has been seen to reduce and prevent the recurrence of the lesion with surgical excision followed by immuno-chemotherapy. But it is not established fact as there are only a few reported cases in literature. [22]

In the cases with distant metastasis, the disease is considered as classically incurable, surgery being considered only for palliative care [21]. Other treatment modalities like radiotherapy and chemotherapy also offers palliative care in these cases.

The oral melanoma has poor prognosis with a five-year survival of 0-55% of these cases. The median survival is slightly more than two years from the time of diagnosis for all oral mucosal melanomas. [23] Independent prognostic factors that have been suggested are tumor thickness greater than 5 mm, ulceration and greater than 10 mitotic figures per high power fields for all oral mucosal melanomas. Tumors which are diagnosed early, especially in the *in situ* stage, are potentially curable and may have a better prognosis and survival.

CONCLUSION

Oral malignant melanoma are very clinically asymptomatic and early detection and diagnosis on histopathology is key to prolonged survival and good outcome with adequate management of the tumor despite being very aggressive and rapidly invasive tumor. It is extremely rare malignancy which may even be due to lack of adequate timely diagnosis and also reporting very few cases as seen in literature. So it is necessary to bring this entity to picture via reporting such cases so that it will be helpful to devise definite diagnostic and management approach to limit the severity of these tumors.

ACKNOWLEDGEMENTS

Brahmakumaris Global hospital and research, BSES MG Hospital funded for all. Also the IHC (Immunohistochemistry) was sent to reference lab.

Abbreviations:

POMM (Primary oral mucosal melanoma), PI3K (Phosphatidylinositol-3-kinase).

Conflict of Interest:

There is no conflict of interest in our case report.

REFERENCES

1. PDQ Pediatric Treatment Editorial Board. PDQ Cancer Information Summaries [Internet]. National Cancer Institute (US); Bethesda (MD): May 21, 2020. Rare Cancers of Childhood Treatment (PDQ®): Health Professional Version.
2. Panda S, Dash S, Besra K, Samantaray S, Pathy PC, Rout N. Clinicopathological study of malignant melanoma in a regional cancer center. *Indian J Cancer*. 2018 Jul-Sep;55(3):292-296.
3. Natarajan E. Black and Brown Oro-facial Mucocutaneous Neoplasms. *Head Neck Pathol*. 2019 Mar;13(1):56-70.
4. Lee JS, Lee H, Lee S, Kang JH, Lee SH, Kim SG, Cho ES, Kim NH, Yook JI, Kim SY. Loss of SLC25A11 causes suppression of NSCLC and melanoma tumor formation. *EBioMedicine*. 2019 Feb;40:184-197.
5. Padhye, A., & D'Souza, J. (2011). Oral malignant melanoma: A silent killer. *Journal of Indian Society of Periodontology*, 15(4), 425–428. <https://doi.org/10.4103/0972-124X.92587>
6. Ardekian L, Rosen DJ, Peled M, Rachmiel A, Machtei EE, el Naaj IA, et al. Primary gingival malignant melanoma. Report of 3 cases. *J Periodontol*. 2000;71:117–20. [PubMed] [Google Scholar]
7. Robertson GR, DeFiebre BK, Firtell DN. Primary malignant melanoma of the mouth. *J Oral Surg*. 1979;37:349–52. [PubMed] [Google Scholar]
8. Chaudhry AP, Hamed A, Gorlin KJ. Primary malignant melanoma of the oral cavity, a review of 105 cases. *Cancer*. 1958;11:923–8. [PubMed] [Google Scholar]
9. Freedman DM, Sigurdson A, Doody MM, Rao RS, Linet MS. Risk of melanoma in relation to smoking, alcohol intake, and other factors in a large occupational cohort. *Cancer Causes Control*. 2003; 14:847–57. [PubMed] [Google Scholar]
10. Holmstrom M, Lund VJ. Malignant melanoma of the nasal cavity after occupational exposure to formaldehyde. *Br J Ind Med*. 1991;48:9–11. [PMC free article] [PubMed] [Google Scholar]
11. Prasad, M. L., Patel, S. G., Shah, J. P., Hoshaw-Woodard, S., & Busam, K. J. (2011). Prognostic Significance of Regulators of Cell Cycle and Apoptosis, p16INK4a, p53, and bcl-2 in Primary Mucosal Melanomas of the Head and Neck. *Head and Neck Pathology*, 6(2), 184–190. doi:10.1007/s12105-011-0319-2
12. Rivera, R. S., Nagatsuka, H., Gunduz, M., Cengiz, B., Gunduz, E., Siar, C. H., Tsujigiwa, H., Tamamura, R., Han, K. N., & Nagai, N. (2008). C-kit protein expression correlated with activating mutations in KIT gene in oral mucosal melanoma. *Virchows Archiv*, 452(1), 27–32. <https://doi.org/10.1007/s00428-007-0524-2>
13. Rapidis, A. D., Apostolidis, C., Vilos, G., & Valsamis, S. (2003). Primary malignant melanoma of the oral mucosa. *Journal of Oral and Maxillofacial Surgery*, 61(10), 1132–1139. [https://doi.org/10.1016/S0278-2391\(03\)00670-0](https://doi.org/10.1016/S0278-2391(03)00670-0)
14. McLean N, Tighiouart M, Muller S. Primary mucosal melanoma of the head and neck. Comparison of clinical presentation and histopathologic features of oral and

- sinonasal melanoma. *Oral Oncol.* 2008; 44:1039–46.
15. Meleti M, Mooi WJ, Casparie MK, van der Waal I. Melanocytic nevi of the oral mucosa – No evidence of increased risk for oral malignant melanoma: An analysis of 119 cases. *Oral Oncol.* 2007;43:976–81.
 16. Lopez-Graniel CM, Ochoa-Carrillo FJ, Meneses-García A. Malignant melanoma of the oral cavity: Diagnosis and treatment experience in a Mexican population. *Oral Oncol.* 1999;35:425–30.
 17. Takagi M, Ishikawa G, Mori W. Primary malignant melanoma of the oral cavity in Japan. With special reference to mucosal melanosis. *Cancer.* 1974;34:358–70.
 18. Soman CS, Sirsat MV. Primary malignant melanoma of the oral cavity in Indians. *Oral Surg Oral Med Oral Pathol.* 1974;38:426–34.
 19. Pliskin ME, Mastrangelo MJ, Brown AM, Cister RP. Metastatic melanoma of the maxilla presenting as a gingival swelling. *Oral Surg Oral Med Oral Pathol.* 1976;41:101–4.
 20. Greene GW, Haynes JW, Dozier M, Blumberg JM, Bernier JL. Primary malignant melanoma of the oral mucosa. *Oral Surg Oral Med Oral Pathol* 1953; 6:1435-43. doi: 10.1016/0030-4220(53)90242-4. PMID: 13120118.
 21. Smyth AG, Ward-Booth RP, Avery BS, To EW. Malignant melanoma of the oral cavity- an increasing clinical diagnosis? *Br J Oral Maxillofac Surg.* 1993;31:230–5.
 22. Umeda M, Komatsubara H, Shigeta T, Ojima Y, Minamikawa T, Shibuya Y, et al. Treatment and prognosis of malignant melanoma of the oral cavity: Preoperative surgical procedure increases risk of distant metastasis. *Oral Surg Oral Med Oral Pathol Oral Radiol Endod.* 2008;106:51–7.
 23. Smyth AG, Ward-Booth RP, Avery BS, To Chidzonga MM, Mahomva L, Marimo C, Makunike-Mutasa R. Primary malignant melanoma of the oral mucosa. *J Oral Maxillofac Surg.* 2007;65:1117–20.
 24. Gupta, S., Tandon, A., Ram, H., & Gupta, O. (2015). Oral malignant melanoma: Report of three cases with literature review. *National Journal of Maxillofacial Surgery*, 6(1), 103. <https://doi.org/10.4103/0975-5950.168239>
 25. Mısır, A. F., Durmuşlar, M. C., Zerener, T., & Gün, B. D. (2016). Primary malignant melanoma. *Saudi Medical Journal*, 37(4), 446–449. <https://doi.org/10.15537/smj.2016.4.15017>
 26. Kumar, V., Vishnoi, J., Kori, C., Gupta, S., Misra, S., & Akhtar, N. (2015). Primary malignant melanoma of oral cavity: A tertiary care center experience. *National Journal of Maxillofacial Surgery*, 6(2), 167. <https://doi.org/10.4103/0975-5950.183856>
 27. Hamed Mohamed, K. E., & Abusin, H. (2016). Primary Melanoma of the Oral Mucosa: A Case Report and Review of Literature. *Journal of Clinical Case Reports*, 06(09), 353–356. <https://doi.org/10.4172/2165-7920.1000873>
 28. Jagadish Reddy, G., RajiniKanth, M., Sunil Kumar, D., RukminiSwathi, T., & Madhavi, A. (2015). Oral malignant melanoma. *Journal of Clinical and Diagnostic Research*, 9(1), 03. <https://doi.org/10.7860/JCDR/2015/10471.5496>

How to cite this article: Bhanji A, Desai S, Ladani P. Primary mucosal melanoma of oral cavity - case report. *Int J Health Sci Res.* 2021; 11(2): 214-219.
