

Non-Surgical Management of a Tooth with Endo-Perio Lesion: A Case Report

Aparna Tripathi¹, Nabila Ahmad², Kavita Negi³

¹Department of Conservative Dentistry and Endodontics, Post Graduate Institute of Dental Sciences, Rohtak, Haryana, India.

²Department of Periodontics, Post Graduate Institute of Dental Sciences, Rohtak, Haryana, India.

³Department of Orthodontics and dentofacial orthopaedics, Post Graduate Institute of Dental Sciences, Rohtak, Haryana, India.

Corresponding Author: Aparna Tripathi

ABSTRACT

The simultaneous involvement of pulpal problems and inflammatory periodontal disease can complicate diagnosis and treatment planning. Proper diagnosis is a determining factor in healing of such lesion. This case report describes a case of primary endodontic lesion which was managed with endodontic treatment that resulted in healing of soft and hard tissues observed at follow-up examinations.

Keywords: furcation, endodontic treatment, endo-perio lesion

INTRODUCTION

Healing of a combined endodontic and periodontal lesion depends on the elimination of both of the disease processes. In cases of combined endo-perio lesion, the endodontic therapy results in healing of the endodontic component while the prognosis of tooth would finally depend on the healing of the periodontal structures. Communication between pulpal and periodontal tissues can occur via the apical foramen, accessory canals, or exposed dentinal tubules, resulting in a bidirectional spread of infection ^[1, 2]. The endo-perio relationship was described by Simring and Goldberg ^[3]. Etiologic factors such as bacteria, fungi, and viruses as well as various contributing factors such as trauma, root resorptions, perforations, and dental malformations play an important role in the development and progression of such lesions. Many systems have been proposed for the classification of endodontic-periodontal lesions, with the most common being that described by Simon *et al.* in 2013 ^[4]. This classification is based on the initial

cause of the disease. In 2014, another classification system for endodontic-periodontal lesions was proposed based on the primary origin of disease and its secondary effects ^[2].

The main factors to take into account for treatment decision-making are pulp vitality and type and extent of periodontal defect. The differential diagnosis of endodontic and periodontal diseases can be challenging but a correct diagnosis has a vital importance so that appropriate treatment can be provided.

CASE REPORT

A 21-year-old female patient reported to the Department of Conservative Dentistry and Endodontics, Post Graduate Institute of Dental Sciences, Rohtak with the chief complaint of pus discharge and intermittent pain in lower right back tooth region for 6 months. Patient also gave history of a visit to a dentist for the same tooth 5 months back. Clinical examination revealed Grade 2 mobility, with a temporary filling placed in relation to tooth 46. An

intraoral sinus opening was seen on the lingual aspect in relation to the same tooth. On periodontal probing, normal probing depth was found. Radiographic examination revealed a pre-accessed tooth with well-defined periapical lesion along-with a radiolucency in the furcation region of 46. The sinus tract was traced using a no. 25 gutta-percha cone (Fig. 1). Radiograph revealed the sinus tract to be associated with the furcation of the tooth 46 (Fig. 2). Tooth was found to be non-vital after performing pulp vitality test. Endodontic treatment was administered in 2 visits. After proper cleaning and shaping a calcium hydroxide dressing was placed. After 7 days the sinus opening disappeared and mobility reduced to grade 1 mobility. After removing temporary filling and proper irrigation and removal of calcium hydroxide dressing, obturation was performed using cold lateral compaction and a permanent composite restoration was placed (Fig. 3).

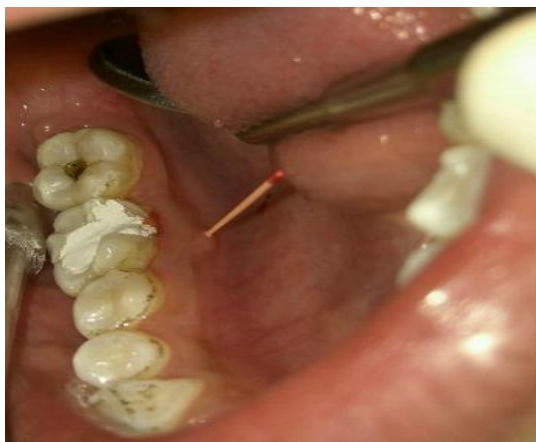

Fig. 1 Sinus tracing using gutta-percha cone

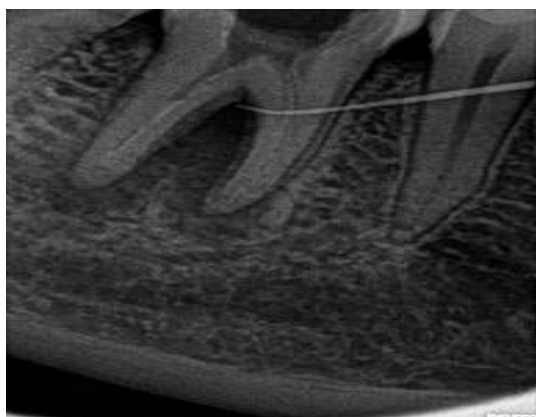


Fig. 2 sinus traced to the furcation region

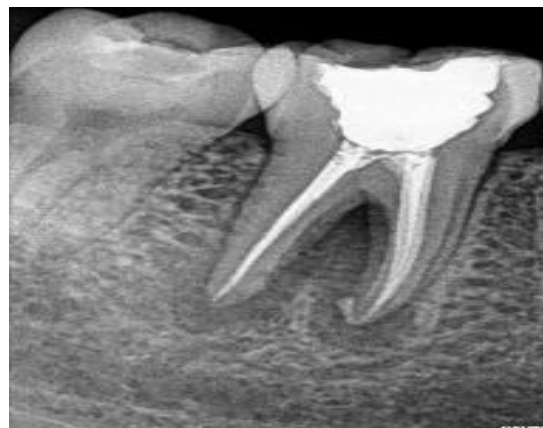

Fig. 3 post-obturation radiograph

FOLLOW-UP:

At 3 months follow up examination, the tooth was non-mobile and radiographic examination revealed healing lesion (Fig. 4). At 12 months follow up examination, radiograph revealed healed periapical lesion. Radiolucency in the furcation region has also disappeared (Fig. 5).

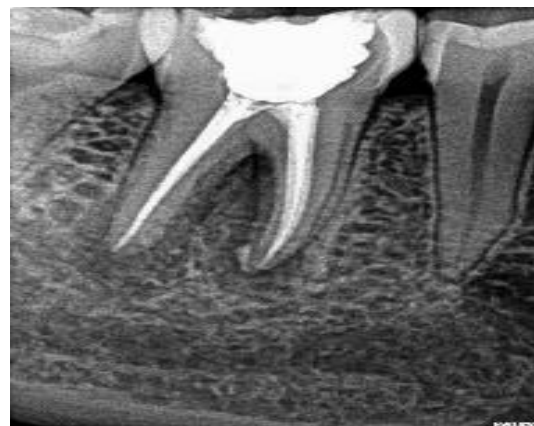

Fig. 4 radiograph at 3 months follow-up

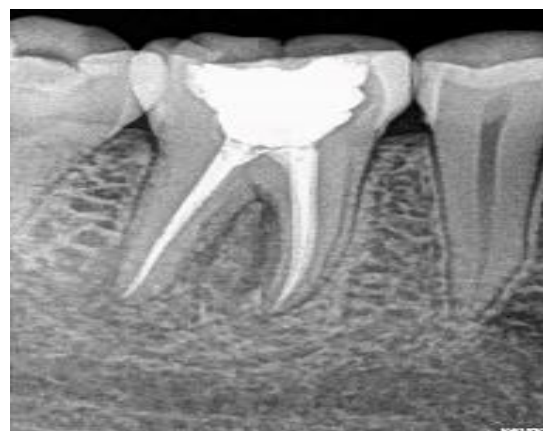

Fig. 5 radiograph at 12 months follow-up

DISCUSSION

Proper diagnosis is important to determine the appropriate treatment

modality and the long-term prognosis of endo-perio lesions. Diagnosis of primary endodontic disease and primary periodontal disease usually presents no clinical difficulty. The pulp vitality test is the first step for proper diagnosis. Although the vitality test does not reveal the histological status of the dental pulp, their ability to determine the pulpal status is quite satisfactory. The ability of vitality tests to detect non-sensitive reaction represented a necrotic pulp was reported as 89% with the cold test and 88% with the electrical test [5].

The infected root canals can elicit a chronic inflammatory reaction which drains through the sinus tracts. If any root cracks and fractures have been ruled out, healing of the periodontal tissues can be expected after endodontic treatment is performed. Thus, further treatment requirements should always be considered followed by an observation period of at least 3 months. Conversely, there has been a debate in the literature about the impact of the endodontic treatment on the healing potential of the periodontium. Some studies have been reported that endodontic treatment may cause an inhibitory effect on periodontal wound healing [6] while some of them [7, 8] demonstrated no significant effects. The possible influence of endodontic treatment on the healing response of furcation defects is related to the accessory canals and permeable areas of dentin and cementum. Accessory canals in the whole furcation area of molars are found in 30–60% of molars and predispose this area to be a zone of intense communication between pulpal and periodontal tissues [9]. These canals are mostly observed in the furcation area of mandibular molars [10].

In this case report, the cleaning and shaping of the root canals were performed in combination with irrigation using sodium hypochlorite. At follow-up examinations the

radiographic healing was observed with a reduction in tooth mobility

REFERENCES

1. Zehnder M, Gold SI, Hasselgren G. Pathologic interactions in pulpal and periodontal tissues. *J Clin Periodontol* 2002; 29:663-71.
2. Al-Fouzan KS. A new classification of endodontic-periodontal lesions. *Int J Dent* 2014;2014:1-7.
3. Simring M, Goldberg M. The pulpal pocket approach: retrograde periodontitis. *J Periodontol.* 1964;35:22–48.
4. Simon JH, Glick DH, Frank AL. The relationship of endodontic-periodontic lesions. *J Endod* 2013;39:e41-6.
5. Petersson K, Söderström C, Kiani-Anaraki M, Lévy G. Evaluation of the ability of thermal and electrical tests to register pulp vitality. *Endod Dent Traumatol.* 1999; 15:127–31.
6. Morris ML. Healing of human periodontal tissues following surgical detachment and extirpation of vital pulps. *J Periodontol.* 1960;31:23–6.
7. de Miranda JL, Santana CM, Santana RB. Influence of endodontic treatment in the post-surgical healing of human Class II furcation defects. *J Periodontol.*
8. Perlmutter S, Tagger M, Tagger E, Abram M. Effect of the endodontic status of the tooth on experimental periodontal reattachment in baboons: a preliminary investigation. *Oral Surg Oral Med Oral Pathol.* 1987;63:232–6.
9. Lowman JV, Burke RS, Pelleu GB. Patent accessory canals: incidence in molar furcation region. *Oral Surg Oral Med Oral Pathol.*
10. Gutmann JL. Prevalence, location, and patency of accessory canals in the furcation region of permanent molars. *J Periodontol.*

How to cite this article: Tripathi A, Ahmad N, Negi K. Non-surgical management of a tooth with endo-perio lesion: a case report. *Int J Health Sci Res.* 2021; 11(1): 265-267.
