

# Esthetic Laser Gingivectomy

S. Hajjaji<sup>1</sup>, A. Esghir<sup>1</sup>, H. Hajjami<sup>1</sup>, A. Boughzella<sup>1</sup>

<sup>1</sup>Dental Medicine Department, Farhat Hached Hospital, Tunisia

Corresponding Author: Sihem Hajjaji

## ABSTRACT

Gingivectomy is the surgical removal of gum tissue. This procedure is used to treat gum disease and to eliminate deep pockets resulting from the detachment of gums from the teeth, or for esthetic reasons.

Currently, gingivectomy is the most common procedure performed with dental lasers. All laser wavelengths can be used to precisely incise the gum for restorative, cosmetic and periodontal purposes. Rapid healing and reduced pain are frequently observed after gingivectomy and patients do not require periodontal dressings or sutures.

**Key Words:** esthetic, laser, gingivectomy, smile, surgery.

## INTRODUCTION

Nowadays, physical appearance is a constant preoccupation and the image we project conditions our relationship with society. This is why practitioners are observing a clear increase in cosmetic requests today. The main requests of patients concern the color, shape and state of their teeth which are partly conditioned by the state of the surrounding tissues.

Modern cosmetic dentistry therefore aims to create teeth with satisfactory proportions to each other, as well as a harmonious relationship between the teeth and the gums.

One of the procedures that guarantee the satisfaction of these objectives is gingivectomy. It is a surgical procedure that has benefited fully from new technologies in order to simplify surgery and optimize the esthetic result. Indeed, lasers (surgical lasers: Er-Yag, Co2, Nd-Yag, diodes) have made it possible to perform gingival or mucosal plasties which are subtle, perfectly controlled, without postoperative pain and whose healing is obtained in a few days, on soft tissues.

## Gingivectomy for Esthetic Purposes

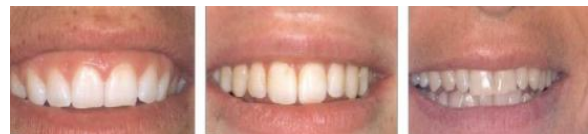

Fig.1 : smile lines respectively high, medium and low

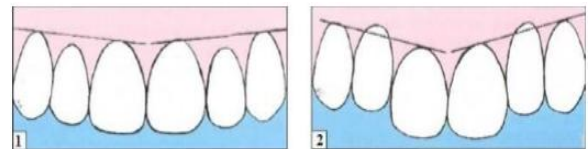


Fig.2 : examples of aesthetic (1) and unaesthetic (2) gumlines

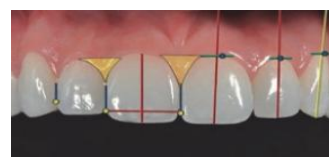


Fig.3 : Zeniths and axes of anterior teeth

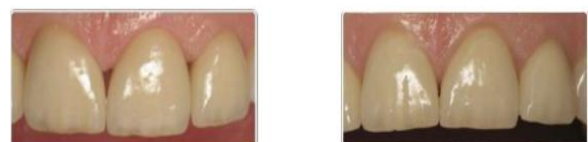

Fig.4 : absence of papilla around the 21 (left), and recovery to the physiological state (right)

Important considerations in terms of smile esthetics are the height/width ratios of clinical crowns, as well as the appearance

and shape of the gums involving the smile line (Fig. 1), the gingival line (Fig. 2), the gingival zeniths (Fig. 3), and the inter-dental papillae (Fig. 4). A remodeling of the gingival contours is sometimes necessary to improve the smile. It is actually a reshaping of the gum around the natural teeth (sometimes even prosthetic) for a better esthetic integration in the smile dynamics. However, it is sometimes difficult to make the patient accept an often major and painful surgical procedure to rearrange the soft tissues. Laser has made it possible to simplify these procedures and to increase their indications. It allows, indeed, for a simple and rapid reshaping of the marginal gingiva for an immediate esthetic result.

### Which Lasers for Cosmetic Gingivectomy?

Currently, gingivectomy is the most common procedure performed with dental lasers. All laser wavelengths can be used to precisely incise the gum for restorative, cosmetic and periodontal purposes. Surgical lasers (Er-Yag, Co2, Nd-Yag, diodes) can be used to perform fine gingival or mucosal surgeries, which are perfectly controlled, without postoperative pain and which heal within a few days. Only erbium lasers are indicated for procedures on both bone and gum. They are particularly effective for esthetic clinical crown lengthening in a very critical area without the need for a flap. The results are reproducible and spectacular: healing in a few days, absence of postoperative pain and stability over time.

### Requirements for an Esthetic Gingivectomy

- Hygiene index: The decision whether or not to perform a gingivectomy depends on the hygiene index. Poor hygiene limits the laser procedure.
- Assessment of the attached gingiva: Its height varies from one individual to another but also within the individual himself. It is between 0.5 and 8 mm and its thickness varies from 0.5 to 2 mm on the vestibular side. A height of attached

gingiva greater than 2 mm is necessary to consider a surgical procedure.

- Assessment of the biological space: The maintenance of the biological space is the most important parameter during gingivectomy because it gives the minimum distance to be respected between the alveolar bone crest and the edge of the sulcus. The biological space will be quantified with a periodontal probe (fig.5) and must therefore be greater than 3mm for any esthetic gingivectomy.
- Periodontal biotype assessment: The periodontal tissues may be more or less at risk for the planned surgical treatment procedure. It is therefore important to evaluate the biotype to ensure that the periodontal health is good after the treatment.

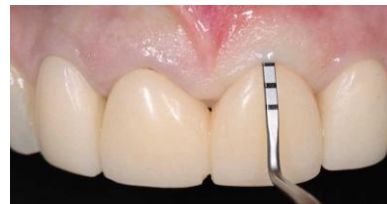

Fig.5: evaluation of the biological space

### Laser Surgical Protocol: Case Report

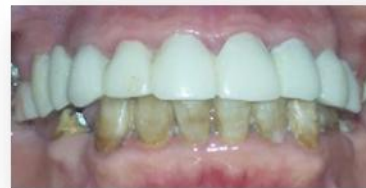

Fig.6: anterior provisional prosthesis : note the anesthetic aspect of the prosthetic crowns due to insufficient height of the teeth

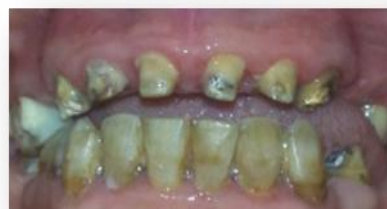

Fig.7: Removal of the temporary prosthesis showing short support teeth

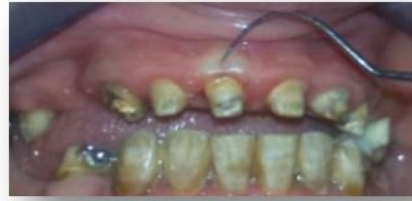
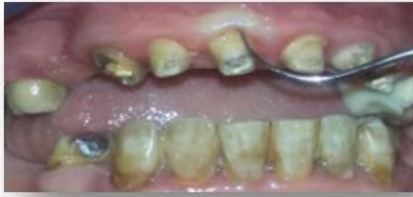
Fig.8 : preoperative evaluation of the biological space and the attached gingiva

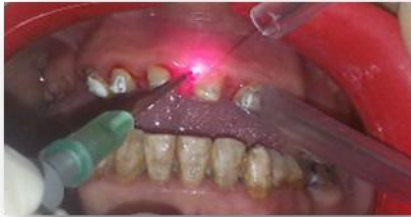

Fig.9 : application of the diode laser

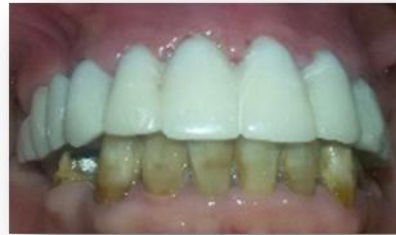

Fig.13 : new provisional prosthesis in place (note the clear increase in height of the prosthetic crowns and the improvement of the esthetic aspect of the prosthesis)

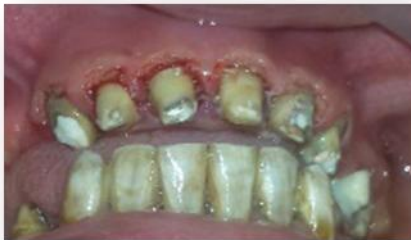

Fig.10: immediate postoperative status (note the excellent hemostasis)

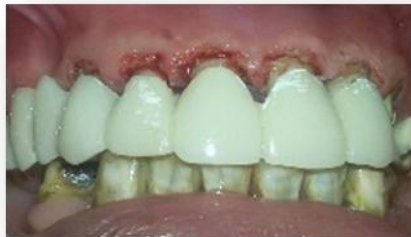

Fig.11: old temporary prosthesis in place (note the gain in height after gingivectomy)

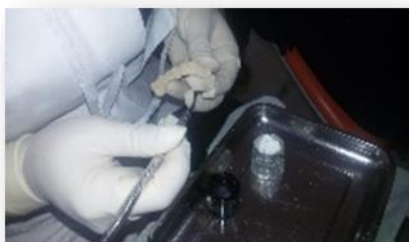

Fig.12: relining of the temporary prosthesis

The patient S.J., 45 years old, is not satisfied with her smile: her teeth are "small and square" (fig.6 and 7). She wanted to improve the esthetic aspect of her prosthesis. The choice was made to lengthen the clinical crowns using the 980 nm CW 2W diode laser. The clinical protocol is simple and painless. The first step is to evaluate both the attached gingiva and the biological space with a periodontal probe (fig.8); remember that a height of 2mm of attached gingiva and a biological space of at least 3mm are the only guarantees for the maintenance of periodontal health after gingivectomy (it is essential to have enough attached gingiva after laser surgery). It is also important to determine the amount of gingiva to be removed in order to obtain the desired length and coronal profile.

Anesthesia is not essential. However, in some patients, and in order to ensure their psychological comfort, a topical anesthesia of the concerned area can be applied.

With the diode laser set to 980 nm CW 2W, contouring of the maxillary incisors is started (fig.9). The laser energy is delivered in pulses (20 pulses per second), the practitioner works in contact mode while keeping the laser fiber in constant motion

around the tooth, which is essential to avoid tissue charring and deep damage. Hemostasis is controlled throughout the procedure thanks to the coagulation effect of the diode laser (fig.10).

The remains of the resected tissue were removed with sterile gauze moistened with saline solution. This procedure was repeated on all the prepared teeth that showed a significant gain in height at the end of the procedure (assessed after the old prosthesis was refitted) (fig.11).

The old prosthesis is then relined (Fig. 12) to reach the new prosthetic margin, and to help the gingiva heal and maintain itself in its new, more apical position. The placement of the new relined prosthesis shows a clear improvement of the esthetic aspect of the anterior restoration: the teeth have become longer and more refined (fig.13). Once again, the laser has significant advantages over traditional surgery with a scalpel:

- Immediate hemostasis and increased per-operative visibility.
- No per- or post-operative pain, thanks to the formation of a protein clot on the wound surface, which serves as a biological dressing and seals the sensory nerve endings.
- Sterilization of the site thanks to the bactericidal effect of the used laser.
- Rapid healing due to the photo-modulation effects of the laser, which helps to stimulate fibroblasts.

## CONCLUSION

Preprosthetic periodontal surgery is sometimes essential for the initiation of a quality prosthetic treatment. Because of certain limitations of conventional periodontal therapies, the use of lasers as an adjuvant or alternative means opens new horizons. Their use must be well defined and the indications for each of them are specific. They differ according to the nature of the tissue and the density of energy transmitted per unit area. Good results can only be obtained if laser radiation is used wisely, with the required knowledge. Laser

technology is gradually taking over from mechanical systems, and its future may be far-reaching.

**Acknowledgement:** None

**Conflict of Interest:** None

**Source of Funding:** None

## REFERENCES

1. Parker S. Laser regulation and safety in general dental practice. *Br Dent.* 2007; 202(9):523-32.
2. Johar K. *Fundamentals of laser dentistry.* Jaypee Brothers Medical Publishers 2011.
3. Romanos GE. The state of the science of lasers in dentistry. *The Canadian Journal of Dental Hygiene* 2012;46(1):20-21.
4. Brugnera Junior A, Garrini dos Santos AEC, Bologna AD, Christinna TCG, Ladarlado P. *Atlas of laser therapy applied to clinical dentistry.* Quintessence editora Ltda 2006.
5. Convissar RA. *Principles and Practice of Laser Dentistry.* Mosby Elsevier 2011.
6. Parker S. Verifiable CPD paper : laser-tissue interaction. *British dental journal* 2007;202(2):73-81.
7. Romanos G, Nentwig GH. Diode laser (980 nm) in oral and maxillofacial surgical procedures: clinical observations based on clinical applications. *J Clin Laser Med Surg.* oct 1999;17(5):193-7.
8. White JM, Goodis HE, Rose CL. Use of the pulsed Nd:YAG laser for intraoral soft tissue surgery. *Lasers Surg Med.* 1991;11(5):455-61.
9. Moritz A. al. : Oral Laser application, 2006;2:347-364.
10. Mirko P, Miroslav S, Lubor M. Significance of the Labial Frenum Attachment in Periodontal Disease in Man. Part 1. Classification and Epidemiology of the Labial Frenum Attachment. *J Periodontol.* déc 1974;45(12):891-4.
11. Rastegar S, Jacques SL, Motamedi M, Kim BM. Theoretical analysis of equivalency of high power diode laser and ND-YAG laser for coagulation of tissue: predictions for prostate coagulation. *SPIE* 1992;1646:150-160.
12. Wyman A, Duffy S, Sweetland HM, Sharp F, Rogers K. Preliminary evaluation of a



- new high power diode laser. *Lasers Surg Med* 1992;12:506-509.
13. Centty IG, Blank LW, Levy BA, et al. Carbon dioxide laser for the de-epithelialization of periodontal flaps. *J Periodontol* 1997;68:763-769.
  14. Folwaczny M, Aggstaller H, Hickel R. Anti microbial effects of 2.94 micron Er-YAG laser radiation on root surfaces: an in vitro study. *J Clin Periodontol* 2002;29:73-78.
  15. Shultz RJ, Harvey GP, Fernandez-Beros ME, Krishnamurty S, et al. Bactericidal effects of the neodymium-YAG laser: in vitro study. *Lasers Surg Med* 1986;6:445-448.
  16. Pacaro BC, Garehim WJ. The CO2 laser in oral and maxillofacial surgery. *J Oral Maxillofac Surg* 1983;41:725-728.
  17. Romanos G, Nentwig GH. Diode laser (980 nm) in oral and maxillofacial surgical procedures: clinical observations based on clinical applications. *J Clin Laser Med Surg* 1999;17:193-197.
  18. Sulewski JG. Historical survey of laser dentistry. *Dent Clin North Am* 2000;44:717-752.
  19. Coluzzi DJ. Laser assisted sulcular debridement. Featured wavelength: Nd-YAG. *Wavelengths* 2001;9:19.
  20. Arcoria CJ, Vitasek-Arcoria BA. The effects of low level energy density Nd-YAG irradiation on calculus removal. *J Clin Laser Med Surg* 1992;10:343-347.
  21. Jennet E, Motamedi M, Rastegar S, Frederickson C, Arcoria C, Powers JM. Dye-enhanced ablation of enamel by pulsed lasers. *J Dent Res* 1994;73:1841-1847.
  22. Tseng P, Liew V. The use of a Nd-YAG dental laser in periodontal therapy. *Aust Dent Assoc News Bull* 1991;Nov: 3-6.

How to cite this article: S. Hajjaji, A. Esghir, H. Hajjami et.al. Esthetic laser gingivectomy. *Int J Health Sci Res.* 2021; 11(10): 267-271. DOI: <https://doi.org/10.52403/ijhsr.20211035>

\*\*\*\*\*