

Proptosis: An Unusual Chief Complaint of Juvenile Nasopharyngeal Angiofibroma

Andrew Charles Gomez Junior¹, Mohamad Hazri Bin Hamal²

¹Resident trainee in Otorhinolaryngology, University Malaya Medical Center, Lembah Pantai, 59100, Kuala Lumpur, Malaysia

²Consultant Otorhinolaryngologist, Hospital Ampang, Jalan Mewah Utara, Pandan Mewah Ampang 68000 Selangor Darul Ehsan, Malaysia

Corresponding Author: Andrew Charles Gomez Junior

ABSTRACT

Juvenile nasopharyngeal angiofibroma is an uncommon, benign, fibrovascular tumor that almost exclusively affects adolescent males. We report a case of a 19 year old gentleman who presented to a tertiary center with gradual right proptosis and was diagnosed with a juvenile nasal angiofibroma.

Keywords:- Juvenile Nasopharyngeal Angiofibroma, Benign, Proptosis

INTRODUCTION

Juvenile nasopharyngeal angiofibroma is an uncommon, benign, fibrovascular tumor that almost exclusively affects adolescent males. [1] With their propensity to present with recurrent episodes of profuse epistaxis, these tumors are often a challenge for surgeons. In most cases, diagnosis is based on clinical grounds and does not require a tissue biopsy. The diagnosis can however be a challenge in cases where the characteristic symptoms of recurrent epistaxis and nasal obstruction are not present.

CASE REPORT

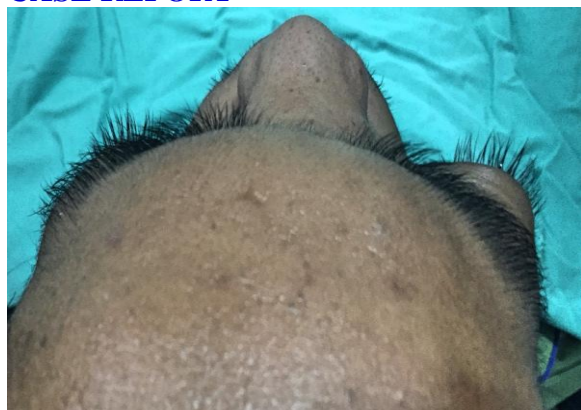

Figure 1

A 19 year old, gentleman was admitted with a chief complaint of right proptosis for 3 months duration. The patient also complained of right sided blurring of vision for one year, and 1 episode of right-sided epistaxis 2 months prior and frontal headache for the preceding 2 weeks. He denied a history of nasal blockage or neck swellings. Review of systems was unremarkable. On examination there was obvious right eye proptosis (Figure 1). Nasoendoscopy revealed a pink, fleshy mass occupying the right nasal cavity, pushing the nasal septum to the left. On the basis of the age of presentation and nasoendoscopic findings a contrast enhanced Computer tomography of the paranasal sinuses and brain was undertaken. This revealed an aggressive, highly vascular, nasal tumor within the epicenter of the nasal cavity (Figure 2) eroding the floor of the anterior cranial fossa and cribriform plates, bilateral sphenoid sinuses with intracranial and orbital extension. The mass obliterates the right pterygopalatine and bilateral sphenopalatine fossas. Magnetic resonance imaging with angiography showed intradural extension and the right maxillary

artery to be the primary feeding vessel. A definitive diagnosis of Juvenile nasopharyngeal Andrew-Fisch stage IVb was confirmed. Treatment options of

surgery and radiotherapy were discussed with the patient and patient was transferred to a tertiary center with interventional radiology services for further management.

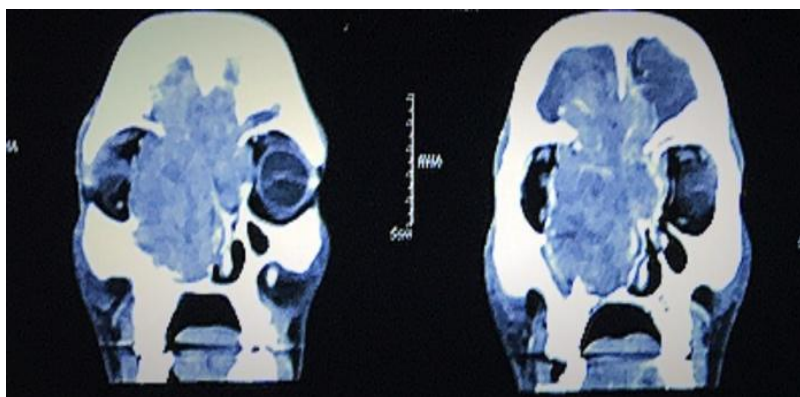


Figure 2

DISCUSSION

Atypical presentations of juvenile nasopharyngeal angiofibromas have been described in literature. These include those arising from the maxillary sinus, nasal septum, ethmoidal sinuses, middle turbinate, inferior turbinate and also those occurring outside the nasal cavity including the oral cavity and larynx. [4] These are termed extranasopharyngeal angiofibromas. Tang et al in a review of 13 patients reported that all (100%) presented with recurrent epistaxis with associated symptoms including nasal obstruction (76.9%), nasal discharge (76.9%), hyposmia (61.5%), snoring (38.5%), headache (23%) and facial swelling (7.7%). [3]

Ghosh et al also reported in his review of 37 patients that recurrent epistaxis was seen in all patient while proptosis was an associated symptom only noted in 5 percent of cases. [1] Proptosis as chief complaint as in this case is rare. It is usually an associated symptom that signifies intraorbital disease involvement in advanced cases.

Diagnosis is confirmed with imaging studies such as Computer tomography studies or Magnetic resonance imaging. [3,5] Radiological features include pterygo-palatine fissure expansion with bowing of the posterior maxillary wall, erosion of the floor of the sphenoid sinus and pterygoid

plates. [5] Surgical excision, either endoscopically or using an open method, is the main treatment modality in Treating Juvenile nasopharyngeal angiofibromas however radiotherapy may be employed in advanced cases. [4]

CONCLUSION

The associated symptoms such as proptosis and headaches in an adolescent male, even if as a presenting complaint should raise a suspicion of juvenile nasopharyngeal angiofibroma.

REFERENCES

1. Ghosh, B., Saha, S., Chandra, S., Nandi, T. K., & Bera, S. P. (2003). Juvenile nasopharyngeal angiofibroma-three years experience. *Indian J Otolaryngol Head Neck Surg Indian Journal of Otolaryngology and Head & Neck Surgery*, 55(4), 228-233
2. Oliveira, J. A., Tavares, M. G., Aguiar, C. V., Azevedo, J. F., Sousa, J. R., Almeida, P. C., & Gomes, E. F. (2012). Comparison between endoscopic and open surgery in 37 patients with nasopharyngeal angiofibroma. *Brazilian Journal of Otorhinolaryngology*, 78(1), 75-80
3. Tang, I. P., Shashinder, S., & Narayanan, P. (2009). Juvenile nasopharyngeal angiofibroma in a tertiary centre: Ten-year experience. *Singapore Med J*, 50(3), 261-264

4. Godoy, M. D., Bezerra, T. F., Pinna, F. D., & Voegels, R. L. (2014). Complications in the endoscopic and endoscopic-assisted treatment of juvenile nasopharyngeal angiofibroma with intracranial extension. *Brazilian Journal of Otorhinolaryngology*, 80(2), 120-125
 5. Ramos, H. F., Takahashi, M. T., Ramos, B. F., Gomes, M. D., & Sennes, L. U. (2011). Juvenile Nasopharyngeal Angiofibroma with intradural extension. *Brazilian Journal of Otorhinolaryngology*, 77(5), 677-677
- How to cite this article: Junior ACG, Hamal MHB. Proptosis: an unusual chief complaint of juvenile nasopharyngeal angiofibroma. *Int J Health Sci Res.* 2020; 10(8):284-286.
