

# Diffuse Lipomatosis of Thyroid Masquerading as Nodular Goitre

Meenu Gill<sup>1</sup>, Gauri Munjal<sup>2</sup>, Pooja Pawaria<sup>3</sup>, Zeany Cheran Momin<sup>3</sup>,  
Sumiti Gupta<sup>1</sup>, Bharti Saklani<sup>3</sup>, Rajeev Sen<sup>4</sup>

<sup>1</sup>Professor, <sup>2</sup>Senior Resident, <sup>3</sup>Junior Resident, <sup>4</sup>Sr. Professor & Head,  
Dept. of Pathology, Pt. B. D. Sharma PGIMS, Rohtak, Haryana, India

Corresponding Author: Zeany Cheran Momin

## ABSTRACT

Diffuse thyroid lipomatosis is an exceedingly rare histopathological condition of thyroid classically characterized by diffuse swelling and fatty infiltration within the thyroid stroma. We report a case of 40 year old female who presented with a midline swelling in neck since 7 years with a recent history of compressive symptoms. On evaluation, goitre of thyroid gland was revealed on computed tomography. She underwent subtotal thyroidectomy and the final diagnosis of diffuse thyroid lipomatosis was confirmed based on histopathology.

**Keywords:** thyrolipoma; histopathology; goiter; neck swelling; lipomatosis; thyroid.

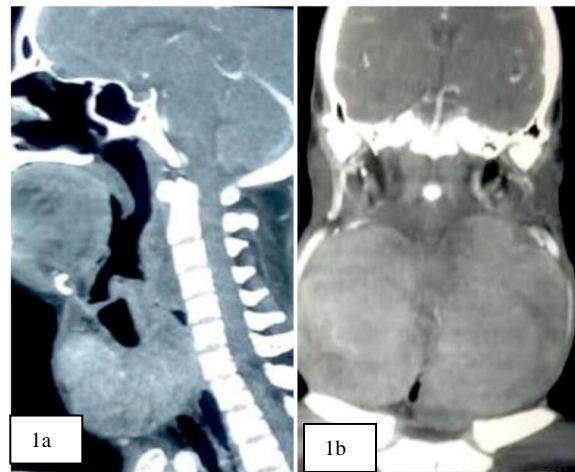
## INTRODUCTION

Thyroid lipomatosis is defined as a progressive enlargement of thyroid gland by diffuse infiltration of mature adipose tissue intermixed with follicles and lack of encapsulation. [1] It is an extremely rare condition and the first ever case was reported by Dhayagude in 1942. [2] We report a case of thyrolipomatosis in a 40 year old patient presenting with respiratory distress.

## CASE REPORT

A 40 year old female patient presented with a history of diffuse midline swelling for the past 7 yrs. With recent increase in the size of swelling, she developed dysphagia, dyspnoea and was admitted in emergency with respiratory distress since 2 days. There were no complains of fever, palpitation, tachycardia or weight loss. Thyroid function tests were within normal limits. Plain radiographs of the chest were unremarkable. Computed tomography scan revealed goitrous

enlargement of thyroid gland (Figure-1a and 1b).



**Figure 1:**-1a and 1b- Pre-operative computed tomography scans showing diffuse enlargement of both the lobes of thyroid gland including the isthmus revealing heterogeneous enhancement and no obvious cystic/necrotic component.

Fine needle aspiration cytology (FNAC) was performed in which 10 ml colloid admixed with blood was obtained and was inconclusive. A clinical diagnosis of colloid goitre with tracheal compression was made and subtotal thyroidectomy was

performed. We received thyroidectomy specimen weighing 550gm, comprising of right and left lobe of thyroid measuring 12x7x5 cm and 10x6x6 cm respectively with attached isthmus. The external surface was encapsulated, nodular and the cut surface was tan brown with microcystic change (Figure-2).

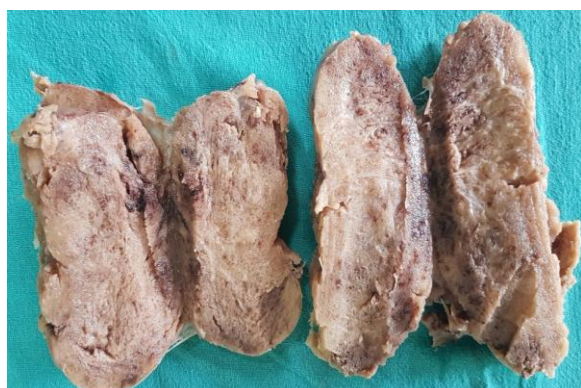


Figure 2: Gross photograph of thyroidectomy specimen showing both right and left lobes with tan brown microcystic change on the cut surface

Microscopically, histological sections from various areas revealed similar morphology comprising of colloid filled thyroid follicles lined by cuboidal cells. The interfollicular stroma showed diffuse and extensive infiltration by mature adipose tissue. There was no evidence of hyperplasia, follicular destruction, lymphocytic infiltrate, amyloid deposition, adenoma or any focus of atypia (Figure-3a and 3b).

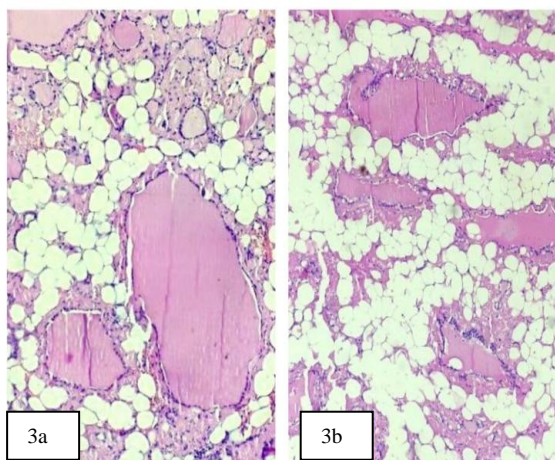


Figure 3: 3a and 3b- Photomicrographs showing histopathological findings: colloid filled thyroid follicles lined by cuboidal cells and interfollicular stroma showing diffuse and extensive infiltration by mature adipose tissue. (H&E, X400)

A diagnosis of diffuse lipomatosis of thyroid gland was rendered based on these findings.

## DISCUSSION

Adipose tissue can be seen in parathyroid, thymus, salivary gland, breast or pancreas. However, its presence in thyroid gland is unusual. [3] Few adipocytes may be found near the capsule, in the perivascular location or in the connective tissue septa. [3,4]

Clinically, it mostly presents as a diffuse enlargement in the anterior cervical region. A large proportion of patients present with hyperthyroidism while others are euthyroid. In our case, the condition of the patient was euthyroid.

Several theories have been proposed to explain the pathophysiology of this condition:

- 1) Trites et al proposed that thyroid arises from primitive foregut and the presence of these lesions suggest a disturbance in development of primitive foregut. [5]
- 2) Schroder et al suggested that adipose tissue may be a result of metaplasia of stromal fibroblasts due to tissue hypoxia or senile involution. [6]
- 3) Chesky et al and other authors have attributed the lesions to the simultaneous inclusion of fat with striated muscle in thyroid gland during embryogenesis before the development of thyroid capsule. [7]
- 4) Lau et al suggested a possible relationship between diffuse lipomatosis and loss of expression of protein succinate dehydrogenase – B subunit in the follicular or adipose cells. [8]

The differential diagnosis of presence of mature adipose tissue in the thyroid include heterotopic nests of adipocytes, diffuse lipomatosis, adenolipoma, amyloid goitre, lymphocytic thyroiditis, intrathyroidthymic or parathyroid lipoma, encapsulated papillary carcinoma and liposarcoma. [3]

Thyrolipoma is a well circumscribed, encapsulated nodule composed of thyroid follicles admixed with mature adipose tissue

while lipomatosis of thyroid is a diffuse process. [1,9] Similarly, its diffuse nature differentiates it from heterotrophic nests of adipocytes located mainly in the subcapsular areas. [1,2] Amyloid goitre which can also contain fat cells can be distinguished based on special stain and polarising microscopy. [1] Fat infiltration can be seen in lymphocytic thyroiditis. [10] Parathyroid lipoma should also be considered as a differential diagnosis wherein lobulated adipose tissue is present in the stroma with follicular formations of parathyroid chief cells. [1]

Our case highlights the importance of evaluation of patients with adipose components in the thyroid in order to exclude other conditions that present as diffuse enlargement of the gland, particularly neoplastic.

## CONCLUSION

Diffuse thyroid lipomatosis is a rare entity of unknown etiology and this case point towards significance of including it in the differential diagnosis of a patient presenting with goitre.

## Conflict of interest

The authors declare that there is no conflict of interest regarding publication of this paper.

## REFERENCES

1. Hijazi DM, Addas FA, Alghanmi NM, et al. Giant goiter secondary to rare diffuse thyrolipomatosis. *Am J Case Resp.* 2018;19: 808-11.
2. Ge Y, Luna MA, Cowan DF, et al. Thyrolipoma and thyrolipomatosis: 5 case reports and historical review of the literature. *Ann DiagnPathol.* 2009;13:384-9.
3. Gupta R, Arora R, Sharma A, et al. Diffuse lipomatosis of the thyroid gland: A pathologic curiosity. *Indian J Pathol Microbiol.* 2009; 52(2):215-6.
4. Demirpolat G, Guney B, Savas R, et al. Radiologic and cytologic findings in as case of Thyrolipoma. *Am J Neuroradiol.* 2002; 23:1640-1.
5. Trites AE. Thyrolipoma, thymolipoma and pharyngeal lipoma: A syndrome. *Can Med Assoc J.* 1996; 95: 1254-9.
6. Schroder S, Bocker W. Lipomatous lesions of the thyroid gland: A review. *Appl Pathol.* 1985;3:140-9.
7. Chesky VE, Dreese WC, Hellwig CA. Adenolipomatosis of the thyroid. *Surgery.* 1953;34:38-45.
8. Lau E, Freitas P, Costas J, et al. Loss of mitochondrial SDHB expression: What is its role in diffuse thyroid lipomatosis? *HormMetab Res.* 2015;47:165-7.
9. Kadivar M, KheirkhahRahimabad P, Salarinejad S. Prominent cold nodule in multinodular goiter revealed to be thyrolipoma: A case report. *Iranian J Pathol.* 2016;11(5):456-9.
10. Sarris AB, Santos MA, da Silva RA, et al. Adipose metaplasia of the thyroid associated with Hashimoto's thyroiditis with nodular hyperplasia and oncocytic cells adenoma: case report and literature review. *J Bras Pathol Med Lab.* 2018;54(2):105-8.

How to cite this article: Gill M, Munjal G, Pawaria P et.al. Diffuse lipomatosis of thyroid masquerading as nodular goitre. *Int J Health Sci Res.* 2020; 10(6):239-241.

\*\*\*\*\*