

Phaeohyphomycosis and Chromoblastomycosis: A Diagnostic Dilemma

Akanksha Gupta¹, M. L. Yadav², Priyanka Goyal¹, Shreya Agarwal¹,
Suvarna Mathur¹

¹Department of Pathology, Mahatma Gandhi Medical College and Hospital, Jaipur, Rajasthan, India

²Professor and Head of Department, Department of Pathology, Mahatma Gandhi Medical College and Hospital, Jaipur, Rajasthan, India

Corresponding Author: Akanksha Gupta

ABSTRACT

Introduction: Phaeohyphomycosis is a rare fungal infection of the skin and subcutaneous tissue caused by melanin-producing fungi i.e. dematiaceous fungi. They are sometimes indistinguishable from a condition called Chromoblastomycosis, commonly seen in tropical countries.

Case History: A 46-year old male presented with a gradual increase in swelling associated with discharge and bleeding from the lesions over right great toe the last 10 months. After 8 months, he developed another similar swelling over the left leg. Surgical resection was done and tissue was sent for histopathology.

Histopathological examination revealed marked infiltration by acute and chronic inflammatory cells with the formation of microabscesses containing a large number of pigmented round to oval cells suggestive of the dematiaceous fungal organisms.

Discussion: Phaeohyphomycosis is caused by fungi of genus *Alternaria*. *Bipolaris*, *Cladophialophora*, *Cladosporium*, *Exophiala*, *Fonsecaea*, *Phialophora*, etc. They have a wide range of presentations. Histopathological examination is usually diagnostic for chromoblastomycosis. Masson-Fontana staining for melanin confirms their presence. Fungal culture can be done for exact species identification.

Conclusion: Diagnosing Phaeohyphomycosis and Chromoblastomycosis is a dilemma for clinicians. Detailed clinical history and histopathology with fungal culture for speciation help in accurately diagnosing Phaeohyphomycosis.

Keywords: Phaeohyphomycosis, Chromoblastomycosis.

INTRODUCTION

Phaeohyphomycosis is a rare fungal infection of the skin and subcutaneous tissue, caused by melanin-producing fungi i.e. dematiaceous fungi. The clinicopathological picture of these fungi infections varies from localized abscess to systemic infections. They are sometimes indistinguishable from a condition called Chromoblastomycosis, commonly seen in tropical countries. Phaeohyphomycosis usually occurs in persons with decreased host immunity, although few cases have been reported in apparently

immunocompetent patients. Due to similar clinical presentations, it is very difficult to differentiate these two clinical entities and thus remains a diagnostic dilemma.

CASE PRESENTATION

A 46-year old male presented with a gradually increasing swelling associated with discharge and bleeding over the right great toe for the last 10 months. 2 months back, he developed another similar swelling over the left leg. There was no history of antecedent trauma, arthropod bite, immunosuppression, family history or

contact with a person with similar lesions or any difficulty in doing daily activities. Surgical resection was done and tissue was sent for histopathology.

Biopsy 1. Skin punch biopsy- Section shows skin and underlying tissue, the epithelium shows hyperplasia with hyperkeratosis (Figure 1). There is marked infiltration by acute inflammatory cells with the formation of microabscess (Figure 2) showing round brown colored thick-walled fungal organisms. Morphology is suggestive of chromoblastomycosis.

Biopsy 2. Growth left leg- Sections show skin and underlying tissue showing marked infiltration by acute and chronic inflammatory cells with the formation of microabscesses. The microabscesses also contain a large number of pigmented round to oval cells suggestive of a dematiaceous fungal organism. Some areas also show small septate hyphae suggestive of phaeohyphomycosis.

PAS stain- showed septate hyphae (Figure 3)

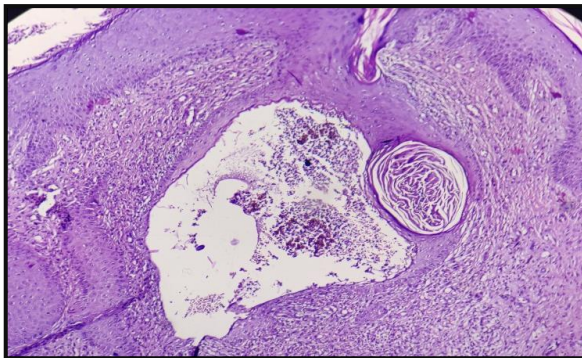


Figure 1.H&EX10 Epithelium shows hyperplasia with hyperkeratosis and thick walled fungal organism

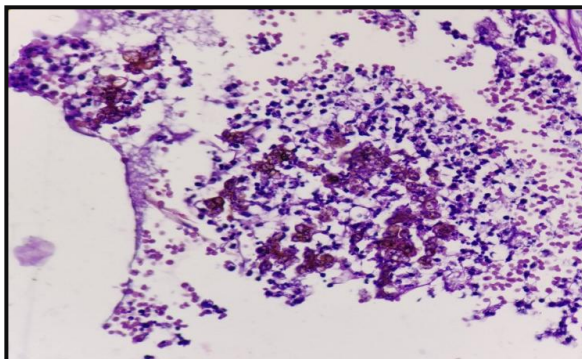


Figure 2.H&E x 40 Microabscess showing round brown colored thick walled fungal organism

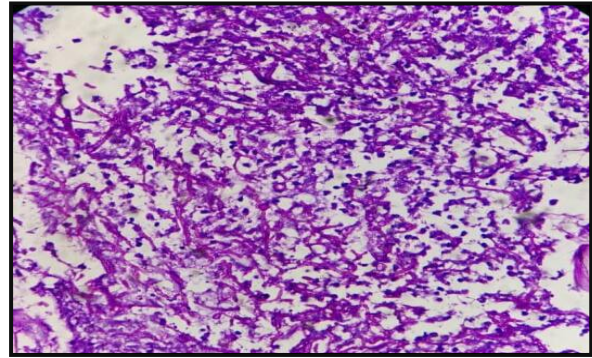


Figure 3. PAS X40 small septate hyphae

DISCUSSION

Phaeohyphomycosis is caused by fungi of genus *Alternaria*, *Bipolaris*, *Cladophialophora*, *Cladosporium*, *Exophiala*, *Fonsecaea*, *Phialophora*, etc.¹ They have a wide range of presentations from subcutaneous nodules or abscesses, invasive sinusitis, keratitis, mycotic arthritis, brain abscess to disseminated infections. Laboratory diagnosis comprises the segregation of fungal hyphae on potassium hydroxide mounts and culture on Sabouraud's dextrose agar². Histopathologically, the lesions show brown-walled septate hyphae or yeast or a combination of both in tissue. Chromoblastomycosis was confirmed by the presence of round, brown, thick-walled sclerotic bodies, which are pathognomonic for this disease³. The Fontana-Masson stain (specific for melanin), PAS and Gomori methenamine silver stains can be used to confirm the diagnosis. Histopathological examination is usually diagnostic from chromoblastomycosis, showing septate, brownish hyphae or yeast-like cells, due to high melanin content and absence of medlar /copper-penny bodies in the subcutaneous tissue. In the presence of only yeast cells with the absence of septate brownish hyphae, it becomes difficult to distinguish phaeohyphomycosis from chromoblastomycosis. Culture for the exact typing of fungus can be done.

CONCLUSION

Diagnosing Phaeohyphomycosis and Chromoblastomycosis is a dilemma for clinicians. Detailed clinical history, absence of medlar bodies on histopathology and a fungal culture for speciation helps in accurately diagnosing Phaeohyphomycosis.

REFERENCES

1. Sanjay G. Revankar. Phaeohyphomycosis. Infectious Diseases MSD Manual Professional Edition 2017;1-2.
2. Aditi Chhonkar, Deepti Kataria, Swagata Tambe, Chitra S. Nayak et. Three rare cases of cutaneous phaeohyphomycosis. Indian Journal of Plastic Surgery 2016;2:271-274.
3. Claudio Guedes Salgado , Jorge Pereira da Silva, Moisés Batista da Silva . Cutaneous diffuse chromoblastomycosis. Lancet Infect Dis 2005; 5: 528.
4. Sybren de Hoog, Daniel Wagner C. L. Santos, Claudio Guedes Salgado, Vania

Aparecida et al. Chromoblastomycosis. Clinical Microbiology Reviews January 2017; 30 (1):233-276.

5. Sanjay G. Revankar, Jan E. Patterson, Deanna A. Sutton, Renee Pullen, Michael G. Rinaldi. Disseminated Phaeohyphomycosis: Review of an Emerging Mycosis. Clinical Infectious Diseases 2002;34:467-76.
6. Flavioqueiroztelles, Phillippeesterre, MaigualidaPerez-Blanco, Roxana g Vitale, Claudio GuedesSalgado. Chromoblastomycosis: an overview of clinical manifestations, diagnosis and treatment. Medical Mycology February 2009; 47: 3 -15.

How to cite this article: Gupta A, Yadav ML, Goyal P et.al. Phaeohyphomycosis and chromoblastomycosis: a diagnostic dilemma. Int J Health Sci Res. 2020; 10(6):162-164.
