

## Asthma Mimic- Not to Be Missed

Manisha Bhardwaj<sup>1\*</sup>, Rajesh Bhawani<sup>2\*\*</sup>, Komal Gharsangi<sup>1\*\*</sup>,  
Pratibha Himral<sup>3\*\*</sup>, Deepak Aggarwal<sup>3\*\*\*</sup>, Jitender Thakur<sup>4\*\*</sup>

<sup>1</sup>Assistant Professor, <sup>2</sup>Professor & Head, <sup>3</sup>Associate Professor, <sup>4</sup>Senior Resident,

<sup>\*</sup>Department of Pulmonary Medicine, <sup>\*\*</sup>Department of Internal Medicine,

Shri Lal Bahadur Shastri Medical College and Hospital, Mandi, Himachal Pradesh - 15008

<sup>\*\*\*</sup>Dept. of Pulmonary Medicine, Government Medical College & Hospital, Sector 32, Chandigarh - 160030

Corresponding Author: Rajesh Bhawani

### ABSTRACT

Asthma is one the most common cause of breathlessness and wheezing in non smoker females. However all that wheeze is not asthma. We present a case of middle age female presented with similar complaints but turned out to be cancer. Adenoid cystic cancer is the second most common primary tracheal tumor with a rare occurrence. It poses a diagnostic challenge as it mimics asthma because of its slow progression and local recurrence. The key factor needed for successful diagnosis is to be familiar with similar conditions.

**Key words:** asthma, mimics, adenoid cystic cancer, diagnostic challenge.

### INTRODUCTION

Asthma is a common respiratory illness encountered in clinics on daily basis. It affects 1-18% of population in different countries. It is a chronic airway inflammatory disease and is defined by respiratory symptoms like cough, breathlessness, chest tightness, and wheezing that are variable with respect to time and intensity. Further documentation of variable airflow limitation with bronchodilator reversibility on spirometry consolidates the diagnosis. Being a heterogeneous disease it has variable phenotypic presentations like allergic, non-allergic, late onset and associated with obesity. Chronic asthmatics can also develop persistent airflow limitation like chronic obstructive airway disease (COPD) and post tubercular airway disease.<sup>1,2</sup>

Allergic asthma is the most easily recognised phenotype. These patients usually have similar complaints since childhood and family history of allergic diseases like rhinitis, skin and drug allergy. They show eosinophilic airway

inflammation and respond well to inhaled corticosteroids. However if there a absence of typical symptoms, poor or no response to therapy and frequent emergency visits, re-assessment is of paramount importance.<sup>1-4</sup>

A variety of benign diseases masquerades asthma. Cardiac failure, vocal cord dysfunction/ abnormalities, post nasal drip, congenital heart disease, gastroesophageal reflux disease and adverse reactions to drugs like aspirin and ACE inhibitors can present with cough and dyspnea simulating asthma. Pulmonary mimics include COPD, allergic bronchopulmonary disease, bronchiolitis, cystic fibrosis, obstructive sleep apnea, and bronchiectasis. Primary tracheal tumors especially slow growing adenoid cystic cancer isa rare cause of chronic respiratory symptoms in young patients which can be misinterpreted.<sup>3-5</sup>

### CASE HISTORY

A 45 year old non smoker female presented to respiratory clinic with difficulty in breathing, mild fever and

hoarseness of voice since 10 days. There was no sore throat, difficulty in swallowing and blood in sputum. She was non diabetic, non hypertensive and had no past history of pulmonary tuberculosis. She had similar complaints on-off since 5 yrs for which she was treated with inhaled bronchodilators, corticosteroids, leukotriene modifiers and theophylline by private practitioner. She reported poor response to treatment and frequent hospital visits for worsening symptoms. She was admitted in the ward and her diagnosis was reevaluated. Detailed history was taken to reconfirm diagnosis. She denied complaints suggestive of atopy and had no pets. Gastroesophageal reflux, foreign body aspiration and illicit drug use was not reported. She was a homemaker with no occupational exposure to toxic substances. There was no significant history of surgical illness, prolonged immobilisation and weight loss. Family history of malignancy was ruled out. She was never put on invasive ventilation for previous exacerbations.

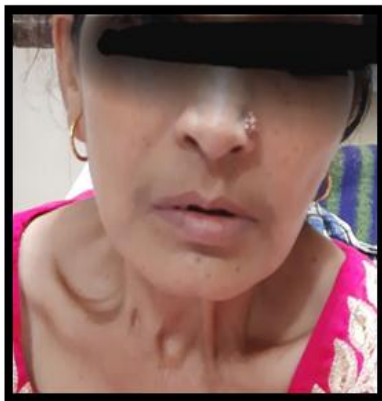


Figure 1: Patient with stridorous breathing.

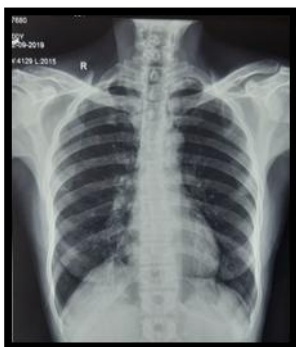

Figure 2: Chest X ray-grossly normal.

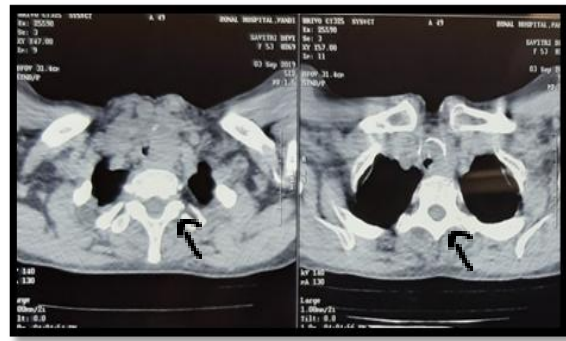

Figure 3: CECT thorax- upper tracheal mass with marked luminal compromise.

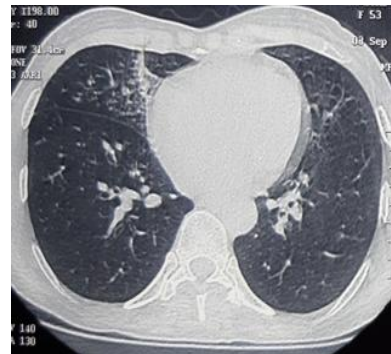

Figure 4: CT thorax-Right middle lobe air space opacity.

On examination, she had mild fever. There was visible difficulty in breathing with use of accessory muscles and inspiratory stridor (Fig 1). There were no palpable lymph nodes or visible swelling in neck. Heart sounds were normal except for tachycardia. Her abdominal and neurological examination was unremarkable. ENT examination showed no abnormality. Indirect laryngoscopy showed bilateral vocal cords normal in appearance and equally mobile. Her routine blood investigations revealed no eosinophilia and Arterial blood gases was unremarkable. Sputum for geneXpert was negative for mycobacteria and culture revealed normal oral flora. Serological tests ruled out ABPA and vasculitis. An urgent chest X ray was grossly normal (figure 2). Contrast enhanced computed tomography(CECT) of neck and thorax revealed a moderately enhancing isodense lesion measuring 18\*19\*28 mm in size in upper part of trachea at level of T1 vertebral body with marked luminal narrowing and right middle lobe consolidation( figure 3 and 4). CECT abdomen and pelvis was normal. Pulmonary

function test revealed obstruction with possible restriction (forced expiratory volume in 1 sec FEV1/ forced vital capacity FVC 57.2, FEV1 0.83L(42% of predicted) and FVC 1.45L (62% of predicted) with blunting of inspiratory curve on flow volume loops. Flexible bronchoscopy showed growth 3 cm below true vocal cord with circumferential narrowing of 70-80%. The length of tracheal stenosis was 4-5 cm and distal tracheal tree was normal. On histopathological examination of biopsy sample, findings were suggestive of adenoid cystic cancer. She underwent tracheal stenting for imminent respiratory compromise at higher center and is on adjuvant radiotherapy.

## DISCUSSION

Wheezing and breathlessness are suggestive of asthma but lack specificity. Various conditions like gastroesophageal reflux disease, congestive heart failure, retrosternal goiter, foreign body aspiration, vocal cord dysfunction/ abnormalities have similar presentation.<sup>3,4</sup> Tracheal tumors are uncommon asthma masquerade and pose diagnostic challenge. So it is wise that diagnoses are reconfirmed and mimics ruled out as a protocol. Rigorous history taking and meticulous physical examination is helpful. Psychological component needs to be explored as well. Thorough ear nose throat (ENT) examination, Indirect laryngoscopy, imaging especially CECT neck and chest, pulmonary functions tests and serological investigations are useful tools to detect lesions early. Common asthma mimics that are often overlooked can be easily ruled out if we are aware of these entities.

Adenoidcystic carcinoma(ACC) is a malignant salivary gland tumor of tracheobronchial tree with rare occurrence of 0.1%. It is second to mucoepidermoid type. It usually presents in fourth- fifth decade and male: female ratio is equal. It is usually not associated with smoking.<sup>5</sup> It mainly involves central airways and generally cause circumferential thickening

leading luminal compromise simulating upper airway obstruction. The patient can complain of coughing, shortness of breath, stridor and change of voice. Repeated episodes of lower respiratory tract infections can occur owing to impaired drainage of secretions post obstruction. It lacks specific clinical characteristics and has indolent course. So it can be mistaken with benign diseases like asthma and tuberculosis like in this case.<sup>5-7</sup> It is a non encapsulated tumor and commonly spreads by direct extension and submucosal or perineural invasion. Lymph node and lung metastasis is uncommon. Chest X ray has limited value because it involves central airways and can be overlapped by bone shadow and mediastinal tissue. Here computed tomography of neck and chest can prove useful tool to detect early lesions. Similarly in this patient, CECT neck and chest revealed tracheal tumor and prompted further investigations. Search of literature revealed that surgery is the mainstay therapy. Surgical resection with end to end anastomosis followed by radiotherapy is the favoured treatment option in localized disease. If tumor is unresectable, medically inoperable and for palliative intention, tracheal stenting is done to prevent airway occlusion. Adjuvant radiotherapy gives prolonged periods of remission.<sup>6-8</sup>

## CONCLUSION

Adenoid cystic cancer is a rare slow growing malignancy of tracheobronchial tree. It can be misinterpreted as adult onset asthma leading to delay in definitive treatment. CT thorax can detect early airway lesions. Awareness and suspicion of asthma mimics can prove life saving especially in atypical presentation and poor response to therapy.

## REFERENCES

1. Chung KF, Wenzel SE, Brozek JL, Bush A, Castro M, Sterk PJ, et al. International ERS/ATS guidelines on definition, evaluation and treatment of severe asthma. *EurRespirJ.* 2014; 343-73.

2. G Alina, D Ahn, Bernstein JA .Confounders of severe asthma: diagnosis to consider when asthma symptoms persist despite optimal therapy. *World Allergy Organ J.* 2018; 11: 29.
  3. King CS, Moore LK. Clinical asthma syndromes and important asthma mimics. *Respir Care.* 2008;53: 568–82.
  4. Bousquet J, Mantzouranis E, Cruz A.A, Ait-Khaled N, Baena-Cagnani CE, Bleecker ER et al. Uniform definition of asthma severity, control, and exacerbations: document presented for the World Health Organization Consultation on Severe Asthma. *J Allergy Clin Immunol.* 2010; 126: 926–938
  5. Maria Lucia L. Madariaga, Henning A. Gaissert. Overview of malignant tracheal tumors. *Ann Cardiothorac Surg.* 2018 Mar; 7: 244–254.
  6. Yang PY, Liu MS, Chen CH. Adenoid cystic carcinoma of the trachea. *Chang Gung Med J.* May 2005; 28: 357-363.
  7. Han X , Zhang J, Fan J , Cao Y , Gu J , Shi H. Radiological and clinical features and outcomes of patients with Primary Pulmonary Salivary Gland tumors. *Can Respir J.* 2019; 2019: 1475024.
  8. Falk N, Weissferdt A, Kalhor N , and Moran CA. Primary pulmonary salivary gland-type tumors,” *Adv Anat Patho;* 2016: 23:13–23
- How to cite this article: Bhardwaj M, Bhawani R, Gharsangi K et.al. Asthma mimic- not to be missed. *Int J Health Sci Res.* 2020; 10(3):79-82.

\*\*\*\*\*