

# Diagnosis and Management Protocol of Acute Corneal Ulcer

Vaishal P Kenia<sup>1</sup>, Raj V Kenia<sup>2</sup>, Onkar H Pirdankar<sup>3</sup>

<sup>1</sup>Kenia Eye Hospital, Mumbai

<sup>2</sup>Kenia Foundation, Mumbai

<sup>3</sup>Kenia Medical and Research Foundation, Mumbai

Corresponding Author: Onkar H Pirdankar

## ABSTRACT

Corneal ulceration is one of the leading causes of corneal blindness. Various pathogens are responsible for corneal ulceration. Accurate and quick diagnosis and prompt treatment is a key to improve clinical and visual outcomes in cases of corneal ulceration. However there are no specific guidelines or protocols are available for managing the corneal ulcers. Sometimes even an experienced clinician struggle to predict the course of the disease in most of the cases. Here we make an attempt to provide an overview on diagnostic approach and management protocol of acute corneal ulcer.

**Key words:** Acute corneal ulcer, corneal ulceration, corneal blindness

## INTRODUCTION

Corneal ulceration is one of the major ocular emergencies causing ocular morbidity. It is considered a leading cause of corneal blindness especially in the developing countries. It has been estimated that globally, corneal ulceration with ocular trauma are resulting in 1.5 -2 million cases of corneal blindness annually <sup>1</sup>. It affects males more than the females, can be seen at any age and mostly the patients belong to a low socio-economic strata <sup>2,3</sup>. In developing countries like India, the major reason for corneal ulcer is ocular trauma whereas in the developed countries, the most common reason is contact lens wear.

### Etiology and Epidemiology:

The causes of a corneal ulcer can be infections like bacteria, viruses, fungi or

parasitic (Acanthamoeba). Whereas the non-infectious causes are autoimmune, neurotrophic, toxic, allergic keratitis, chemical burns, keratitis secondary to entropion, trichiasis, blepharitis, lagophthalmos.

Infectious causes of corneal ulceration vary based on geographic location. The common microorganism are Fusarium species, Pseudomonas aeruginosa, Aspergillus spp., S. Pneumoniae, Staphylococcus Spp. Fungal organisms are common in Countries like India, China. In other countries such as Philippines, Taiwan, Thailand and Singapore bacterial organisms such as Pseudomonas aeruginosa is common. Table 1 describes the common microorganisms, by counties <sup>4</sup>.

Common organism	Total	IND	CH	SG	PH	JP	TH	KR	TW
Bacterial	38.0%	38.3%	15.3%	41.3%	53.2%	47.8%	50.5%	42.8%	61.8%
Fungal	32.7	45.6%	30.2%	0.7%	27.0%	6.3%	9.1%	10.0%	8.2%
Parasitic	2.4	2.1%	0.9%	1.3%	5.7%	5.0%	4.0%	1.2%	6.9%
Viral	12.6%	6.9%	46.2%	7.0%	2.0%	16.6%	6.1%	6.0%	8.2%
Infectious Keratitis (Not Specified)	14.5%	7.1%	4.4%	49.7%	12.1%	24.3%	30.3%	40.0%	15.0%

Table 1 describes common organism found in Asian countries (IND-India, Ch- China, SG- Singapore, PH- Philippines, JP- Japan, TH-Thailand, KR- South Korea, TW-Taiwan)

### **Pathogenesis:**

#### **Bacterial:**

Bacterial corneal ulcers are results from the penetration of bacteria after a breach in the corneal epithelial barrier except organisms like gonococcus can penetrate an intact epithelium to cause ulcer. Factors predisposing the epithelium like corneal edema, prolonged contact lens usage, dry eyes, and trauma make it vulnerable to corneal infection. The most common microorganism is *Pseudomonas Aeruginosa* which utilizes glycolyx to adhere to epithelium and then invades into the stroma through breach in epithelial. Inflammatory cells (PMNs) reach the site of corneal breach from the tears and limbal vessels which releases cytokines and interleukins resulting in progressive invasion of cornea and increase in size of the ulcer. Phagocytosis of the organism releases the free radicals and proteolytic enzymes leading to necrosis and sloughing of the epithelium, Bowman's membrane and stroma. In addition, process is facilitated by proteases and exotoxin that are produced by multiplying bacteria and endotoxin that are produced by organisms after their death. The endotoxins are polysaccharides within the cell wall of gram negative bacteria and are responsible for ring infiltrates.<sup>3,4</sup>

#### **Fungal:**

Fungus are classified as yeast, filamentous septated, pigmented and non-pigmented and filamentous without septae. In the tropical countries, the commonest fungus is filamentous like *Aspergillus*, *Fusarium*, in temperate countries yeast fungus like *Candida* is common. Fungal pathogens also enter the cornea after an epithelial breach, following trauma or foreign body in the form of vegetative material or soil particles and after invasion incite a host inflammatory response. The inflammatory

response is less aggressive and slow compared to bacteria. Fungus secretes proteolytic enzymes and fungal antigens and toxins which facilitates their deeper stromal penetration and breach the Descemet's membrane and thereby reach anterior chamber where it forms fungus-exudate-iris mass covering the pupillary area.<sup>5</sup>

#### **Viral:**

In viral ulcer, the virus reaches the cornea from within via terminal branches of ophthalmic division of the trigeminal nerve. It has been postulated that in case of herpes simplex there is an involvement of the sub basal nerves which results in epithelial swelling whereas in case of herpes zoster there is an involvement of deep stromal nerves. So without epithelial breach the virus reaches the eye via nerve endings and the inflammation of nerve causes neurogenic pain. The virus actively replicates in corneal epithelium. The virus in the epithelium forms raised lesion forming superficial punctate keratitis and then sloughs to form large epithelial defect and eventually stromal ulceration.

#### **Parasites such as *Acanthamoeba*:**

*Acanthamoeba* keratitis is most commonly associated with soft contact lens use, Once it is adherent to the contact lens, it survives in the space between the contact lens and the ocular surface and later gets attached to the glycoproteins on the corneal villi. The microtrauma to the corneal epithelial surface due to contact lens use promotes the entry of the organism into the epithelium, they invade Bowman's layer and enter the stroma. The infection then moves along the corneal nerves, produces acute inflammation and radial deposits (radial keratoneuritis). The acute inflammation produces metalloproteases that digest collagen fibrils and allows deeper penetration into the stroma. As the disease progresses, it may penetrate the anterior chamber and can cause endophthalmitis.

#### **Symptoms:**<sup>6,7</sup>

- Reduced visual acuity,
- Tearing,
- Discharge,

- Redness are the common symptoms presented by the patients.
- Pain (Disproportionate pain can be seen in Herpes and Acanthamoeba. Fungal ulcers are quieter whereas pseudomonas are fast growing)
- Diagnostic Approach:

Careful History:

It is very important to keep in mind the TRIAD of ocular trauma, Lowered immune status (either the ocular surface or the individual as a whole) or extremely virulent organisms that penetrate the intact ocular surface. A corneal ulcer cannot develop in a healthy individual with a healthy ocular surface, in the absence of ocular trauma. In this respect, a detailed history focussed on finding the cause of an ulcer in the patient is very important so as to ensure an appropriate management. A history of ocular trauma, ocular surgery,

long-term use of ocular medications (topical steroids, Anti-glaucoma medications), contact lens wear (age of contact lens and lens cleaning solution), and previous ocular infections is important as all these factors alter the ocular surface milieu and promote microbial invasion of the cornea in the absence of trauma. Similarly, systemic diseases such as diabetes, rheumatoid arthritis, hepatitis, auto-immune diseases and their therapy, tuberculosis, malignancy impair the natural immune status of an individual and predisposes to opportunistic infections, unusual microbes, fungi or viruses.

Thorough Slit lamp Biomicroscopy:

A thorough slit lamp examination is useful to evaluate the clinical signs may be helpful to confirm the probable diagnosis. Figure 1 briefly describes the diagnostic approach for acute corneal ulcer.

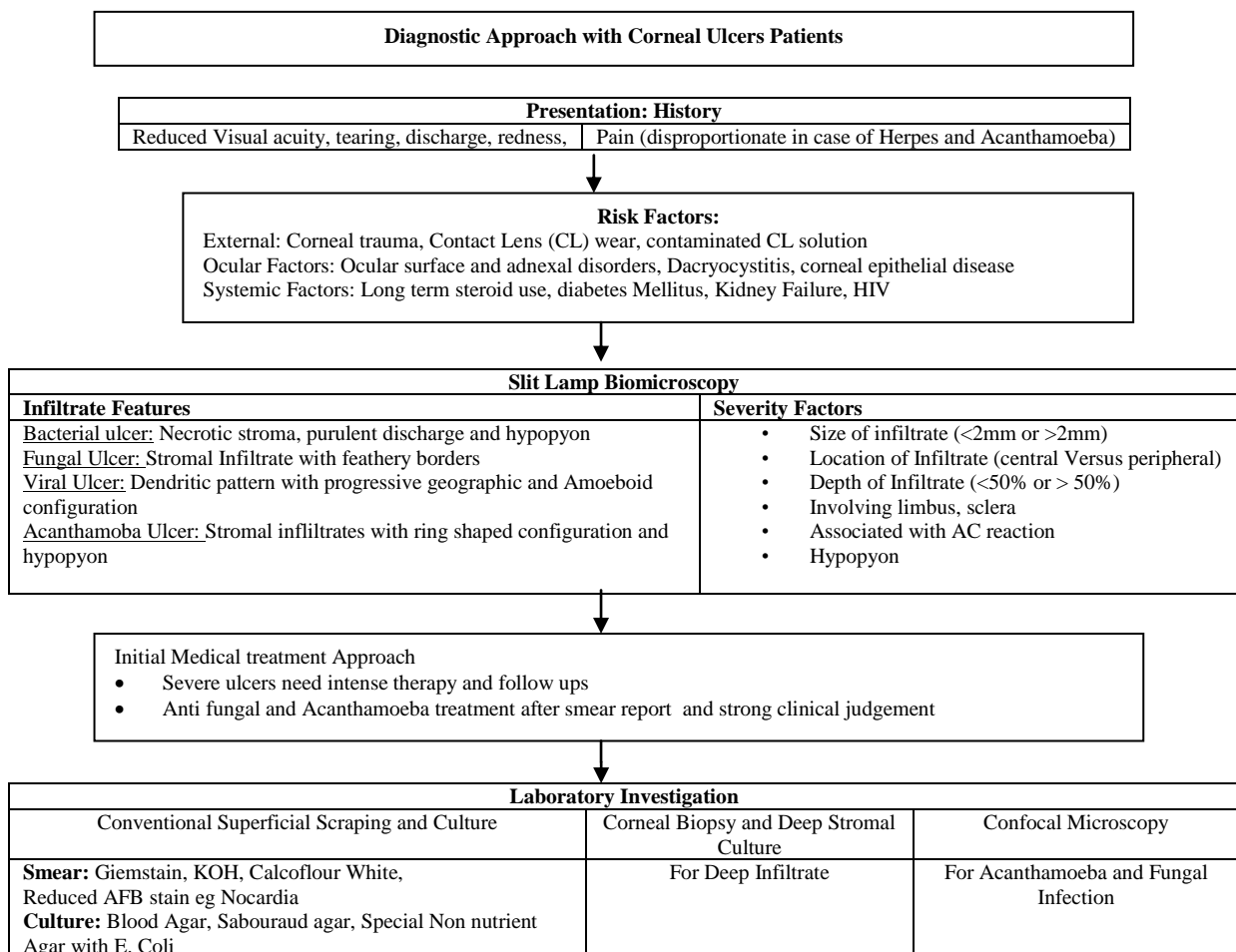


Figure 1: Diagnostic Approach with Corneal Ulcers Patients

Slit lamp examination starts with:

1. Eyelid assessment for Blepharitis, meibomian glands dysfunction, ectropian/ entropion, lagophthalmos.
2. Eyelashes assessment for trichiasis/ distichiasis
3. Lacrimal apparatus system assessment for punctal abnormalities, dacryocystitis
4. Conjunctiva assessment for discharge, inflammation, foreign body, papillae, follicle, cicatrization, symblepharon, pseudomembrane, filtering bleb, tube erosion
5. Sclera assessment for any nodule, thinning
6. Cornea assessment for epithelial defects, punctate keratopathy, stromal edema, ulceration, thinning, perforation, infiltrate characteristics (size, shape, location, depth), foreign body, sign of previous corneal surgeries. Fluorescein or rose Bengal staining allow clinicians to identify some organism or underlying cause. For example in cases of viral infections dendritic ulcers are stained with fluorescein and rose Bengal stain.
7. Anterior chamber assessment for presence of any inflammation, look for cells and flare, hypopyon, hyphema

**Signs:** <sup>6,7</sup>

Although there are no specific signs to identify the responsible organisms, a careful slit lamp assessment with clinical experience help reach probable diagnosis. Various factors such as size, shape, location of Infiltrate, involvement of limbus, sclera, associated with AC reaction and hypopyon gives information about how aggressive the infection is.

**Bacterial:**

Gram positive infection (Figure 2):

- Localized infiltrate with distinct borders
- Minimal stromal haze

Gram negative infection (Figure 3):

- Dense stromal suppuration/ Ring Infiltrate
- Hazy surrounding cornea with a ground glass appearance.

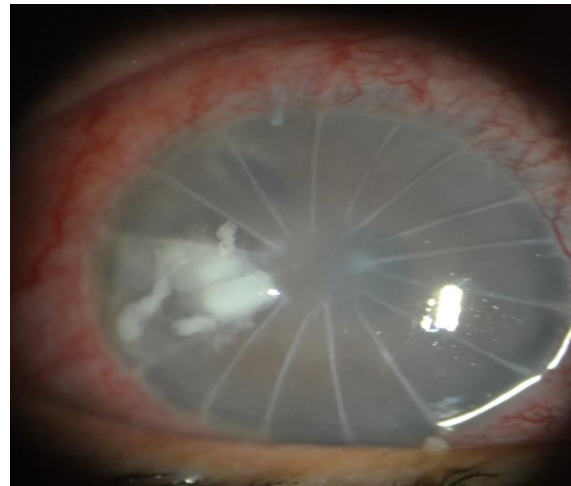


Figure 2: Post RK bacterial ulcer (S. Aureus) (Image from Vaishal P Kenia)

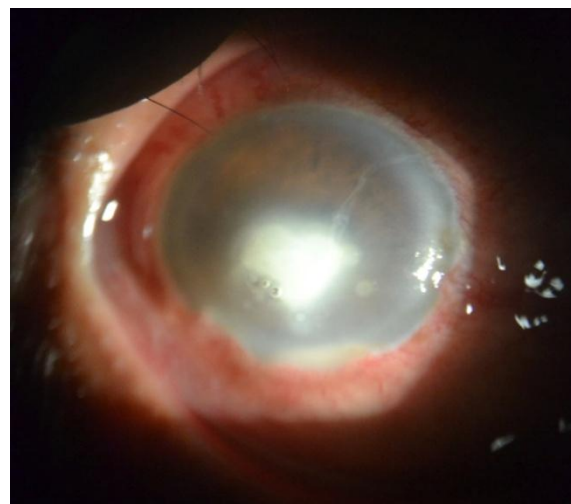

Figure 3: Iron foreign body induced gram negative bacterial corneal ulcer in a diabetic case (Image from Vaishal P Kenia)

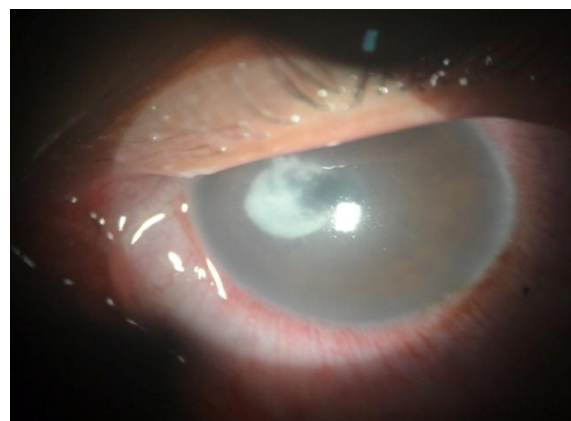

Figure 4: Fungal ulcer with feathery margin with satellite lesion (Image from Vaishal P Kenia)

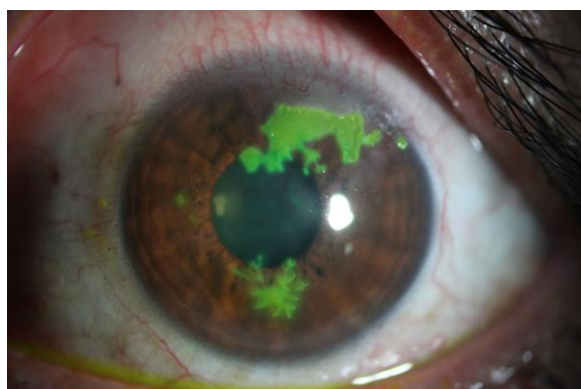**Fungal:**

- Dry raised slough, with a dried appearance of surrounding cornea which is clear.
- Stromal infiltrate with feathery edges,

- Satellite lesions and thick endothelial exudates, (Figure 4)
- Sometimes presents with ring infiltrate
- Hypopyon usually forms which is convex upwards and may wax and wane.

#### **Viral:**

- Viral ulcers can result from herpes simplex or herpes zoster infections
- Viral ulcer can be seen in the form of dendritic pattern (linear branching) due to central desquamation.
- The end of the branches manifest a characteristically swollen appearance.
- It generally gets stained with fluorescence.
- Anterior stromal infiltrate appear under the ulcer but resolves spontaneously.
- Corneal sensation is reduced.
- Progressive centrifugal enlargement may result in larger epithelial defect with a geographical and amoeboid configuration. (Figure 5)



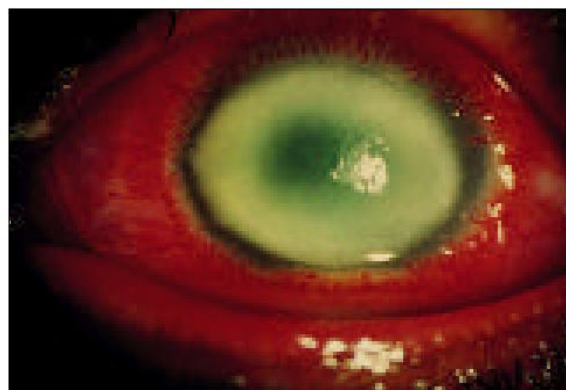
**Figure 5** showing three phases of lesions: epithelial dots (9 o'clock), dendritic pattern (6 o'clock) and a geographic epithelial keratitis (12–2 o'clock), suggesting herpes simplex virus epithelial keratitis.(Image From Gurav P et al 2015 <sup>9</sup>)

#### **Parasitic**

##### **A. Acanthamoeba:**

- Acanthamoeba keratitis can be contact lens or non contact lens related
- Characterized by epithelial irregularities, corneal edema, with single or multiple stromal infiltrates which has classic ring shaped configuration (Figure 6)
- However diffuse and satellite infiltrates are also common.

- Hypopyon is also a common finding in acanthamoeba.
- In late cases radial keratoneuritis can also be noted and can be identified as whitish outline of the corneal nerves <sup>6,7</sup>.



**Figure 6** Ring Infiltrate in Acanthamoeba (Image from Garg P., Rao, G., 1999)<sup>8</sup>

##### **B. Microsporadia:**

- Characterized by raised epithelial lesion and deep stromal keratitis.

Identification of causative organism underlying the disease is important for successful treatment and it requires laboratory investigations. Microscopic examination and cultures is a considered as a gold standard for the accurate diagnosis. Laboratory investigations allow for direct visualization of microorganism in material and help understand the inoculation of material under appropriate conditions to allow multiplication of microorganism.

##### **Microbiological Culture and Light Microscopy:<sup>8,9</sup>**

Traditionally clinicians were heavily dependent on light microscopes, corneal smears and cultures. Conventional smear and culture for bacteria, fungus and Acanthamoeba can be prepare by scraping the base and leading edge of the corneal ulcer using flame sterilized Kimura spatula or sterile surgical blade no 15 on Bard Parker Handle. Every scraping can be use for direct microscopic examination, culture and antibiotic susceptibility testing. These scraping are immediately placed on glass slides for light microscopy and agar plates for culture (Blood agar, chocolate agar, Potato dextrose agar (PDA), Sabouraud agar

etc). The slides for light microscopy are stained with 10% potassium hydroxide or gram stain or Giemsa stain to aid in the visualization of fungal filament, bacterial or Acanthamoeba cyst growth respectively. Special staining such as modified Ziehl Neelsen for nocardia, microsporidia and KOH or calcofluor white staining for acanthamoeba and fungus can be use. For culture the agar plates are inoculated at 25-27degree C for 7 days in case of (PDA) whereas in case of other media it is inoculated at 35-37 degree C (2 days for blood agar) and microorganism growth is assessed on daily basis. Cultures of contact lens, lens case and contact lens solution can also be done in case of contact lens wearers.

### **Corneal Biopsy and deep Stromal Culture technique:**

Corneal biopsy is indicated if the infiltrate is located in the mid or deep stroma with overlying uninvolved tissues. Corneal biopsy can be performed at the slit lamp biomicroscope or operating microscope. After instillation of topical anaesthetic, a small trephine or blade is used to excise a small piece of stromal tissue at the edge of the infiltrate which can be sent for culture as well as histopathology.

### **Antimicrobial Susceptibility:**<sup>9</sup>

Antimicrobial susceptible testing of the isolates is performed by Kirby Buaer Disk Diffusion method using ciprofloxacin (5 µg), ofloxacin (5 µg), gatifloxacin (5 µg), tobramycin (10 µg), chloramphenicol (30 µg), amikacin (30 µg), gentamicin (10 µg), moxifloxacin (5 µg) as per Clinical and Laboratory Standards Institute Guidelines. Disk diffusion method assesses antibiotic sensitivity of bacteria. It uses antibiotic discs to evaluate the extent to which bacteria are affected by those antibiotics. Antibiotic susceptibility does not necessarily directly reflex clinical susceptibility.

### **Confocal Microscopy:**

Confocal microscopy has played a crucial role in the diagnosis of microbial keratitis, fungal and acanthamoba keratitis<sup>8,10,11</sup>.

With advancement in technology, direct visualization of pathogens within the patients cornea is possible. In Vivo confocal microscopy is non invasive technique available in clinical settings. To best of our knowledge there are presently two modalities available for clinical use are scanning slit IVCM (Confoscan, Nidek Technology, Fremont, CA) and laser scanning IVCM (HRT3 with Rostock corneal module, Heidelberg Engineering, Heidelberg, Germany). On confocal microscopy acanthamoeba cyst can be identified as double walled ovoid bodies and fungal bodies were seen as bright linear filamentous structures with bright borders that appear as parallel lines (double walled linear bodies)<sup>10</sup>

### **Treatment protocols**

In majority of the cases the infection is resolved without any acute surgical need. However surgical intervention is required irrespective of infection is resolved or not resolved<sup>2</sup>.Initiation of treatment is based on clinical judgement, smear report and the treatment is modified according to culture report and clinical response. It has also been reported that use of topical cortico steroid is controversial hence they are best avoided.

### **Medical Treatment:**

Antibiotic, antifungal or antiviral eye drops are the treatments of choice however Antifungal and Acanthamoeba therapy started only after microbiological evidences, in most cases. The line of medical treatment and the route of treatment is decided based on the depth, size and location of infiltrates. Central infiltrate would require more aggressive treatment as compared to peripheral, superficial<2mm infiltrate. Deep intrastromal infiltrate would require intrastromal injections as it gives good drug availability at deeper layer.

### **Bacterial Keratitis:**

Topical antibiotics (Monotherapy) can be in given in cases of superficial peripheral infiltrates< 2mm. For deep stromal involvement or an infiltrate larger than 2 mm with extensive suppuration a loading dose every 5-15 minutes followed

by frequent applications such as every hour is recommended. In case of monotherapy, Levofloxacin 1.5% is preferred over Gatifloxacin and Moxifloxacin due to emerging resistance with Gatifloxacin and Moxifloxacin and easier availability of Levofloxacin. In cases of large or visually significant infiltrate or severe infection in the presence of a hypopyon, topical fortified antibiotics is preferred. Systemic antibiotics are rarely required, however they can be considered in severe cases where infection

involves limbus and sclera. Role of corticosteroid in treating the bacterial ulcer is controversial. The SCUT treatment study found no benefit of concurrent topical corticosteroid therapy using prednisolone sodium phosphate 1% in conjunction with broad spectrum topical antibiotics. A pervious study have reported no benefits of corticosteroids in managing corneal scars<sup>12</sup>. Table 2 describes the various antibacterial drugs.

Table 2 describes the various antibacterial drugs.

Gram Positive Cocci	Gram Negative Cocci	Gram Positive Bacilli	Gram Negative Bacilli
Regular antibiotic Cefazolin 4 <sup>th</sup> Generation Fluoroquinolone Higher antibiotics Vancomycin Linezolid	Regular Antibiotics Ceftriaxone Ceftazidime Fluoroquinolone	Regular Antibiotics Amikacin Fluoroquinolone Clarithromycin	Regular antibiotic Fluoroquinolone F. Tobramycin Higher antibiotics Amikacin Ceftazidime Piperacillin Meropenam Colistin

**Fungal Keratitis:**

Fungal ulcers are difficult to treat since the diagnosis is delayed. Mycotic ulcer treatment trial (MUTT) I compared natamycin and voriconazole revealed that Natamycin had showed significant clinical improvement as compared to voriconazole. MUTT II compared oral voriconazole and oral placebo which did report benefits of oral voriconazole in treating Fusarium Ulcer. Steroids are contraindicated in fungal ulcers. Subconjunctival antifungals should be avoided since they result in severe pain and induce tissue necrosis to some extent. Since Intrastromal Voriconazole has a good penetrating capacity it can be considered to treat deep and larger ulcers. Intrastromal Voriconazole can be used as an adjunct to Natamycin in eyes not responding to topical natamycin<sup>13,14</sup>. Table 3 describes Antifungal drugs<sup>6,7</sup>. Figure 7 describes the algorithm for managing severe bacterial keratitis.

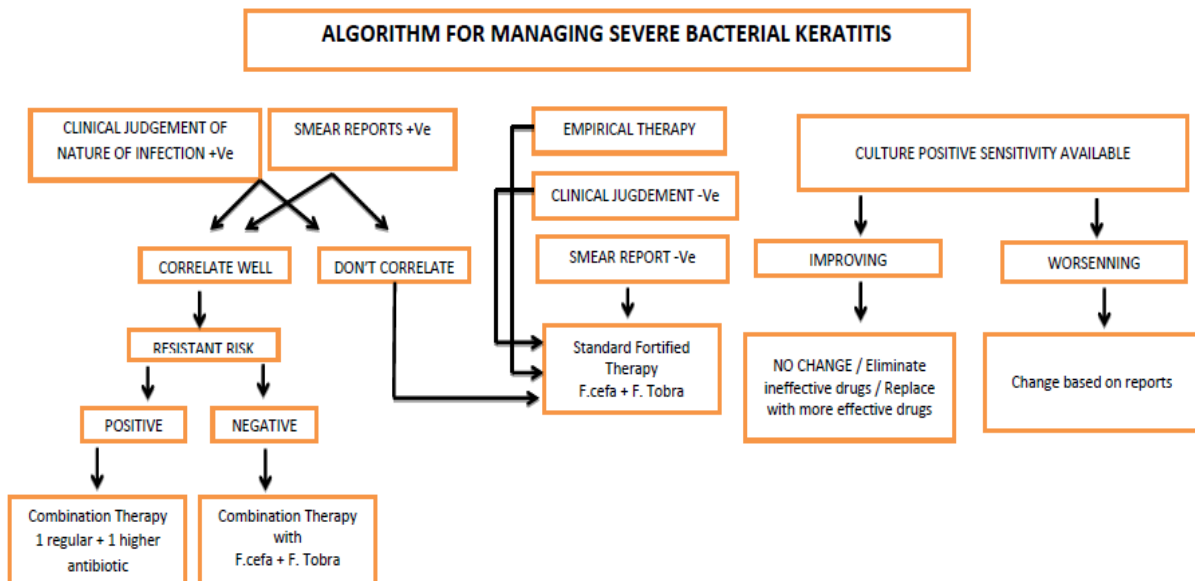


Figure 7: Algorithm for Managing Severe Bacterial Keratitis

**Table 3 describes Antifungal drugs**

Polyenes	Pyrimidines	Imidazoles
e.g. Nystatin, Amphotericin B Natamycin	e.g. Flucytosine	e.g. Clotrimazole Miconazole Ketoconazole Fluconazole Itraconazole

**Acanthamoeba Keratitis:**

A combination of propamidine isethionate (Brolene) 0.1% and polyhexamethylene biguanide 0.02% can be prescribed in initial stage. A combination of brolene and neomycin or monotherapy with chlorhexidine also gives good results. Steroid should be avoided however in case of deep vascularisation steroids and cysticidal agents combination can be used. Oral Miltefosine can be considered as adjunctive treatment for Acanthamoeba keratitis<sup>15</sup>. Table 4 describes Antiameoboid drugs<sup>6,7</sup>.

**Table 4 describes Antiameoboid drugs**

Anticeptic Biocides	Aminoglycosides	Diamidines
Chlorhexidine PHMB	Neomycin Paromomycin	Dibromopropamide Hexamidine

**Viral Keratitis:**

Usually, about 50% of active epithelial lesions heal spontaneously without treatment. The cure rate of antiviral therapy is 95%. In most of the cases healing occur by day 10. After healing has occurred medication should be quickly tapered and discontinued by day 14. Steroids are contraindicated in viral ulcers. Table 5 describes the anti viral drugs<sup>6,7</sup>.

**Table 5 describes anti viral drug**

Topical	Systemic
Acyclovir 3% ointment Ganciclovir 0.15% Gel Trifluorothymidine 1% drop	Oral Acyclovir 400mg Famciclovir 500mg Valacyclovir 1gm Valganciclovir 900mg

**Supplementary treatment:**

Cycloplegic agents such as atropine sulphate 1%, homatropine 1%, or cyclopentolate 1% can be prescribe for three times a day to reduce the ciliary spasm and produce mydriasis, thus help relieve pain and prevent the formation of synechiae. Glaucomatous drug can be prescribed to lower the IOP.

**Causes of Medical treatment failure**

- Wrong diagnosis
- Resistance to Antibiotic especially (Ciprofloxacin, moxifloxacin etc.)
- Non compliance from patients

**Surgical treatment**

Surgical treatment depends on various factors such as size, location and causes of the ulcer.

**Corneal Gluing to manage perforations:**

For managing corneal perforations less than 2mm cyanoacrylate glue is applied. Healing of the cornea occurs as fibrovascular tissue grows under the glue and dislodges the glue. If the perforation is larger than 2mm then either a tenon patch or multilayer amniotic membrane graft is considered. It has been reported that Gunderson flap have also been use to treat perforation however it was found to be non effective.<sup>16</sup>

**Amniotic membrane transplant (AMT):**

AMT can provide structural support in areas of corneal ulceration. The use of a single layered AMT may be sufficient to treat ulcers lacking depth and significant stromal thinning however non effective in cases of deep ulcers and multilayered AMT can be considered<sup>16,17</sup>. It has been reported that AMT is also efficacious in treating neurotrophic Ulcer<sup>18</sup>

DALK using the big bubble technique seems to be effective and safe in the treatment of deep fungal as well Acanthamoeba keratitis unresponsive to medication<sup>19</sup>. Also, therapeutic Keratoplasty have shown good results in Acanthamoeba keratitis<sup>17</sup>. Penetrating keratoplasty (PKP) is performed in advance cases where medical treatment fails or perforation too large to treat by other options<sup>2,7,16,20</sup>

**Novel treatment approaches**

Topical Povidone-Iodine 1.25% has shown to be as effective as topical antibiotics for bacterial keratitis<sup>21</sup>. Collagen shields or contact lenses soaked in antibiotics are used in some cases which may enhance the drug delivery. Nano drug



particles as it has better penetration and drug availability.

Newer treatments such as photoactivated chromophore for infectious keratitis -corneal collagen cross-linking (PACK-CXL)<sup>22,23</sup> have been used in therapy resistant cases of melting corneas and also in novel cases of bacterial keratitis. It has been reported that Dresden protocol technique is found to be efficacious by damaging the DNA and RNA in microbes and thus help in improving and reducing inflammatory response to bacteria. Pack CXL has a very good healing rate in cases of bacteria as compared to fungal. However it works better in superficial infiltrate and future work is required to explore its use in other cases with consideration of treatment parameters as well as pathogen types.

#### Prevention

Since it is vision threatening condition, it is important to increase awareness about eye care. Many causes of corneal ulcers can be prevented by using protective eye wear during travelling or work. Educating the patients about care and maintenance of contact lens can help prevent ulcers related to contact lens wear.

#### REFERENCES

1. Whitcher JP, Srinivasan M, Upadhyay MP. Corneal blindness: A global perspective. *Bull World Health Organ.* 2001;79(3):214-221.
2. Vaddavalli PK, Garg P, Sharma S, Sangwan VS, Rao GN, Thomas R. Role of Confocal Microscopy in the Diagnosis of Fungal and Acanthamoeba. *Ophthalmology.* 2011; 118(1):29-35.
3. Sharma S, Garg P, Rao GN. Patient characteristics, diagnosis, and treatment of non-contact lens related Acanthamoeba keratitis. *Br J Ophthalmol.* 2000;84(10): 1103-1108.
4. Khor WB, Prajna VN, Garg P, et al. The Asia Cornea Society Infectious Keratitis Study: A Prospective Multicenter Study of Infectious Keratitis in Asia. *Am J Ophthalmol.* 2018;195:161-170.
5. Al-Mujaini A, Al-Kharusi N, Thakral A, Wali UK. Bacterial keratitis: Perspective on epidemiology, Clinico-Pathogenesis, diagnosis and treatment. *Sultan Qaboos Univ Med J.* 2009;9(2):184-195.
6. Fleiszig SM, Evans DJ. The Pathogenesis of bacterial keratitis: studies with *Pseudomonas Aeruginosa*. *Clin Exp Optom.* 2002;85(5):271-278.
7. Kuriakose T, Thomas PA. Keratomycotic malignant glaucoma. *Indian J Ophthalmol.* 1991;39(3):118-121.
8. Garg P, Rao GN. Corneal ulcer: Diagnosis and management. *J Community Eye Heal.* 1999;12(30):21-23.
9. Prakash G, Avadhani K, Srivastava D. The three faces of herpes simplex epithelial keratitis: A steroid-induced situation. *BMJ Case Rep.* 2015;2015(12):2014-2015.
10. Chidambaram JD, Prajna N V., Larke NL, et al. Prospective Study of the Diagnostic Accuracy of the In Vivo Laser Scanning Confocal Microscope for Severe Microbial Keratitis. *Ophthalmology.* 2016;123(11): 2285-2293.
11. Motukupally SR, Singh A, Garg P, Sharma S. Microbial Keratitis Due to *Aeromonas* Species at a Tertiary Eye Care Center in Southern India. *Asia-Pacific J Ophthalmol.* 2014;3(5):294-298.
12. Kumar R, Andrea C, Pedram H. Current State of In Vivo Confocal Microscopy in Management of Microbial Keratitis. *Semin Ophthalmol.* 2010;25(5-6):166-170.
13. Srinivasan M, Mascarenhas J, Rajaraman R, et al. The Steroids for Corneal Ulcers Trial (SCUT): secondary 12-month clinical outcomes of a randomized controlled trial. *Am J Ophthalmol.* 2014;157(2):327-333.
14. Sharma N, Agarwal P, Sinha R, Titiyal JS, Velpandian T, Vajpayee RB. Evaluation of intrastromal voriconazole injection in recalcitrant deep fungal keratitis: Case series. *Br J Ophthalmol.* 2011;95(12):1735-1737.
15. Sharma N, Chacko J, Velpandian T, et al. Comparative evaluation of topical versus intrastromal voriconazole as an adjunct to natamycin in recalcitrant fungal keratitis. *Ophthalmology.* 2013;120(4):677-681.
16. Aichelburg AC, Walochnik J, Assadian O, et al. Successful treatment of disseminated *Acanthamoeba* sp. infection with miltefosine. *Emerg Infect Dis.* 2008;14(11): 1743-1746.
17. Tuli S, Gray M. Surgical management of corneal infections. *Curr Opin Ophthalmol.* 2016;27(4):340-347.

18. De Craene S, Knoeri J, Georgeon C, Kestelyn P, Borderie VM. Assessment of Confocal Microscopy for the Diagnosis of Polymerase Chain Reaction–Positive Acanthamoeba Keratitis: A Case-Control Study. *Ophthalmology*. 2018;125(2):161-168.
19. Chen HJ, Pires RTF, Tseng SCG. Amniotic membrane transplantation for severe neurotrophic corneal ulcers. *Br J Ophthalmol*. 2000;84(8):826-833.
20. Gao H, Song P, Echegaray JJ, et al. Big bubble deep anterior lamellar keratoplasty for management of deep fungal keratitis. *J Ophthalmol*. 2014;2014(July 2011):1-9.
21. Jamali H, Gholampour AR. Indications and Surgical Techniques for Corneal Transplantation at a Tertiary Referral Center. *J Ophtha*. 2019;14(2):125-130.
22. Isenberg SJ, Apt L, Valenton M, et al. Prospective, Randomized Clinical Trial of Povidone-Iodine 1.25% Solution Versus Topical Antibiotics for Treatment of Bacterial Keratitis. *Am J Ophthalmol*. 2017; 176:244-253.
23. Hafezi F, Bradley Randleman J. PACK-CXL: Defining CXL for infectious keratitis. *J Refract Surg*. 2014;30(7):438-439.
24. Tabibian D, Mazzotta C, Hafezi F. PACK-CXL: Corneal cross-linking in infectious keratitis. *Eye Vis*. 2016;3(1):1-5.

How to cite this article: Kenia VP, Kenia RV, Pirdankar OH. Diagnosis and management protocol of acute corneal ulcer. *Int J Health Sci Res*. 2020; 10(3):69-78.

\*\*\*\*\*