

## Effect of Shockwave Therapy on Reduction of Dupuytren's Disease: A Case Report

Sivadasan Sandeep Kumar<sup>1</sup>, Suparna Gangopadhyay<sup>2</sup>

<sup>1</sup>Senior Physical Therapist, Department of Neurorehabilitation, Institute of Neurosciences, Kolkata.

<sup>2</sup>Physiatrist, Director, Department of Neurorehabilitation, Institute of Neurosciences Kolkata.

Corresponding Author: Sivadasan Sandeep Kumar

### ABSTRACT

Dupuytren's disease (DD) is a common progressive fibrotic condition affecting the palmar and digital fascia. Although its management is undertaken by hand surgeons, it is commonly seen by other doctors as an incidental finding. In many cases it is believed to be associated with other medical conditions, although the evidence for such associations is not always clear. [1] One of the major determinants of Dupuytren's disease (DD) treatment efficacy is recurrence of the contracture and no definitive treatment. Unfortunately, lack of agreement in the literature on what constitutes recurrence makes it nearly impossible to compare the multiple treatments alternatives available today. [2]

**Case presentation:** A 44 year old female diagnosed to have carpal tunnel syndrome in the year 2015 and operated for the same in may 2015. Later she developed bilateral Dupuytren's contracture (right >left). Shockwave therapy at Institute of Neuroscience, Neurorehabilitation Department was introduced to bilateral hand and it resulted in significant reduction and complete loss of all the symptoms.

**Conclusion:** Shockwave therapy is useful and presents one of most effective, conventional & non invasive treatment for Dupuytren's disease.

**Keywords:** Dupuytren's disease, flexor digitorum superficialis.

### INTRODUCTION

Dupuytren's disease (DD) is a type of fibromatosis which progressively results in the shortening and thickening of the fibrous tissue of the palmar fascia. This condition which predominantly affects white-northern Europeans has been identified since 1614. DD can affect certain activities of daily living such as face washing, combing hair and putting hand in a glove. The origin of Dupuytren's contracture is still unknown, but there are a number of treatments that doctors have come across throughout the years. Historically surgery has been the mainstay treatment for DD but not the only one. [3] Many non-operative therapies have been investigated for the treatment of Dupuytren's disease. These include needle fasciotomy, continuous slow skeletal

traction, radiation, dimethyl sulfoxide, vitamin E, allopurinol, physical therapy, ultrasound therapy, steroid injections, radiation, interferon, splinting, and enzymatic fasciotomy. Most of these therapies have not proven to be clinically useful. [4] However, Shockwave therapy has shown encouraging results.

### CASE PRESENTATION

A 44 year old female developed bilateral carpal tunnel syndrome with numbness and paresthesia of both hands more on the right side since years. She had associated weakness of right hand. She also complained of exacerbation of symptoms in the night and disturbing her sleep. She had difficulty in doing the house hold chores and the symptoms are disabling at times. She is a known case of hypertension

&hypothyroidism on oral medication. She underwent open carpal tunnel release on 12<sup>th</sup> of May 2015 and was uneventful.

Her symptoms recurred and underwent alternative ayurvedic treatment for the same but with no effect in reduction. On November 2018 she came to IN-K neurorehabilitation OPD with exacerbation of symptoms and complained of bilateral wrist and hand pain with mild right claw hand deformity. On examination she had right third FDS (flexor digitorum superficialis) tendon fibrosis superior to third metacarpal bone. Second, third, fourth and fifth FDS tightness leading to clawing. On the left hand third FDS tightness with pain on palpation. VAS was 8/10. Handgrip was reduced (right>left). Her vitamin D<sub>3</sub> was low and bilateral NCV& RA factor levels were normal.

**TREATMENT:**

She was given medication to normalise her vitamin D deficiency and neuropathic drugs, advised for shockwave therapy and manual exercises for the above problems.

Thrice a week for six weeks of shock wave sessions were administered. She

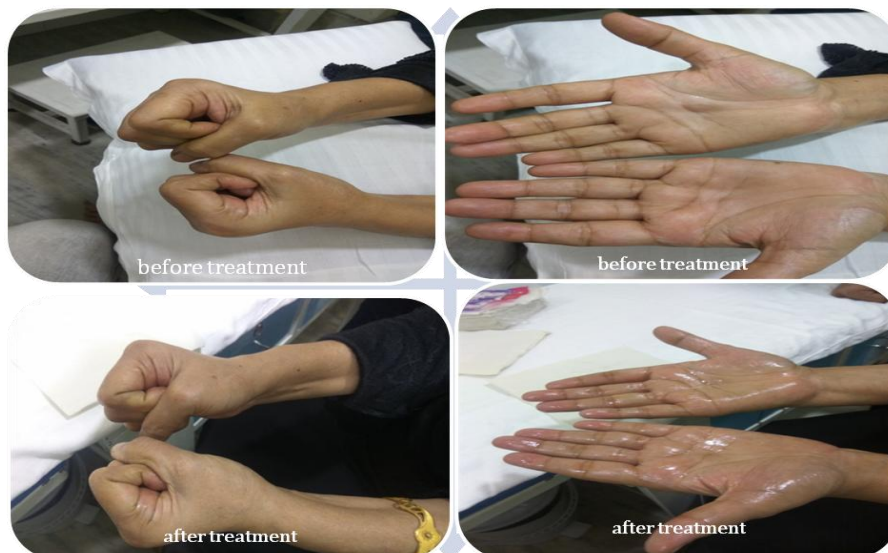was taught and advised to do wrist palmar fascia stretching exercises with neural stretching exercises and contrast bath. From third week she noticed significant reduction in the size of fibrosis and pain, was able to do her household activities. At the end of sixth week there was complete reduction of pain, tightness and fibrosis.VAS 1/10. She resumed all her household activities without pain after 4 years.

**Shockwave parameters used:**

Energy	Target	Frequency
90 <sub>mJ</sub>	1500 beats	10 <sub>Hz</sub>

Diameter of the head: 15 mm  
 Patient position: sitting on chair upright with both hands kept upright with palmar surface facing upright position.  
 Frequency of treatments: 3 days in a week  
 Number of treatments: 18

Complications: Haematoma and petechiae with Temporary hypersensitivity to or an increase in pain & localized swelling. Most symptoms will disappear within minutes or hours after treatment.




**DISCUSSION**

Extracorporeal shockwave therapy (ESWT) began with an incidental observation of osteoblastic response pattern

during animal studies in the mid-1980 that generated an interest in the application of ESWT to musculoskeletal disorders. In the past 10 to 15 years, shockwave therapy had

emerged as the leading choice in the treatment of many musculoskeletal disorders including proximal plantar fasciitis of the heel. Lateral epicondylitis of the elbow, calcific tendinitis of the shoulder and. non-union of long bone fracture. The sources of shockwave generation include electro hydraulic, electromagnetic and piezoelectric principles. Electro hydraulic shockwaves are high-energy acoustic waves generated under water explosion with high voltage electrode. Shockwave in urology (lithotripsy) is primarily used to disintegrate urolithiasis, whereas shockwave in orthopaedics (orthotripsy) is not used to disintegrate tissues, rather to induce tissue repair and regeneration. The application of extracorporeal shockwave therapy (ESWT) in musculoskeletal disorders has been around for more than a decade and is primarily used in the treatment of sports related over-use tendinopathies such as proximal plantar fasciitis of the heel, lateral epicondylitis of the elbow, calcific or non-calcific tendonitis of the shoulder and patellar tendinopathies etc. The success rate ranged from 65% to 91%, and the complications were low and negligible. [5]



Picture demonstrating shockwave

## CONCLUSION

Shockwave therapy proves to be promising effective non invasive therapy in reduction of Dupuytren's contracture.

## Limitations:

Radiological investigations will be included in further studies.

## BIBLIOGRAPHY

1. M G Hart, Hooper. Clinical associations of Dupuytren's disease Postgrad Med J 2005; 81:425-428.
2. Hester J. Kan, Frank W. Verrijp, Steven E. R. Hovius, Christianne A. van Nieuwenhoven, Dupuytren Delphi Group, and Ruud W. Selles. Recurrence of Dupuytren's contracture: A consensus-based definition. PLoS One, v.12 (5); 2017
3. RMafi, S Hindocha, and W Khan. Recent Surgical and Medical Advances in the Treatment of Dupuytren's Disease – A Systematic Review of the Literature. The Open Orthopaedic journal. 2012;6(1):77-82
4. Hurst LC, Badalamente MA. Nonoperative treatment of Dupuytren's disease. Pubmed Hand Clin. 1999 Feb; 15(1):97-107, vii.
5. Ching-Jen Wang. Extracorporeal shockwave therapy in musculoskeletal disorders. Wang Journal of Orthopaedic Surgery and Research (2012) volume 7, Article number: 11

How to cite this article: Kumar SS, Gangopadhyay S. Effect of shockwave therapy on reduction of Dupuytren's disease: a case report. Int J Health Sci Res. 2020; 10(2):102-104.

\*\*\*\*\*