

Utility of Locoregional Flaps in Buccal Mucosa Reconstruction: An Institutional Experience of a Large Cohort

Rajani Bejjihalli¹, Nadimul Hoda², Vasantha Dhara³, Sabitha Kortikere⁴, Jayesh Nathani⁵, Subhabrata Ghosh⁶

¹MDS, Assistant Professor, Oral Oncology, Kidwai Memorial Institute of Oncology, Bangalore, India 560029,

²MDS, Assistant Professor, Oral Oncology, Kidwai Memorial Institute of Oncology, Marigowda Road, Bangalore, 560029, India.

³MDS, Fellow, Oral Oncology, Kidwai Memorial Institute of Oncology, Bangalore, India.

⁴MDS, Professor & Head, Oral Oncology, Kidwai Memorial Institute of Oncology, Bangalore, India.

⁵MDS, Fellow, Oral Oncology, Kidwai Memorial Institute of Oncology, Bangalore, India.

⁶MDS, Fellow, Oral Oncology, Kidwai Memorial Institute of Oncology, Bangalore, India.

Corresponding Author: Vasantha Dhara

ABSTRACT

Objective: To evaluate the utility of locoregional flaps for the reconstruction of buccal mucosa defects in the Indian population attending a tertiary cancer centre.

Materials and Methods: A retrospective study of 302 patients and their records was done, who underwent reconstruction of buccal mucosa with locoregional flaps from January 2016-2017. Buccal fat pad, nasolabial flap, masseter flap, forehead flap, PMMC flap were used for reconstruction and evaluated.

Results: The most commonly used was the PMMC flap in 42.05% of cases, followed by nasolabial flap (25.1%), masseter flap (17.8%), buccal fat pad (11.5%) and forehead flap in (3.3%) of cases. Total flap survival rate was 98.01% with satisfactory functional and esthetic outcomes.

Conclusion: Due to their reliable vascularity, ease of harvesting the flap, and minimal postoperative morbidities, locoregional flaps are still ideal options to reconstruct buccal mucosa defects. These are valuable in resource constrained, high volume centres especially in patients with poor performance and low socio economic strata.

Keywords: Buccal mucosa, Reconstruction, locoregional, nasolabial flap, pectoralis major myocutaneous flap

INTRODUCTION

Head and neck cancer is the sixth common cause of cancer with an estimated worldwide incidence of over 600,000 new cases annually.¹ Carcinoma of the buccal mucosa is the most common cancer of the oral cavity in India.² Surgical management of buccal mucosa is complex in view of its proximity to the masticatory space and the mandible.³

Surgery for tumors of head and neck can cause significant soft tissue, bony and skin defects resulting in functional

impairment such as speech and swallowing deficits. In the past, attempts were made to achieve functional restoration of resected head and neck areas with acceptable cosmesis using locoregional flaps. The last couple of decades have seen an increasing role of microvascular free flaps for optimal soft and hard tissue reconstruction gaining superior functional and esthetic results.^{4,5} However, in many resource deficit centres catering to the economically weak and centres where microvascular setup is not

available, locoregional flaps continue to be used with satisfactory outcomes.

The buccal mucosa is a composite site that may consist of both soft and hard tissue depending on the tumour extensions. Reconstruction of this defect has been done using locoregional flaps at our institution and the choice of the flap is dependent on the location, size, extent of the tumour.

MATERIALS AND METHODS

A retrospective records review was performed of all cases of carcinoma of primary buccal mucosa treated surgically in the department of oral oncology, Kidwai Memorial Institute for Oncology. Loco regional flaps such as buccal fat pad, nasolabial flap, masseter flap, forehead flap, PMMC flap were used for reconstruction of buccal mucosa defects in all these cases. Cases with complete records, including demographic, clinical, and surgical data, were included. Complications of flaps were noted. All statistical analyses and graphics were performed by SPSS 22.0 statistical package (SPSS, Inc., Chicago, IL, USA). A Chi-square test was used for comparison of categorical variables. A value of $p < 0.05$ was considered statistically significant.

RESULTS

The charts and records from the oral oncology Unit, identified 302 biopsy proven cases of squamous cell carcinoma of buccal

mucosa from the database between January 2016 to Jan 2017.

There were 135 men and 167 women in our series. The mean age of patients was 54.5 years. The length of hospitalization ranged from 7 to 24 days. Amongst the males, 42.9% (n= 58) had a history of smoking, 48.2% (n=66) had a history of alcohol consumption and 88.6% (n= 119) had a history of tobacco/ areca nut consumption. Amongst the females, 92.6% (n= 154) of them had a history of arecanut/ tobacco chewing. 158 patients in total had medical comorbidities such as hypertension, diabetes mellitus, thyroid disorder and cardiac conditions.

The tumor size stages were as follows: T I in 29 patients (9.6%), T2 in 74 patients (24.5%), T3 in 102 patients (33.7%), and T4 in 97 patients (32.1%). (Figure 1)

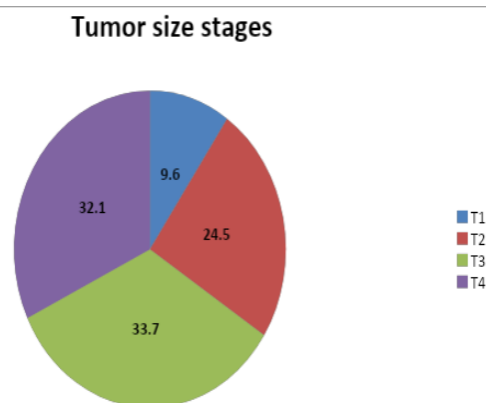


Figure 1: distribution of tumour size

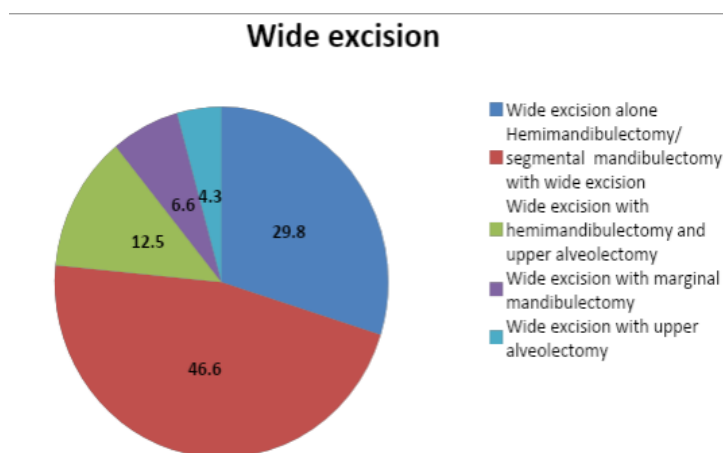


Figure 2: distribution of surgical treatment

Wide excision with adequate margin was done in all the cases with or without bony resection, with or without skin margins depending on the tumour involvement. Wide excision alone was done in 29.8 % of cases (n= 90). Hemimandibulectomy / segmental mandibulectomy with wide excision was done in 46.6% of cases (n= 141). Wide excision with hemimandibulectomy and upper alveolectomy was done in 12.5% of cases (n=38). Wide excision with marginal mandibulectomy was done in 6.6% of cases (n=20). Wide excision with upper alveolectomy was done in 4.3% of cases (n=13). (Figure 2)

The most commonly used was the PMMC flap in 42.05% of cases (n = 127), followed by nasolabial flap 25.1% (n= 76), masseter flap 17.8% (n= 54), buccal fat pad 11.5% (n= 35) and forehead flap in 3.3% (n=10) of cases. (Figure 3)

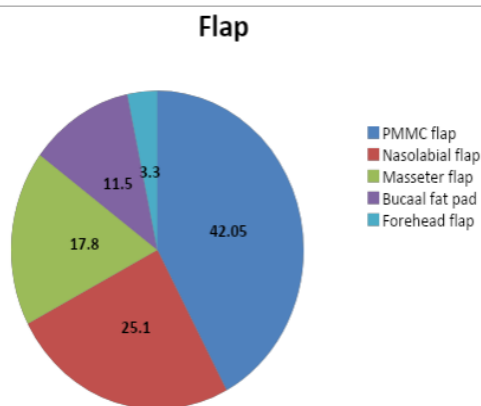


Figure 3: distribution of flap reconstruction options

Total flap survival rate was 98.01% (296/302). Two PMMC flaps developed signs of congestion postoperatively, which was caused by a hematoma that necessitated surgical exploration. Spontaneous recovery of the flaps followed later. 2 PMMC flaps and 1 forehead flap completely failed. The two failed PMMC flaps were debrided and the forehead flap was used for secondary defect closure. The failed distal part of the forehead flap was debrided and after wound contraction, nasolabial flap was used for secondary reconstruction. 1 PMMC flap

underwent partial necrosis and healed secondarily. Marginal necrosis of PMMC flap was found in 18 cases (15 females, 3 males). 10 patients in this group had diabetes mellitus. Wound dehiscence was noted in 2 cases of PMMC flap and 1 nasolabial flap. Orocutaneous fistula was noted in one nasolabial flap case and one PMMC flap case. Patients underwent primary closure after excision of fistula. Wound dehiscence at the donor site of PMMC was seen in 6 cases, which underwent secondary healing (all males). Twenty-six patients (28.0%) developed at least one other postoperative complication, including wound infection (n = 5), wound dehiscence (n = 1), fistula (n = 10), and bleeding (n = 1). The mean mouth-opening width was 3.7cm at 6 months post surgery. The comprehensive analysis of the patient's characteristics was analysed to identify the factors that may have the adverse effect on the success rate of the flap. (Table 1)

TABLE 1 - Clinicopathologic characteristics of patients with flap necrosis.

	Number	Flap necrosis (24) (COMPLETE / PARTIAL/ MARGINAL)	P value
Gender:			
Male	135	4	0.048
Female	167	20	
Age			
>45	123	15	0.765
<45years	179	9	
PORT			
Yes	254	18	0.684
No	48	6	
Smoking			
Yes	58	4	0.921
No	244	20	
Comorbidity			
Yes	158	21	0.036
No	144	3	

No significant differences were found between the two groups in terms of age, smoking and radiotherapy (p > 0.05). Female gender was associated with risk of flap necrosis (p= 0.048). Our analysis indicated an association between existence of a medical comorbidity and increased risk of flap necrosis (p = 0.036). Majority of patients were satisfied with the appearance during our follow-up, and were capable of maintaining a regular oral diet. (Table 2)

TABLE 2: Postoperative function results in buccal mucosa defects:

TYPE	NUMBER	COSMETIC APPEARANCE		DIET		SPEECH	
PMMC	127	Satisfied	64	Normal	72	Fluent and intelligible	61
		Neutral	52	Soft	54	Intelligible with effort	65
		Dissatisfied	12	Liquid	1	Unintelligible	1
Nasolabial	76	Satisfied	54	Normal	59	Fluent and intelligible	74
		Neutral	18	Soft	17	Intelligible with effort	2
		Dissatisfied	4	Liquid	0	Unintelligible	
Forehead	10	Satisfied	1	Normal	3	Fluent and intelligible	7
		Neutral	4	Soft	6	Intelligible with effort	2
		Dissatisfied	3	Liquid	1	Unintelligible	1
Masseter	54	Satisfied	25	Normal	20	Fluent and intelligible	51
		Neutral	23	Soft	24	Intelligible with effort	3
		Dissatisfied	6	Liquid	0	Unintelligible	0
Buccal fat pad	35	Satisfied	35	Normal	34	Fluent and intelligible	35
		Neutral	0	Soft	1	Intelligible with effort	0
		Dissatisfied	0	Liquid	0	Unintelligible	0

The follow-up period ranged from 6 to 36 months.

DISCUSSION

Locoregional soft tissue flaps have been time tested reconstruction options being practised even today in the decade of microvascular flaps due to various factors. Their vascularity, ease of harvesting, colour match and abundance of skin and soft tissue for reconstruction have been reliable. Their biggest drawback of not providing bone replacement in resected cases has given clear indications for using osteocutaneous microvascular flaps or non vascularised grafts for smaller defects. Considering a requirement of significantly higher technical expertise, longer operative times, intensive care units for patient management and flap monitoring, the less technique sensitive local flaps are options which may not be replaced. The COVID pandemic put a strain on many cancer centres and these locoregional flaps have come to the rescue in restrained situations.

In our study a gamut of locoregional soft tissue flaps were used. After adequate wound healing and flap take up, 254 patients were referred for adjuvant treatment based on the histopathology report. Parameters such as aesthetics, oral competence, mouth opening and ability to eat which were noted in records during follow up periods were included and were found satisfactory. Complete flap failure rate in our study was only seen in 3 cases (2 PMMC , 1 forehead flap). Partial/ Marginal

necrosis was seen in 21 patients, of whom 18 of them were in females with PMMC flaps. Management was either done by a secondary flap reconstruction or debridement with secondary healing under antibiotic cover.

Buccal mucosa is a common site for oral cancer, and the reconstruction options depend upon the site and size of defect.⁶ The gingivobuccal sulcus cancers, also known as the Indian cancer, invariably involve a part of the buccal mucosa in most cases, requiring segmental or hemimandibulectomy with reconstruction using flaps providing bulk. For smaller lesions, primary closure is possible, however it depends on the depth of resection which also dictates reconstruction options. For superficial resections, skin grafts and even buccal fat pads are ideal. When the defect ranges from upper to lower sulcus, with or without alveolectomy; forehead flap, nasolabial flap, submental flap, platysma flap, or temporalis muscle flap are standard options.⁷ Pectoralis major myocutaneous flap is the most sought after for hemimandible or segmental defects and inset done either as a single or bipaddle manner.

Buccal Fat Pad

The buccal fat pad flap is utilized for reconstructing small-to-medium-sized soft tissue defects and as a cover for bony defects in the palate and alveolus. The first use of buccal fat pad for oral malignancy defects was done by Rapidis et al.,Hao, and

Dean et al.^{8,9,10} Buccal fat pad could be involved as a deeper margin in some resections and in such cases it cannot be used as a reconstruction option.¹¹ Gentle handling of flap is essential while inseting as stretching can impair its vascularity. The epithelialization of bfp takes around 4-6 weeks. In our cases, adequate healing was observed with maintenance of mouth opening. (Figure 4)

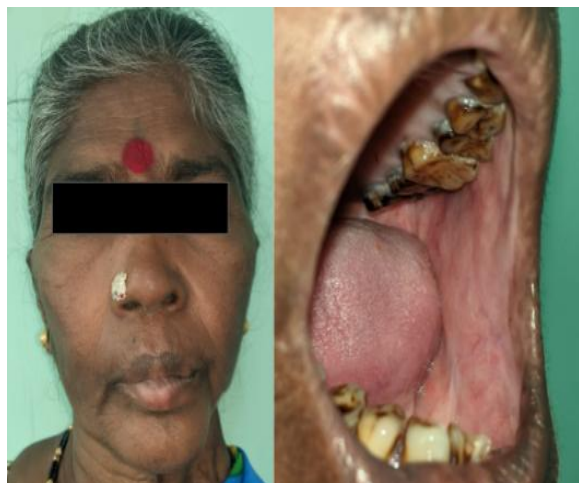

Figure 4: healed site of buccal fat pad

Nasolabial flap

Nasolabial flap is a very versatile flap regularly used for reconstruction of defects of cheek, nose, lips and oral cavity. Based on its orientation, it is supplied by the facial artery, transverse facial artery (inferior based), or superficial temporal artery and infraorbital artery (superior based).¹² Depending on the defect, the flap can be raised as thin as deep to the subdermal plexus, and as thick as superficial to the facial musculature with their nerve supply intact.¹³ Nasolabial flap in our series, has been extensively used for buccal mucosa, commissure, upper lip or lower lip, lower alveolus and upper alveolus resection cases. In males, hair growth could be a limiting factor initially. Fine suturing of the incision can ensure a more esthetic result eventually. (Figure 5)

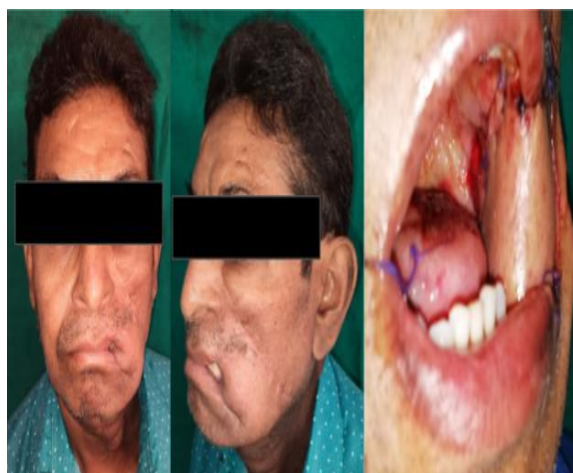

Figure 5: use of nasolabial flap

Masseter muscle flap

It was first introduced as a reconstruction option by Conley and Gullane in 1978 for oropharyngeal defects.¹⁴ While raising the cheek flap, the fascia over masseter is incised to include it thus preserving branches of the facial nerve. the inseting of the flap can be done by transposing it horizontally while maintaining the superior zygoma attachment.¹⁵ Selection of masseter flap as reconstruction option is to be decided carefully as in cases of its involvement or proximity to tumour will require resection of it as per oncological principles. Thus thorough clinical and radiological evaluation is necessary before using this flap. In our cases, patients were strictly advised mouth opening exercises after 5 days. The disadvantage in some patients would be the deformity present anteriorly. (Figure 6)

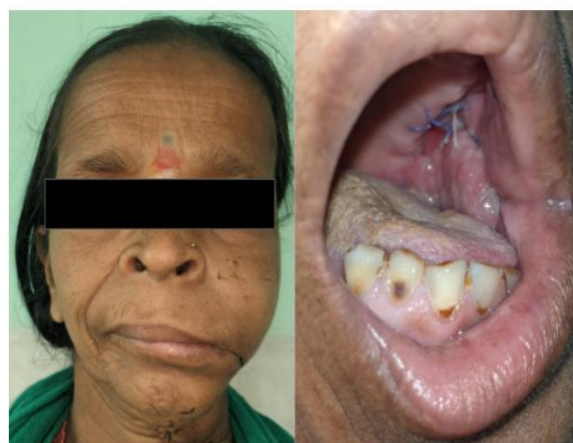

Figure 6 : use of masseter flap

Pectoralis major myocutaneous flap

PMMC flap has been the workhorse of head and neck reconstruction due to the advantages it provides such as excellent blood supply, bulk of skin and muscle with ease of harvesting.¹⁶ The arterial supply is by the thoracoacromial artery, lateral thoracic artery and superior thoracic artery.¹⁷ The popularity of the PMMC flap as the go-to option is understood by its use in the reconstruction of oral cavity defects following resection of lateral gingivobuccal complex lesion, composite defects

following segmental or hemimandibulectomy, full thickness cheek defects, and total glossectomy defects. Anchoring sutures during flap raising to hold the muscle base to the skin is essential to prevent shearing of the flap. suturing and inseting of the flap is to be done diligently without much torsion as it can lead to damage to the pedicle. The majority of our cases required PMMC flap for reconstruction with good functional and esthetic outcomes. (Figure 7)

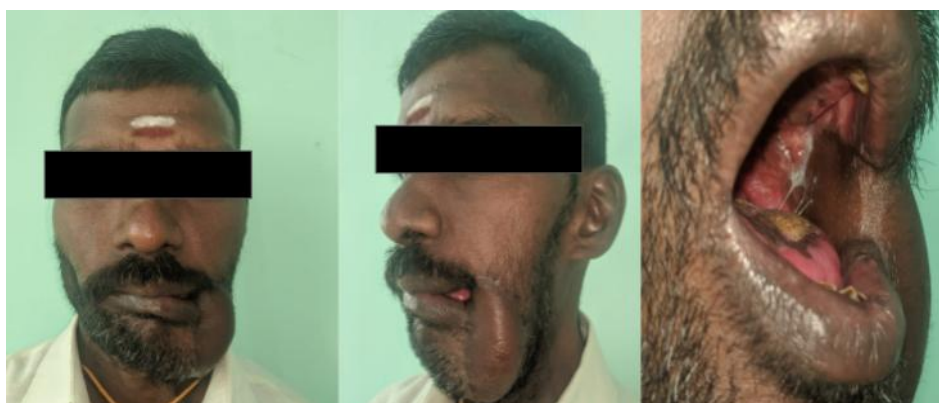

Figure 7: use of pmmc flap

Marginal necrosis is a relatively common complication in females due to the fat bulk between the muscle base and the skin.

Forehead flap

The forehead flap is not being frequently used since the past few decades. However due to its proximity and vascularity it is a dependable option for reconstruction of nasal and cheek defects.¹⁸ The forehead flap is an axial pattern fasciocutaneous flap supplied by superficial temporal vessels.¹⁹ It is raised as a median, paramedian flap in a vertical fashion or full length or partial length flap in a horizontal fashion.²⁰ The donor site is covered with a split skin graft. In any reconstruction setting, The forehead flap is done as a two-stage procedure. For our cases, forehead flap was used in defects involving the buccal mucosa with and without lip and commissure involvement. The length of the flap is adequate to fold and make an intra oral and

extra oral lining. After a healing period of 3 weeks, the proximal portion of the flap is cut and disposed of. (Figure 8)

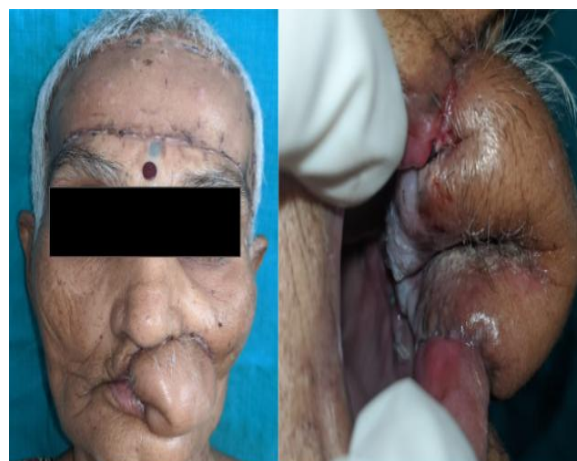

Figure 8: use of forehead flap

The disadvantage is the residual forehead donor site scar due to full thickness skin graft.

The huge patient load coming from a challenged socioeconomic background and lack of high expertise centres, locoregional

flaps are options which may not fade away completely. The last few years have seen other local flaps being increasingly used such as the submental flap, supraclavicular flap, infrahyoid flap, temporoparietal flap, etc.²¹ Mastering these flaps is essential for the younger surgeons before moving on to the more sophisticated free flaps.

CONCLUSION

A wide range of reconstructive options are available for composite defects resulting from buccal mucosa cancer resections, the efficacy of which depends on the specific anatomy of the defect, planned outcome, the patient's tolerance for donor site morbidity, and the surgeon's training and experience. Our institute's experience shows locoregional flaps are still an option for buccal mucosa resections with acceptable aesthetic and functional outcomes.

ACKNOWLEDGEMENTS

Study conducted retrospectively from records exclusively. Ethical approval waived by the Institutional review board.

Conflict of Interest: No Conflict of interest among authors.

Funding Sources: No funding sources present.

REFERENCES

1. Ferlay J, Soerjomataram I, Ervik MB. GLOBOCAN 2012: Cancer Incidence, Mortality and Prevalence Worldwide. International Agency for Research on Cancer; 2012. Available from: <http://www.globocan.iarc>.
2. Srivastava V, Kaur T, Sucharita V. Consensus Document for Management of Buccal Mucosa Cancer. NewDelhi: Indian Council of Medical Research;2014.
3. Fang QG, Shi S, Li ZN, et al. Squamous cell carcinoma of the buccal mucosa: analysis of clinical presentation, outcome and prognostic factors. *Mol Clin Oncol*. 2013; 1:531-4.
4. Kalavrezos N, Bhandari R. Current trends and future perspectives in the surgical management of oral cancer. *Oral Oncol*. 2010;46:429-32.
5. Fang QG, Safdar J, Shi S, et al. Comparison studies of different flaps for reconstruction of buccal defects. *J Craniofac Surg*. 2013; 24:e450-1.
6. Iyer SG, Pradhan SA, Pai PS, Patil S. Surgical treatment outcomes of localized squamous carcinoma of buccal mucosa. *Head Neck*. 2004;26(10):897-902. doi:10.1002/hed.20096
7. Squaquara R, Kim Evans KF, Spanio di Spilimbergo S, Mardini S. Intraoral reconstruction using local and regional flaps. *Semin Plast Surg*. 2010;24(2):198-211. doi:10.1055/s-0030-1255337
8. Rapidis AD, Alexandridis CA, Eleftheriadis E, Angelopoulos AP. The use of the buccal fat pad for reconstruction of oral defects: Review of the literature and report of cases. *Oral Maxillofac Surg*. 2000;58:158-63.
9. Hao SP. Reconstruction of oral defects with the pedicled buccal fat pad flap. *Otolaryngol Head Neck Surg*. 2000;122:863-7.
10. Dean A, Alamillos F, Garcia Lopez A, Sanchez J, Penalba M. The buccal fat pad in oral reconstruction. *Head Neck*. 2001;23: 383-8.
11. Samman N, Cheung LK, Tideman H. The buccal fat pad in oral reconstruction. *Int J Oral Maxillofac Surg*. 1993;22:2-6
12. Verghese BT, Sebastian P, Cherian T, Mohan PM. Nasolabial flap in oral reconstruction: An analysis of 224 cases. *Br J Plast Surg*. 2001;54:499-503.
13. Rahpeyma A, Khajehahmadi S. The place of nasolabial flap in orofacial reconstruction: A review. *Ann Med Surg (Lond)*. 2016; 12:79-87 doi:10.1016/j.amsu.2016.11.008
14. Mahieu R, Russo S, Gualtieri T, Colletti G, Deganello A. Oral cavity reconstruction with the masseter flap. *Acta Otorhinolaryngol Ital*. 2016;36:139-43.
15. Conley J, Gullane PJ. The masseter muscle flap. *Laryngoscope*. 1978;88:605-12.
16. Tobin GR. Myocutaneous flaps for head and neck reconstruction. *Am J Surg*. 1984; 147(3):305. doi: 10.1016/0002-9610(84)90114-4.
17. Ariyan S. The pectoralis major myocutaneous flap. A versatile flap for reconstruction in the head and neck. *Plast Reconstr Surg*. 1979;63:73. doi: 10.1097/00006534-197901000-00012.

18. Baliarsing AS, Thorat TS, Gupta A, Bhat U, Garg S, Bhattacharyya D. Flap selection in head and neck cancer reconstruction. *Int J Otorhinolaryngol Clin.* 2013;5:63-76.
19. Nakajima H, Imanishi N, Minabe T. The arterial anatomy of the temporal region and the vascular basis of various flaps. *Br J Plast Surg.* 1995;48:439-50
20. Agbara R, Fomete B, Obiadazie AC, Omeje KU, Amole OI. The forehead flap: a valuable option in resource depleted environment. *Plast Aesthet Res.* 2016; 3:115-120. <http://dx.doi.org/10.20517/2347-9264.2015.123>
21. Patel UA, Hartig GK, Hanasono MM, Lin DT, Richmon JD. Locoregional Flaps for Oral Cavity Reconstruction: A Review of Modern Options. *Otolaryngol Head Neck Surg.* 2017;157(2):201-209. doi:10.1177/019459981770058

How to cite this article: Bejjihalli R, Hoda N, Dhara V et.al. Utility of locoregional flaps in buccal mucosa reconstruction: an institutional experience of a large cohort. *Int J Health Sci Res.* 2020; 10(12):325-332.
