

# Refractive Accommodative Esotropia: Case Report

Vinitkumar Kamble<sup>1</sup>, Bhadra Priya<sup>1</sup>, Satbodh Shrestha<sup>2</sup>, Arbind Ray<sup>3</sup>

<sup>1</sup>Resident, RIO (Ophthalmology), IGIMS Medical College, Patna (Bihar)

<sup>2</sup>Ophthalmologist, Sagarmatha Choudhary Eye Hospital, (SCEH), Lahan

<sup>3</sup>Optometry Student, Dr R P Centre AIIMS, New Delhi

Corresponding Author: Vinitkumar Kamble

## ABSTRACT

Accommodative esotropia is the popular childhood form of ocular misalignment and has an enthusiastic sequel if management is beginning on time. Here we have single case report reviews a composite presentation of accommodative esotropia and describes the treatment choices.

**Keywords:** accommodative, abnormal head posture, esotropia, refractive

## INTRODUCTION

A 3-year-old male child, presented to Paediatric eye department at RIO, IGIMS Medical College, Patna. The patient's mother was concerned that her son's eyes were turning in and he had a no face turn or chin elevation. Mother also told that her son had never worn glasses or received any type of treatment for the eye turn. The patient's medical history was first child, born in the hospital with full term normal vaginal delivery without complication. Past surgical history was non-significant. Family history shows no known strabismus or inherited eye condition. He is not currently on any medications. Patient had presented to the paediatric department six months previously for a routine eye exam. At that time refractive error was documented as being within normal limits for her age, no heterotropia was noted at distance or near, and a no abnormal head posture was noticed.

Examination: A thorough eye exam was performed. Due to his age and limited understanding several standardized tests were unable to be performed.

Best-corrected visual acuity by Snellen optotype was unable to be measured, therefore fixation response was

assessed using CSM (central, steady, maintained) method.

Patient was noticed to have identical fixation design with either eye and did not resist for occlusion of each eye. Sensory tests were not performed due to the child is non understanding of the Titmus Fly test and Worth 4-dot tests. Pupils were equal, round, reactive and no afferent pupillary defect was noted.

The child had a no head turn. We demonstrated an 80-prism dioptre intermittent esotropia at distance and near in primary gaze position another gaze position was difficult to determine because of uncooperative child. No alphabet pattern squint was found in primary gaze and extraocular movements were full in all gaze. Cycloplegia was accomplished using 1% cyclopentolate. Post-cycloplegia retinoscopy found +3.00 DS OD and +4.00 DS OS. Anterior segment was within normal limit.

Dilated fundus exam was within normal limit. Differential diagnosis considered in our case which includes sixth cranial nerve palsy, essential infantile esotropia or congenital esotropia, Type I Duane's retraction syndrome and refractive or non-refractive accommodative esotropia.

Cranial nerve sixth (CN VI) palsy should be ruled out because intermittent, alternate pattern of esotropia was present with no abnormal head posture and negative forced duction test. This diagnosis is classified with an abduction deficit that can sometimes elicit a head turn to compensate for the paretic lateral rectus muscle<sup>(1)</sup>. Other additional signs of a CN VI palsy include an esotropia that is greater when measured at distance than near and is larger in magnitude when a patient is gazing into the field of the paretic muscle.<sup>(1)</sup>

In children, a cranial nerve sixth palsy can be triggered by a viral infection, vaccine administration or trauma.<sup>(1)</sup> Child mother reported he was negative for all of these forerunners. Another differential diagnosis to consider would be infantile, or congenital, esotropia. This idiopathic condition presents in an infant by the age of 3 to 6 months with approximately 1-2 dioptres of hyperopia.<sup>(2)</sup> It is associated with a positive family history of strabismus, inferior oblique overaction, dissociated vertical deviation and a large angle of deviation, usually larger than 30 prism dioptres.<sup>(2)</sup>

In our case report child did exhibit a larger angle of esotropia, the onset of strabismus is well beyond the age of 6 months, which we can confirm from her prior eye examination six months before when no strabismus was detected.

Duane syndrome (DRS) type I is characterized by the patient having the inability to abduct and type III is associated with poor abduction and adduction of the same eye.<sup>(2)</sup> Most commonly Duane syndrome presents unilaterally and can have an associated palpebral fissure narrowing and globe retraction concurrent with attempted or actual adduction<sup>(2)</sup>. Patients of DRS have no squint in primary position, but in some cases, AHP of small angle found to assist recoup their incapacity to abduct or adduct. We ruled out DRS due to the fact that child had no ocular motility restrictions in any field of gaze with no palpebral fissure narrowing.

Therefore, child was tentatively diagnosed with a refractive accommodative esotropia. Accommodative esotropia is identified by a convergent variance of the eyes consorted with rousing of the accommodative reflex.<sup>(3)</sup> This type of strabismus usually presents between 6 months and 7 years of age; average onset is 2.5 years old.<sup>(3)</sup> Treatment in our case scenario included the full cycloplegic spectacle prescription for full time wear and he was scheduled for a follow up in two months.

## DISCUSSION

Accommodative esotropia is the most common form of all childhood strabismus<sup>(4)</sup> and can be divided into two types (1) refractive (fully accommodative and partly accommodative) (2) nonrefractive<sup>(2)</sup> (convergence excess and hypo accommodative convergence excess)

Refractive accommodative esotropia reveal the same prism dioptre angle of squint at both near as well as distance without glasses rectification. The beginning of accommodative esotropia mostly starts at the age of two to three, but has been observed in child of 4 months old<sup>(5)</sup>. The refractive error of these children averages + 4.75 dioptres<sup>(3)</sup>. The mechanism behind accommodative esotropia consists of three components: under correction of the hyperopia, accommodative convergence, and insufficient fusional divergence.<sup>(3)</sup> An uncorrected hyperope is forced to accommodate excessively to produce a clear retinal image. In the presence of accommodation, convergence is stimulated requiring the patient's fusional divergence system to react. If the child has a deficient fusional divergence working and cannot reimburse for the convergence factor, an esodeviation will happened<sup>(2)</sup>. The treatment for a child is their full cycloplegic hyperopic spectacle correction.<sup>(2,3)</sup> This will reduce the load of accommodation needed to fine their retinal image, which in turn will keep the exact eye alignment.

If a patient has a residual esodeviation even with their full hyperopic glass correction, the residual deviation is nonaccommodative and is classified as partially accommodative. Partial accommodative esotropia commonly occurs because the accommodative treatment needed for an accommodative esotropia was delayed. (2)

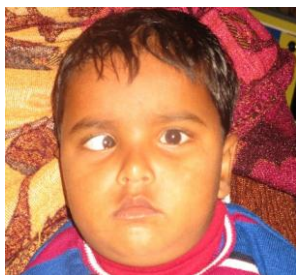In few patients of esotropia accommodative factor has been removed with the corrective glasses, but after some period the non-accommodative factor steadily becomes exposed. These patients's treatment may include a surgical management. (3) Hutchinson et al (7) in 2004 suggest that roughly 77% of child with accommodative esotropia have a first or second degree relative with same state. First degree relatives alone, the prevalence of accommodative esotropia is 23%, so it is essential to have siblings examined. These esotropia are commonly associated with amblyopia. Generally, in Refractive accommodative esotropia (8) the deviation is between 23 and 30 PD which is constant for distance and near. The average amount of hyperopia is +3 up to +10 D. The main aim of treating this eye position are to replace normal eye alignment, to keep up good visual acuity in each eye and assist good binocular function. Management consists of giving spectacle correction with full

hyperopic correction which is calculated from wet retinoscopy. A large amount of delay in early treatment following esotropia rises the likelihood of nonaccommodative factor which is called as partially accommodative esotropia which is defined by Mulvihill et al (9) in 2000. If there is any associated amblyopia the treatment should be started to address this issue.

## TREATMENT

Patient was given the full cycloplegic hyperopic correction so that the disparity of refractive and partially accommodative esotropia could be made at her follow up visit. If ocular alignment through the spectacle prescription is orthophoria the conclusion can be made that her esotropia is purely refractive component.

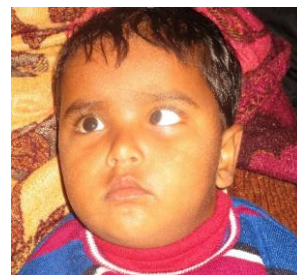Berk et al in 2004 explained that if the beginning of ocular misalignment is after two years of age, then many patients of accommodative esotropia the prognosis has been good due to some form of developing fusion ability. (5) Amblyopia is a common associated finding to be monitored for at our follow up visit, mainly since her refractive error is positive for anisometropia. With accommodative esotropia, anisometropia was found to be the only statistically significant risk factor for the development of amblyopia. (5)



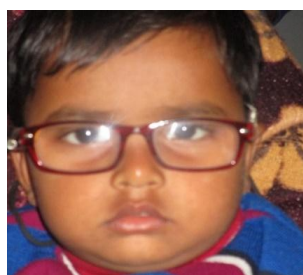Picture A




Picture B



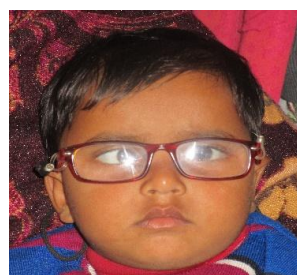Picture C



Picture D



Picture E



Picture F



Picture A, B, C shows a periodically alternate esotropia. We did a cycloplegic refraction and advice full correction. Picture

D, E, F shows photo of ocular alignment after wearing glass which is diagnosed as refractive accommodative esotropia.

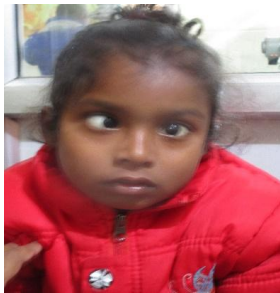

Image A

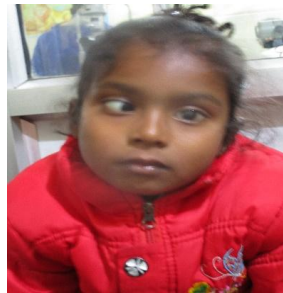

Image B

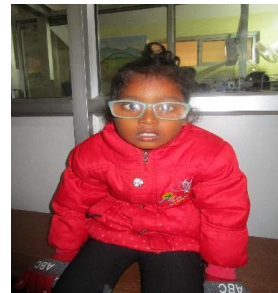

Image C



Image D



Image E

Second patient a five years old female with alternate convergent squint. We performed a cycloplegic refraction. Image A, B, C shows a periodically alternate esotropia. We did a cycloplegic refraction with +4.00 D sphere in both eyes. We advise full correction. Image D, E shows orthophoria after wearing glass.

## CONCLUSION

It is important to differentiate between the aetiologies of paralytic and non-paralytic esotropias so that proper management can be initiated. Accommodative esotropia has a favourable prognosis if treatment is introduced early. Management consists full correction of the hypermetropia which is diagnosed after cycloplegic refraction due to the main central factor of hyperopia was found in this condition. If it is not clear if the aetiology of the esotropia is non-accommodative, accommodative, or partial, the initial treatment should seek to correct any amount of hyperopia found before other treatment options are considered. It is important to

take into consideration the child's refractive error, binocular status, and accommodative function in diagnosing each individual patient so that treatment can be initiated as early as possible.

**Manuscript presented in other meetings or conference:** No

**Financial support:** Nil.

**Conflict of interest:** None.

## REFERENCES

1. Ehlers JP, Shah CP, eds. The Wills Eye Manual. 5<sup>th</sup> Ed. Baltimore: Lippincott Williams & Wilkins, 2008.
2. American Academy of Ophthalmology. Pediatric Ophthalmology and Strabismus: Basic and Clinical Science Course. San Francisco: AAO, 2011-2012.
3. Nelson LB, Olitsky SE, eds. Harley's Pediatric Ophthalmology. 5<sup>th</sup> Ed. Philadelphia: Lippincott Williams & Wilkins, 2005.
4. Mohney BG. Common Forms of Childhood Esotropia. Ophthalmology 2001; 108: 805–809.

5. Berk AT, Kocak N, Ellidokuz H. Treatment Outcomes in Refractive Accommodative Esotropia. Journal of AAPOS. 2004;8.
6. Kanski, JJ. Clinical Ophthalmology: A Systemic Approach. 6<sup>th</sup> Ed. Edinburgh: Butterworth Heinemann Elsevier, 2007
7. Hutcheson KA, Childhood esotropia. Curr Opin Ophthalmol 2004;15(5):444-448
8. "Refractive Accommodative Esotropia" in Chapter 7; Esodeviations. Basic and Clinical Science Course; Section 6. Paediatric Ophthalmology and Strabismus. San Francisco: American Academy of Ophthalmology, 2010-2011; 93-95
9. Mulvihill A, MacCann A, Flitcroft I, O'Keefe M. Outcome in refractive accommodative esotropia. Br J Ophthalmology 2000; 84(7): 74

How to cite this article: Kamble V, Bhadra Priya, Satbodh Shrestha et.al. Refractive accommodative esotropia: case report. Int J Health Sci Res. 2020; 10(12):117-121.

\*\*\*\*\*