

# Medical Management of Type II Scar Ectopic Pregnancy: A Case Report

Shameem Farzana<sup>1</sup>, Hina Shams Solangi<sup>2</sup>, Karmin Huma<sup>3</sup>

<sup>1</sup>MBBS, FRCOG (UK), Head of Department OBGYN Dr. Sulaiman Al Habib Hospital As Sweidi Exit 26, Hamza Bin Abdulmutalib Street, Po box 5612, Riyadh 12944, Kingdom of Saudi Arabia

<sup>2</sup>MBBS, FCPS (Pak), Consultant OBYN Dr. Sulaiman Al Habib Hospital As Sweidi Exit 26, Hamza Bin Abdulmutalib Street, Po box 5612, Riyadh 12944, Kingdom of Saudi Arabia

<sup>3</sup>MBBS, Locum Trainee Dr Sulaiman Al Habib Hospital As Sweidi/ Post graduate Trainee, Deccan Medical Collage Hyderabad, Telangana state. India

Corresponding Author: Hina Shams Solangi

## ABSTRACT

**Background:** Cesarean scar ectopic pregnancy is a rare form of ectopic pregnancy. Due to increased in cesarean section procedures its incidence is increasing. It is a diagnostic as well as therapeutic challenge for physicians as standardized guidelines are not yet been established.

**Case report:** A 32 years old African lady who had previous 2 cesarean sections, presented with irregular menstruation cycle, lower abdominal pain and vaginal bleeding. Patient was diagnosed as incomplete miscarriage but on follow-up ultrasound was suggestive of type II cesarean scar pregnancy. Our patient was successfully treated with single dose methotrexate.

**Conclusion:** It is important for physicians and sonologists to have a high index of suspicion while following patients with risk factors for scar ectopic pregnancy. Single dose methotrexate can be the first line of treatment for type II scar ectopic pregnancy.

**Key words:** Cesarean section, scar ectopic, diagnosis

## INTRODUCTION

Cesarean scar pregnancy is a rare form of ectopic pregnancy in which gestational sac implantation is seen partially or completely within the previous cesarean scar. The reported incidence of cesarean scar pregnancy is from 1/1800 to 1/2500.<sup>(1,2)</sup> The recent increase in cesarean scar pregnancy is due to increasing rate of cesarean sections and more awareness among the physicians about this particular condition. Evolving evidence about etiology is that it can be due to damage to endometrium and myometrium by previous cesarean section or any previous uterine surgery, the risk of cesarean scar pregnancy is independent of number of cesarean sections.<sup>(3)</sup> If early diagnosis and treatment is not done timely it can progress into an abnormally invasive placenta which can

result in uterine rupture and life threatening hemorrhage.<sup>(4-6)</sup> Therefore early recognition of problem and optimal treatment is the key factor in cesarean scar pregnancy.

Patients of cesarean scar pregnancy can present with pelvic pain and vaginal bleeding during first trimester. Although many women remain stable and asymptomatic until diagnosis, the diagnostic investigation is trans-vaginal ultrasound that can be combined with trans-abdominal scan. MRI can be used in few cases when the diagnosis is in doubt.<sup>(7,8)</sup>

The diagnosis of cesarean scar pregnancy is based on visualization of empty uterine cavity and cervical canal, detection of placenta or gestational sac embedded in uterine scar,<sup>(9)</sup> presence of thin myometrium less than 3 mm, or absent myometrial layer between the gestational

sac and bladder presence of prominent or at times rich vascular pattern at or in the area of cesarean scar with positive pregnancy test.<sup>(10)</sup>

Shin-yu lin et.al described a new ultrasound grading system for cesarean scar pregnancy Grade I: when the cesarean scar pregnancy is occupying less than half the thickness of myometrium. Grade II: when it is occupying more than half of the thickness of myometrium. Grade III: when the gestational sac bulges out of the overlying myometrium and uterine serosa. Grade IV: when the cesarean scar pregnancy becomes an amorphous tumour with rich vascularity around the cesarean scar.<sup>(10)</sup>

Many treatment options are available for management of cesarean scar ectopic pregnancy. It may be medical, surgical or uterine artery embolization or combination of the above.<sup>(11)</sup> All these management options are derived from various researches based on gestational age, viability of embryo, evidence of deficient myometrium and clinical presentation.<sup>(12-15)</sup> Medical management is effective, cheap and noninvasive in majority of the cases. Offer anti D prophylaxis to all Rh negative women who had surgical removal of ectopic pregnancy or when bleeding is repeated, heavy or associated with abdominal pain.

The aim of reporting this case is that initially the diagnosis was missed and when diagnosed on second visit we successfully managed this case with a single dose of methotrexate in-spite of initial high BHCG levels.

## CASE REPORT

32 years old African woman known case of diabetes mellitus on insulin, gravida three para two living one with history of two previous cesarean sections, presented to obstetrics and emergency department of Dr. Sulaiman Al Habib Hospital, Riyadh, Saudi Arabia with complains of lower abdominal pain and vaginal bleeding for one week. She was not sure of her last period and gave history of irregular cycles for the last 6 months. Her past medical and family history

was unremarkable, no known allergies. Clinically patient was stable with pulse rate 90 beats/minute blood pressure 112/78mm hg, her RBS was 84 mg/dl.

Her body weight was 61 kg and height 161 cm. Her initial BHCG was 23876.5 IU/L, Blood group type O positive. Ultrasound done showing thickened endometrium 15.8mm and mixed echogenicity within the uterus 6.2x 8mm as shown in figure-I.

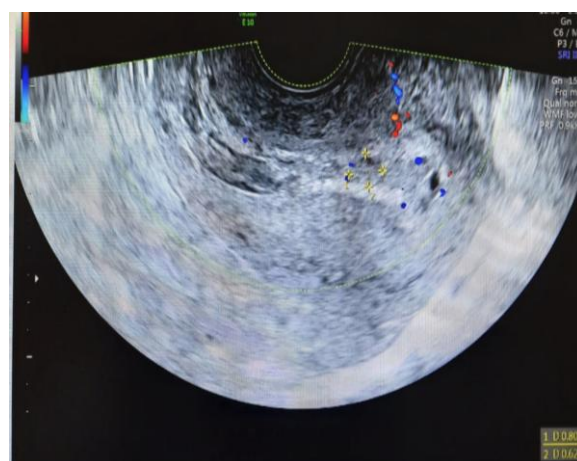


Figure-I Thickened endometrium with mixed echogenicity.

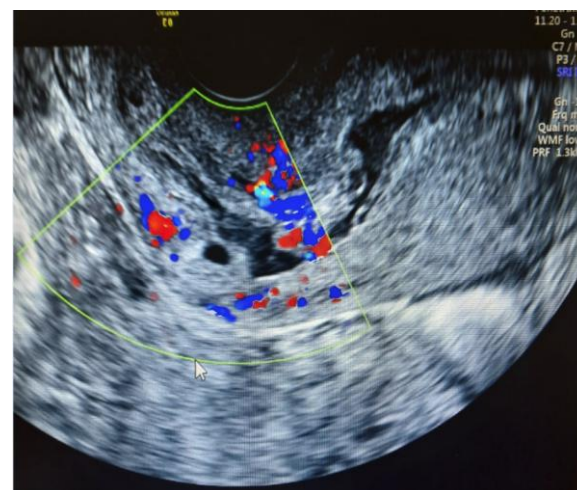


Figure-II Type II scar ectopic pregnancy.

Patient admitted as a case of incomplete miscarriage for observation and evaluation. Bleeding was minimal after admission. Patient counseled for expectant vs surgical management but patient opted for expectant management. Patient discharged home with follow-up and emergency care instructions. Patient was seen in the clinic after one week, patient



successfully with single dose methotrexate without any additional treatment. <sup>(18)</sup>

## CONCLUSION

Cesarean scar pregnancy poses a diagnostic challenge for physicians and sonologists, they need to maintain high index of suspicion during imaging and follow up. A missed diagnosis with delayed management may lead to uterine rupture, massive hemorrhage and even a maternal death. Trans-vaginal ultrasound by keen sonologists will pick up most cases of cesarean scar pregnancy. Single dose of systemic methotrexate treatment for cesarean scar pregnancy can be the first choice in managing Type II cesarean scar pregnancy.

## ACKNOWLEDGMENTS

We would like to acknowledge Dr Saima Najam's support and help for writing manuscript and proof reading. We also want to thank Dr Arulmozhi Munuswamy, who picked up the diagnosis and provided sonographic images of scar ectopic pregnancy with her expertise in field of ultrasonography.

## Conflicts of interest

Authors declared no conflicts of interest.

## REFERENCES

1. Rotas MA, Haberman S, Levгур M. Cesarean scar ectopic pregnancies: etiology, diagnosis, and management. *Obstet Gynecol.* 2006; 107(6):1373-81.
2. Grechukhina O, Deshmukh U, Fan L, et al. Cesarean scar pregnancy, incidence and recurrence: five- years experience at a single tertiary care referral center. *Obstet Gynecol.* 2018, 132(5):1285-95
3. Zhou X, Li H, Fu X. Identifying possible risk factors for cesarean scar pregnancy based on a retrospective study of 291 cases. *J Obstet Gynaecol Res.* 2020; 46(2):272-278
4. Pekar-Zlotin M, Melcer Y, Levinsohn-Tavor O, et al. Cesarean Scar Pregnancy and Morbidly Adherent Placenta: Different or Similar? *Isr Med Assoc J.* 2017; 19(3):168-71.
5. Zosmer N, Fuller J, Shaikh H, et al. Natural history of early first-trimester pregnancies implanted in Cesarean scars. *Ultrasound in obstetrics & gynecology: the official journal of the International Society of Ultrasound in Obstetrics and Gynecology.* 2015; 46(3): 367-75.
6. Michaels AY, Washburn EE, Pocius KD, et al. Outcome of cesarean scar pregnancies diagnosed sonographically in the first trimester. *J Ultrasound Med.* 2015; 34(4): 595-9.
7. McKenna DA, Poder L, Goldman M, Goldstein RB. Role of sonography in the recognition, assessment, and treatment of caesarean scar ectopic pregnancies. *J Ultrasound Med* 2008;27: 779-83.
8. Peng KW, Lei Z, Xiao TH, et al. First trimester caesarean scar ectopic pregnancy evaluation using MRI. *Clin Radiol* 2014; 69:123-9
9. Timor-Tritsch IE, Monteagudo A, Santos R, et al. The diagnosis, treatment, and follow-up of cesarean scar pregnancy. *Am J Obstet Gynecol* 2012;207:44.1-13.
10. Lin SY, Hsieh CJ, Tu YA, et al. New ultrasound grading system for cesarean scar pregnancy and its implications for management strategies: An observational cohort study. *PLoS One.* 2018. 9;13(8):2-4.
11. Najam S, Malik SE, Aqeel S, et al. Viable Caesarean scar pregnancy: A case report. *Biomedica.* 2020; 36 (1): 1-5.
12. Birch Petersen K, Hoffmann E, Ribbjerg Larsen C, et al. H. Cesarean scar pregnancy: a systematic review of treatment studies. *Fertil Steril.* 2016; 105(4):958-67.
13. Riaz RM, Williams TR, Craig BM, Myers DT. Cesarean scar ectopic pregnancy: imaging features, current treatment options, and clinical outcomes. *Abdom Imaging.* 2015; 40(7):2589-99.
14. Lian F, Wang Y, Chen W, et al. Uterine artery embolization combined with local methotrexate and systemic methotrexate for treatment of cesarean scar pregnancy with different ultrasonographic pattern. *Cardiovasc Intervent Radiol.* 2012; 35(2): 286-91.

15. Chiang YC, Tu YA, Yang JH, et al. Risk factors associated with failure of treatment for cesarean scar pregnancy. *Int J Gynaecol Obstet.* 2017 Jul;138(1):28-36.
  16. Sadeghi H, Rutherford T, Rackow BW, et al. Cesarean scar ectopic pregnancy: case series and review of the literature. *Am J Perinatol* 2010;27:111–20.
  17. Majangara R, Madziyire MG, Verenga C, et al. Cesarean section scar ectopic pregnancy - a management conundrum: a case report. *J Med Case Rep.* 2019; 13(1):137.
  18. Dearworth, Hannah and Cottrell, Jesse. Successful treatment of a cervical ectopic pregnancy with single-dose methotrexate therapy, *Marshall Journal of Medicine.* 2020;6(3);33-7.
- How to cite this article: Farzana S, Solangi HS, Huma K. Medical management of type II scar ectopic pregnancy: a case report. *Int J Health Sci Res.* 2020; 10(11):70-74.

\*\*\*\*\*