

## Bilateral Branchial Cleft Fistula - Case Report

Vishal Singh<sup>1</sup>, Rajkumar Verma<sup>2</sup>, Trilok Guleria<sup>3</sup>, Arun Kumar<sup>1</sup>

<sup>1</sup>MS ENT, Department of ENT, Civil Hospital Baijnath, Kangra, HP.

<sup>2</sup>MS Gen. Surgery- Department of Surgery, Civil Hospital Baijnath, Kangra, HP.

<sup>3</sup>ENT Department, Govt Medical College Hamirpur HP.

Corresponding Author: Rajkumar Verma

### ABSTRACT

**Introduction-** The structure of face and neck develop from branchial arches. Defect in development may lead to various branchial arch anomalies which may develop as cyst, sinus, and fistula in early or late childhood.

**Case report-** We are presenting two cases of different age group with bilateral fistula. First case was a male of 18 yrs with no craniofacial deformity. 2<sup>nd</sup> case was a female child 6yrs of age with microtia in right ear. Both operated with stepladder incision under GA.

**Conclusion-** Stepladder incision is an appropriate method for fistula excision. Recurrence was not seen but scar makes a cosmetic concern.

**Key words:** Branchial, Bilateral, Congenital, Embryological, Excision, Fistula.

### INTRODUCTION

The embryological structure of face, neck and pharynx develop from branchial arches. The branchial arches are a series of six mesodermal pouches that develop at the side of the primitive pharynx within 4-7 week of gestation. As branchial arches develop, the failed obliteration of branchial cleft often leads to the development of branchial arch anomalies. These are the 2<sup>nd</sup> most common congenital lesion of the neck. The 2<sup>nd</sup> arch is responsible for up to 95% of all branchial cleft anomalies. These anomalies present as cysts, sinuses or fistulae. Approximately 80% of cases present as branchial cysts and remaining 20% emerges as sinuses, fistulas, or cartilage remnants. A complete 2<sup>nd</sup> branchial arch fistula should have an internal opening at the tonsillar fossa and an external opening at the medial aspect of the sternomastoid muscle.

### CASE REPORT

We are presenting two cases of different age group with bilateral 2<sup>nd</sup> arch

fistula. First case is a male patient of 18 yrs with history of pus discharge from neck from two openings at the same level. The history was since the age of the 5 yrs. The condition of the pt. used to improve after taking antibiotic. On examination bilateral fistulous opening at the level of junction of upper 2/3<sup>rd</sup> and lower 1/3<sup>rd</sup> of sternomastoid muscles. On pressing the openings mucoid discharge can be elicited bilaterally. On following these cranially cord like structure could be elicited bilaterally. On oropharyngeal examination grade one tonsillar hypertrophy was present. There was no craniofacial deformity. Renal ultrasound was normal. The external ear was grossly normal. Pure tone audiometry was normal. Hence the possibility of brachio-oto-renal syndrome was ruled out. The CT fistulogram was performed which showed the internal opening at the level of tonsillar fossa bilaterally. Haematological investigations and blood biochemistry was unremarkable. Systemic examination was normal. The patient was operated after one week.

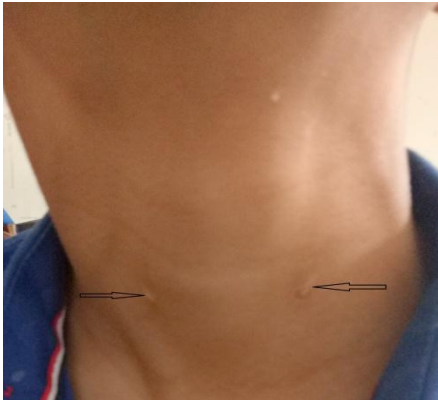

Fig.1 pre-op picture showing bilateral Fistulous opening

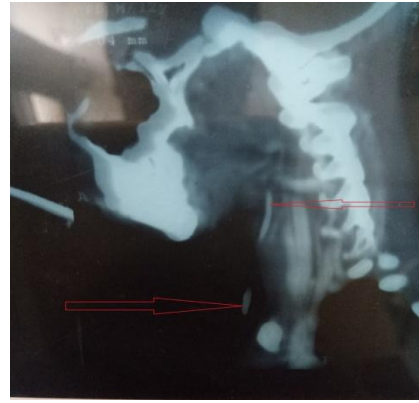

Fig.2 CT fistulogram showing fistulous track

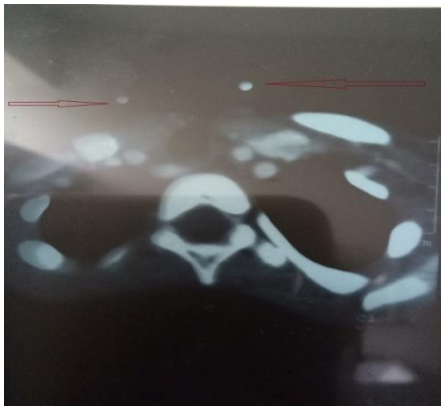


Fig.3 CT fistulogram showing bilateral fistulous track.

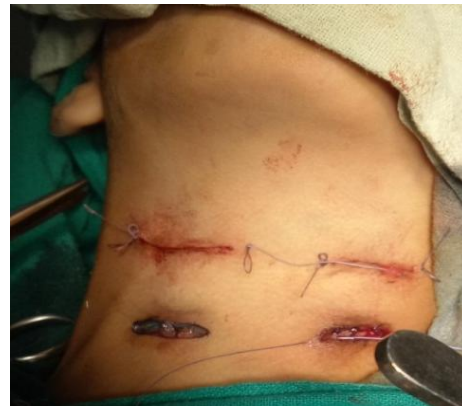

fig.4 per operative picture post excision of fitulous

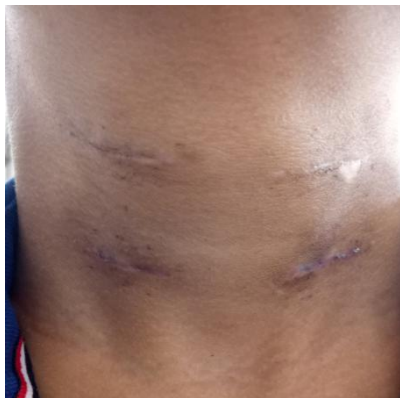

Fig.5 post op picture after two weeks

Second case is a female child of 6yrs with history of fistulous opening in neck

since birth. History of mucoid discharge from both the openings was present. On examination active discharge could be seen from both openings. Oropharyngeal examination was unremarkable. Pinna was showing grade two microtia in Rt. ear. Canal was patent. In lt. ear there was preauricular cartilaginous tag. pure tone audiometry was normal bilaterally. Ultrasound was showing no anomaly in bilateral kidneys. CT fistulogram was showing fistulous track with internal opening at the level of tonsils bilaterally. The patient was operated for bilateral fistula under GA.

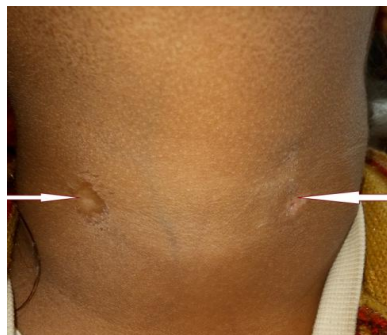

Fig.6 2<sup>nd</sup> case with bilateral fistula

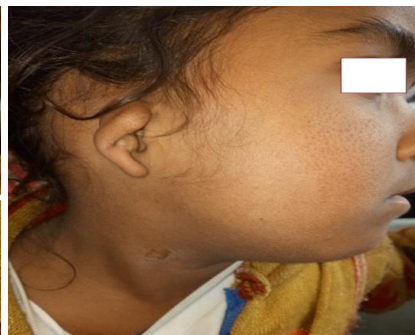

Fig.7 Rt ear microtia

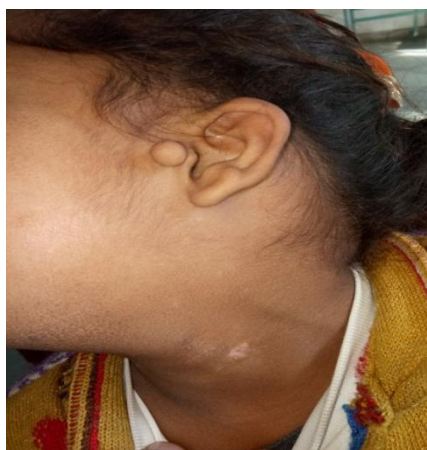

Fig.8 Lt. ear preauricular tag

## DISCUSSION

Branchial cleft anomalies occur as a result of an incomplete obliteration of the branchial apparatus during fetal development. The development of the branchial apparatus begins at about the second week of fetal development, and it is completed by the sixth to seventh week. The mesodermal arches are separated externally by ectoderm-lined grooves and internally by endoderm-lined pouches. The six arches are numbered in a cranio caudal direction. They give rise to the structures of the head and neck. As normal development proceeds, the branchial clefts and pouches are obliterated, except for the first cleft. Branchial anomalies in the form of epithelium-lined tubes connecting the skin to the foregut lumen may arise as a result of a persisting cervical sinus or a breakdown of the branchial plate or closing membrane between the clefts and pouches. (1,2) Anomalies of the first, second, and third branchial arches have been commonly described.

First branchial cleft anomalies have two variants. The type 1 variant occurs in the preauricular region and lies in a plane parallel to the external auditory canal and lateral to the facial nerve. The type 2 variant appears as an opening posterior or inferior to the angle of the mandible; the tract has an intimate association with the parotid gland and the VIIth cranial nerve.

Fistulas of the second branchial cleft are the most common branchial anomalies,

accounting for as many as 90% of all branchial cleft fistulas. (3,4) They are typically seen at a site along the anterior border of the sternocleidomastoid muscle. The tract crosses superiorly-lateral to the common carotid artery, the glossopharyngeal nerve, and the hypoglossal nerve-and it lies between the internal and external carotid arteries. The sinus often ends close to the middle constrictor muscle; in other cases, the sinus opens into the region of the tonsillar fossa.

Fistulas of the third branchial cleft, which are rare, also appear at the anterior border of the sternocleidomastoid muscle. They ascend lateral to the common carotid artery and they pass posterior to the internal carotid artery, superior to the XIIth cranial nerve and inferior to the glossopharyngeal nerve. The tract terminates by piercing the lateral thyrohyoid membrane at the piriform sinus.

Two conventional methods have been mentioned in the literature, namely the stepladder approach and single-incision approach. (5,6) In the present study, a bilateral stepladder approach was employed in the management of both cases for the purpose of better surgical access. This method was associated with good surgical outcome with no recurrence after 1 year of follow-up. The single-incision approach should be reserved for branchial sinuses or branchial fistulas with a short tract. The management of bilateral branchial fistulas follows the same principals of unilateral fistula or sinus tract excision wherein complete tract excision is mandatory to prevent recurrent symptoms.

## CONCLUSION

In conclusion two cases with different age group have been put under study with no family history of branchial fistula. First case 18 yrs of age, male sex, with no craniofacial deformity. In 2<sup>nd</sup> case female child of 6yrs of age with microtia in right ear. Both cases operated by stepladder incision under general anaesthesia. No recurrence reported in both cases. However,

post-op scar create cosmetic concern for the patient.

#### REFERENCES

1. Williams PL, Warwick R. Gray's Anatomy. 36th British ed. Philadelphia: W.B. Saunders; 1980:150.
2. Donegan. Congenital neck masses. In: Cummings CW, Fre-dricksen M, Harker LA, et al, eds. Otolaryngology- Head and Neck surgery. St. Louis: C.V. Mosby; 1986;1597-1608.
3. Olsen KD, MaragosNE, Weiland LH. First branchial cleft anomalies. Laryngo scope 1980; 90(3):423-36.
4. aka RC, Singh G. Complete congenital third branchial fistula on right side. Otolaryngol Head Neck Surg 2007;137(3):518-19.
5. Mandell DL. Head and neck anomalies related to the branchial apparatus. Otolaryngol Clin North Am. 2000;33(6): 1309-32.
6. Bajaj Y, Ifeacho S, Tweedie D, Jephson CG, Albert DM, Cochrane LA, et al. Branchial anomalies in children. Int J Pediatr Otorhinolaryngol. 2011;75:1020-3

How to cite this article: Singh V, Rajkumar, Guleria T et.al. Bilateral branchial cleft fistula - case report. Int J Health Sci Res. 2020; 10(10):316-319.

\*\*\*\*\*