

Osteofibrous Dysplasia: A Rare Case Involving Humerus

Gargi Gupta¹, Reeta Dhar², Shilpi Sahu³

¹Post-graduate Student, ²Professor, ³Professor and HOD,
Department of Pathology, MGM's Medical College and Hospital, Navi Mumbai.

Corresponding Author: Reeta Dhar

ABSTRACT

Osteofibrous dysplasia (OFD) is a benign fibro-osseous lesion in cortical bone of anterior mid-shaft of the tibia of infancy and childhood. The lesion is characterized by slow growth and proliferation of fibrous cellular tissue, bone, cement or in combination. A 49 years old male came to tertiary care centre with history of swelling on left arm since one month associated with pain and was gradually progressive. History of intramuscular injection and diabetes was present. Clinical diagnosis of deltoid granuloma on left lateral aspect of deltoid on upper arm was made.

Case History: A 49 years old male came to tertiary care centre, Navi Mumbai with history of gradually progressive swelling on left arm since one month associated with pain. Patient gave history of intramuscular injection in the past. History of Diabetes was also there. Clinical diagnosis of deltoid granuloma was made.

Conclusion: We reported an extremely rare case of Osteofibrous dysplasia arising in an adult in humerus and cortical excision from left lateral aspect of upper arm was given. It is important to recognize OFD clinically for further timely and appropriate treatment.

Keywords: Fibro-osseous lesion, deltoid, ossifying fibroma.

BACKGROUND

Osteofibrous dysplasia (OFD) is a benign fibro-osseous lesion also referred to as ossifying fibroma of the long bones. It comprises 0.2% of all primary bone tumors¹. It is most commonly detected during infancy and childhood, and the cortical bone of the anterior mid-shaft of the tibia is the most frequent site. The histopathology shows irregular fragments of woven bone rimmed by osteoblast and fibrous components that consist of bland spindle cells with collagen production.

WHO in 1972 classified it in two types as ossifying fibroma and cementifying fibromas; but in 1992 WHO considered it in one heading as cemento-ossifying fibroma. Further, the term "cemento-ossifying fibroma" was replaced by "ossifying fibroma" in 2005 under the new WHO classification.

Frangenheim first described the lesion in 1921 and reported it as a congenital osteitis fibrosa⁴. Subsequently, Kempson reported two cases affecting the tibia of young children and named the lesion ossifying fibroma⁵.

CASE HISTORY

A 49 years old male came to tertiary care centre, Navi Mumbai with history of gradually progressive swelling on left arm since one month associated with pain. Patient gave history of intramuscular injection in the past. History of Diabetes was also there. Clinical diagnosis of deltoid granuloma was made.

Grossly three grey white to grey brown, soft to firm tissue pieces largest measuring 3 x 2 x 1 cm and smallest measuring 1 x 1 x 0.5 cm was received.

Microscopically the sections studied revealed plenty of bony trabeculae of variable size and shape rimmed by proliferating osteoblasts amidst the fibrous stroma comprising of spindly cells and

blood vessels. At the periphery, numerous muscle bundles and fascicles are also seen. Large foci of chondroid metaplasia are also seen. No mitotic activity or necrosis identified.

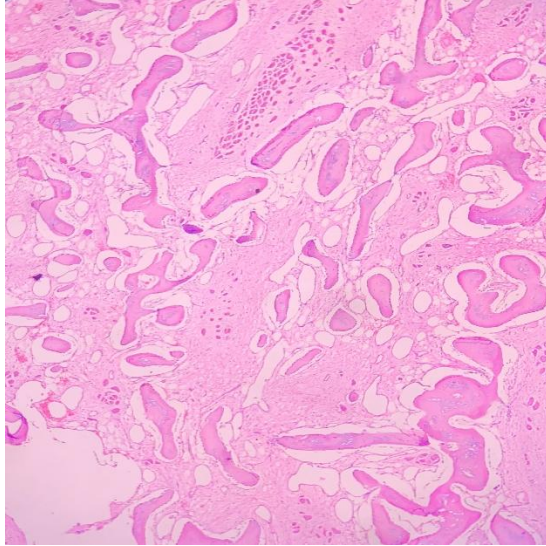


Figure 1

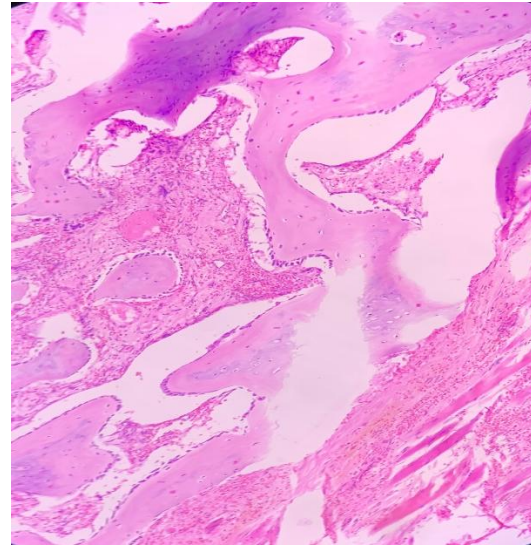


Figure 2

Figure 1&2 (10 X): Sections show bony trabeculae with muscle fibres. At places, calcification can also be seen.

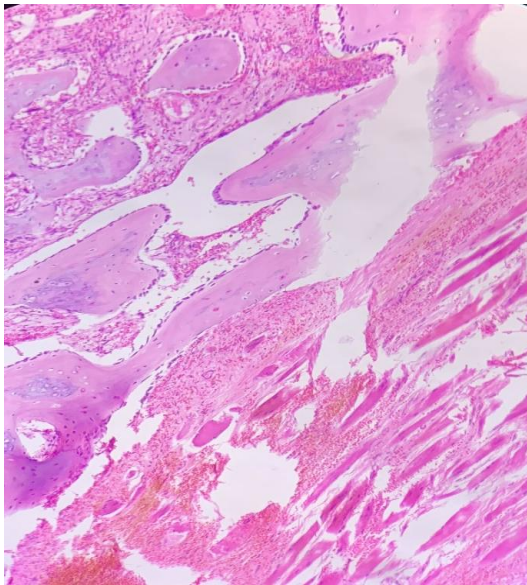


Figure 3

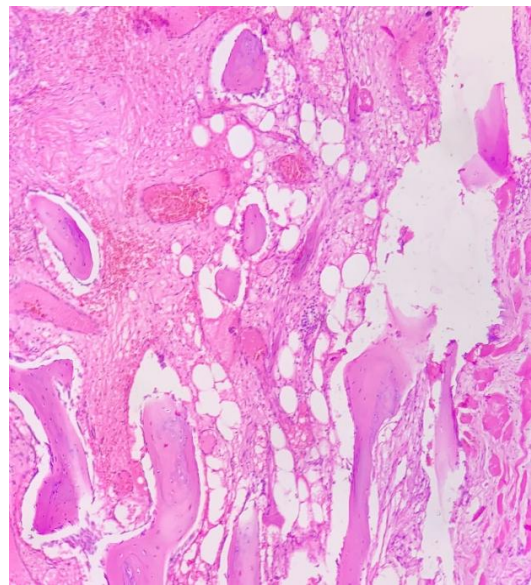


Figure 4

Figure 3 & 4 (40 X) : Sections show bony trabeculae amidst the fibrous stroma comprising of spindly cells and blood vessels.

DISCUSSION

OFD is a benign fibro-osseous lesion which most commonly occurs in the anterior cortex of the proximal or middle third of the tibia, and the ipsilateral fibula is involved in about 20% of cases¹. It occurs most commonly in tibia and fibula, and the involvement of other bones is very rare. The cortex often is expanded and thinned, with

multiple radiolucencies mixed with intervening areas of sclerosis. The second most common site of involvement is the fibula. OFD is most commonly detected during the first two decades of life. However, there are some cases of OFD occurring in adults.

It is frequently asymptomatic and bilateral involvement is rare. Osteofibrous

dysplasia of the mandible, which occurs exclusively in adults, commonly is referred to as ossifying fibroma. The histopathology of OFD includes fibro-osseous lesions, with irregular fragments of woven bone rimmed by well defined osteoblasts. The fibrous tissue also show whorled, storiform pattern.

This is a rare case of osteofibrous dysplasia in an adult with involvement of humerus having history of intramuscular injection in deltoid five months ago.

CONCLUSION

We reported an extremely rare case of OFD arising in an adult in humerus and cortical excision from left lateral aspect of upper arm was given. It is important to recognize OFD clinically for further timely and appropriate treatment.

Conflict Of Interest

The authors declared no potential conflicts of interest regarding research, publication of the article.

REFERENCES

1. Yoshida, S., Watanuki, M., Hayashi, K., Hosaka, M., Hagiwara, Y., Itoi, E., . Watanabe, M. (2018). Osteofibrous dysplasia arising in the humerus: A case report. *Rare Tumors*, 10, 203636131880885. doi:10.1177/2036361318808852
2. Fletcher CDM, Bridge JA, Hogendoorn PCW, et al. WHO classification of tumors of soft tissue and bone. 4th ed. Lyon: International Agency for Research on Cancer (IARC), 2013, pp. 343–355.
3. Abraham VT, Marimuthu C, Subbaraj R, et al. Osteofibrous dysplasia managed with extraperiosteal excision, autologous free fibular graft and bone graft substitute. *J Orthop Case Rep* 2015; 5(1): 41–44.
4. Frangenheim P. Angeborene Ostitis fibrosa als Ursache einer intrauterinen Unterschenkelfraktur. *Arch Klin Chir* 1921; 117: 22–29 (In German).
5. Kempson RL. Ossifying fibroma of the long bones. A light and electron microscopic study. *Arch Pathol* 1966; 82(3): 218–233.
6. Campanacci M. Osteofibrous dysplasia of long bones. A new clinical entity. *Ital J Orthop Traumatol* 1976; 2(2): 221–237.
7. Schlitter HE. Zwei benigne Knochentumoren mit seltener Lokalisation und Spontanfraktur. *Fortschr Geb Röntgenstr Nuklearmed* 1958; 88(2): 195–200.
8. Blauth W and Meves H. Behandlungsprobleme bei der “aggressiven” Form der fibrösen Dysplasie. *Z Orthop Ihre Grenzgeb* 1974; 112(2): 230–235.
9. Sissons HA, Kancherla PL and Lehman WB. Ossifying fibroma of bone. Report of two cases. *Bull Hosp Jt Dis Orthop Inst* 1983; 43(1): 1–14.
10. Wang J-W, Shih C-H and Chen W-J. Osteofibrous dysplasia (ossifying fibroma of long bones). A report of four cases and review of the literature. *Clin Orthop Relat Res* 1992; 278: 235–243.

How to cite this article: Gupta G, Dhar R, Sahu S. Osteofibrous dysplasia: a rare case involving humerus. *Int J Health Sci Res.* 2020; 10(10):102-104.
